Digitized by the Internet Archive
in 2026

https://archive.org/details/manualofdiseases0000char_e3t1

PLATE I

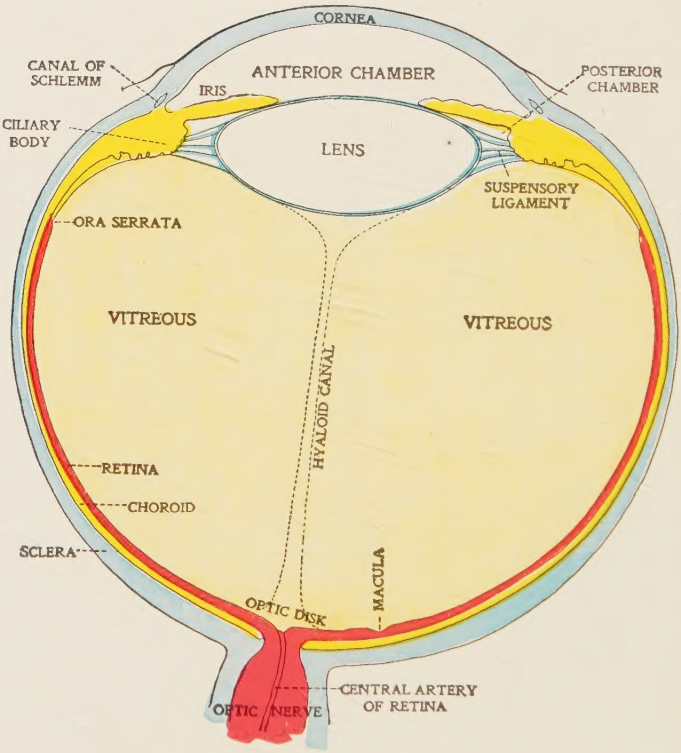

FIG. 1.—Horizontal Section of the Eyeball. Magnified about 3½ ×.

150TH THOUSAND

MANUAL

OF THE

DISEASES OF THE EYE

FOR STUDENTS
AND GENERAL PRACTITIONERS

BY

CHARLES H. MAY, M.D.

Director and Visiting Surgeon, Eye Service, Bellevue Hospital, New York; Consulting Ophthalmologist to the Mt. Sinai Hospital, to the French Hospital, to the Italian Hospital, New York, and to the Monmouth Memorial Hospital; Formerly Chief of Clinic and Instructor in Ophthalmology, College of Physicians and Surgeons, Medical Department, Columbia University, New York

Eleventh Edition, Revised

WITH 374 ORIGINAL ILLUSTRATIONS
INCLUDING 23 PLATES, WITH 73 COLORED FIGURES

NEW YORK
WILLIAM WOOD AND COMPANY
1924

COPYRIGHT, 1924, by
WILLIAM WOOD AND COMPANY

First Edition, August, 1900.
Second Edition, September, 1901. Reprinted October, 1901, and July, 1902.
Third Edition, August, 1903. Reprinted January, 1904, and October, 1904.
Fourth Edition, August, 1905. Reprinted October, 1906.
Fifth Edition, August, 1907. Reprinted August, 1908.
Sixth Edition, August, 1909. Reprinted August, 1910.
Seventh Edition, July, 1911. Reprinted July, 1913.
Eighth Edition, August, 1914. Reprinted August, 1916, and February, 1917.
Ninth Edition, August, 1917. Reprinted July, 1919, July, 1920 and July, 1921.
Tenth Edition, April, 1922. Reprinted August, 1923.
Eleventh Edition, August, 1924.

British Edition by Mr. Claud Worth; Baillière, Tindall & Cox, London, 1906.
Second British Edition, May, 1908. Reprinted January, 1909.
Third British Edition, October, 1911. Reprinted April, 1912.
Fourth British Edition, Nov., 1914. Reprinted Feb., 1917, Jan., 1918, Nov., 1918, Nov., 1919, Aug., 1920 and April, 1922.
Fifth British Edition, September, 1924.
Spanish Translation by Prof. C. E. Finlay; Salvat Editores, Barcelona, 1907.
Second Spanish Edition, October, 1909.
Third Spanish Edition, March, 1912.
Fourth Spanish Edition, July, 1914.
Fifth Spanish Edition, July, 1918.
Sixth Spanish Edition, May, 1921.
Seventh Spanish Edition, July, 1924.
French Translation by Dr. Bouin; Steinheil, Paris, 1907.
Second French Edition, May, 1911.
Third French Edition, January, 1914.
Fourth French Edition, Masson et Cie, 1923.
Italian Translation by Prof. E. Trombetta; Unione Tipografico, Turin, 1905.
Second Italian Edition, January, 1909.
Third Italian Edition, January, 1916.
Fourth Italian Edition, December, 1920.
Fifth Italian Edition, November, 1924.
Dutch Translation by Dr. G. J. Schoute; Meulenhoff, Amsterdam, 1907.
Second Dutch Edition, September, 1910.
Third Dutch Edition, June, 1916.
Fourth Dutch Edition, September, 1919.
German Translation by Dr. E. Oppenheimer; Hirschwald, Berlin, 1904.
Second German Edition, June, 1921.
Japanese Translation by Dr. T. Hidaka; Nankodo, Tokio, 1909.
Second Japanese Edition, August, 1914.
Chinese Translation by Dr. T. M. Li, Presbyterian Mission Press, May, 1923.

PUBLISHERS PRINTING COMPANY, NEW YORK

PREFACE TO THE ELEVENTH EDITION

The tenth edition of this manual appeared in April, 1922, and was reprinted in August, 1923; there have also been new editions of the British and of some of the foreign language editions; an eighth translation, the Chinese, appeared in 1923.

In presenting the eleventh edition, the author desires to express his appreciation of the continued favor with which his work is received; more than one hundred and fifty thousand copies have been published. Every page has been carefully examined; alterations and additions have been incorporated to improve the text wherever possible.

Chapter XI on Uveitis and Chapter XXV on Disturbances of Motility have been rewritten, the latter with the able assistance of Dr. J. H. Dunnington. Colored Plate IVa, representing a Very Light-Colored Background and the Fundus in the Negro, has been added; some of the halftone illustrations have been replaced by superior ones and a few have been added.

The volume has been kept up to date, but has not been increased in size, the original plan of presenting a book for the student and general practitioner having been adhered to.

CHARLES H. MAY, M.D.

698 Madison Avenue, New York,
August, 1924.

PREFACE TO THE FIRST EDITION

In the following pages the author has endeavored to present a concise, practical, and systematic Manual of the Diseases of the Eye, intended for the student and the general practitioner of medicine. The great difficulty in preparing a book of this sort is to say enough but not too much. With this idea in view, the author has made the volume sufficiently comprehensive, up to date, and yet of limited size.

DISEASES OF THE EYE

CHAPTER I

EXTERNAL EXAMINATION OF THE EYE BY MEANS OF INSPECTION AND PALPATION

Introduction.—Thorough examination of the eye requires the adoption of a certain routine. The history of the patient's complaint will lead the trained observer to concentrate his attention upon the affected part of the eye; but until proficiency is gained through experience it is not safe to depart from a systematic plan of examination.

The eye, being intimately associated with the rest of the body, must not be regarded as an isolated organ. Hence a knowledge of the condition of the system is often valuable in the diagnosis and successful treatment of ocular disease. The parts immediately surrounding the eye must also receive careful attention.

Systematic examination of the eye may be divided into

1. Objective.
2. Subjective or functional.

The *objective examination* may be subdivided into

(a) Examination of the appendages and the anterior portions of the eyeball by means of *inspection and palpation;* this part of the examination is usually conducted in *daylight.*

(b) Examination of the cornea and of the interior of the eyeball in the *dark room,* with *artificial light,* by means of *oblique illumination* and the *ophthalmoscope.*

Inspection.—Those parts of the eye which admit of examination by daylight are best illuminated by seating the patient so that he faces a window. Taking a general survey of the eyes, we notice certain prominent symptoms,

such as swelling, congestion, discharge, lacrymation, photophobia, etc.

Proceeding from the superficial to the deeper parts, we commence with the *lids*, noticing their thickness, color, and position; the condition of their margins, whether swollen, crusted, or ulcerated; the power of opening and closing; the size of the palpebral aperture; and the position and permeability of the lacrymal puncta. Passing to the region of the *tear-sac* we see whether this is swollen, and whether

FIG. 2.—Eversion of the Lower Lid.

FIG. 3.—First Step in Eversion of the Upper Lid.

pressure with the tip of the index finger causes escape of secretion. We examine the condition and direction of the *cilia*, and notice whether any are misdirected.

Next we inspect the inner or *conjunctival surface of the lids*, observing any change in color, smoothness, thickness, and secretion of this membrane, and looking for foreign bodies.

Exposure of the Conjunctiva of the Lower Lid is easy: Place the thumb near the margin of the lid, press downward, while the patient looks up (Fig. 2).

Eversion of the Upper Lid requires a little practice: Grasp the central lashes between the thumb and index finger of the right hand and draw the lid strongly downward and away

from the globe, directing the patient to look down (Fig. 3); place the left thumb (or a probe held horizontally) at the upper margin of the tarsus and press downward, at the same time quickly turning the lid. Having turned the lid, it can be kept everted by shifting the left thumb against the margin,

FIG. 4.—Keeping the Upper Lid Everted.

FIG 5.—Exposure of the Retrotarsal Fold of the Conjunctiva of the Upper Lid.

the other fingers of the left hand being applied above the patient's forehead (Fig. 4).

Another method of inverting the upper lid, which requires but one hand, is as follows: Place the tip of the index finger just above the margin of the upper lid and the thumb immediately below the border of the lower lid. Tell the patient to look down. Push the upper lid back so as to tilt its edge away from the eyeball. With the thumb slide the lower under the upper lid. The latter is now grasped between the index finger and thumb and is readily inverted by a sort of semirotatory movement. The whole act is continuous, easy, is done quickly and with little discomfort to the patient.

This exposes the tarsal portion of the conjunctiva. To

inspect the *retrotarsal fold* (and this is important in the examination for trachoma) it is necessary to continue as follows: Press the edge of the everted upper lid firmly against the supraorbital margin with the thumb of the left hand; then push the lower lid upward over the cornea with the right index finger, at the same time exerting gentle backward pressure upon the eyeball (Fig. 5). Another method of exposing the retrotarsal fold is to put the upper lid on the stretch by drawing it downward and forward, and pressing upon the skin above the tarsus with a flat, blunt instrument, such as a squint-hook, until the fornix comes into view.

Then we proceed to the *eyeball* and notice its situation in the orbit, whether this is normal or whether the globe is pushed forward (exophthalmos) or sunken (enophthalmos). Its position in reference to the visual lines should be roughly ascertained; we see whether the visual lines meet at the object looked at, by directing the patient to gaze at a finger held about a foot in front of the eyes; if they deviate, we investigate whether there is loss of motion in any direction (paralysis), or absence of muscle-balance, either latent (heterophoria) or manifest (strabismus), as explained in Chapter XXV.

We observe whether there is any œdema of the bulbar conjunctiva (chemosis), or *congestion* of the anterior part of the eyeball. If the latter is present, it should be examined carefully, for the nature of this injection points to the seat of inflammation as explained on page 93, and illustrated on Plate VII.

Fig. 6.—Placido's Disc.

The *cornea* is next inspected, and may reveal inflammation, ulceration, vascularization, opacities, or foreign bodies. As an aid, we may now use a strong convex lens with which to concentrate the light from the window, but this method (oblique illumination) gives better results in the dark room with artificial light, and is, therefore, described in Chapter III. The *corneal reflex* derived from the window bars

gives us information concerning the curvature and smoothness of this part of the eye. Placido's keratoscope (Fig. 6), a target-like disc consisting of alternate black and white circles, may be used. By causing the patient to look in different directions, every part of the surface of the cornea is explored; distortion of the corneal reflection of the circles or of the lines corresponding to the window panes indicates a change of curvature or roughness. A minute foreign body can often be detected in this manner (Fig. 7).

A *B*

FIG. 7.—Corneal Reflection of Placido's Disc. *A*, Normal; *B*, distortion caused by a foreign body on the cornea.

To bring an abrasion, infiltration, or ulcer of the cornea more clearly into view, we may instil a drop of 2 per cent. solution of *fluorescein* (p. 408), washing off the excess with water. Wherever the cornea is infiltrated or its epithelium is absent there will be a green stain.

We often find evidences of previous ulceration of the cornea in the form of *opacities*. When a corneal opacity is very faint and cloud-like, it is called a nebula; when denser, a macula; and when perfectly opaque and white, a leucoma (Figs. 147, 148, 149).

The *sensitiveness* of the cornea may be noted by touching it gently with a thread or piece of soft paper, taking care not to touch the lids or lashes.

When there is much irritation, spasm of the lids (*blepharospasm*) prevents a proper examination. In such cases, the instillation of a solution of cocaine or holocain will aid us in exposing the eyeball.

In infants or very young children, when blepharospasm, swelling, inflammation, or obstinacy prevents us from inspecting the cornea in the usual way, the child is laid upon its back across the nurse's lap, and its head is steadied between the knees of the examiner who sits facing the nurse (Fig. 8). Holding the child's hands, the nurse steadies the patient's

body with her arms, allowing the legs to remain free, so that when the child struggles it will expend its energy in motion of the feet while the head remains the fixed point. Under such circumstances the lids may usually be everted by pulling upon them at a little distance from the margin. To

FIG. 8.—Method of Examining the Eyes of Infants and Young Children.

inspect the eyeball, we part the lids by placing our thumbs at the edges, rolling in the latter somewhat and then separating, keeping close to the surface of the eyeball (Fig. 9). Having exposed the eyeball, we may replace the thumb of the right hand by the index finger of the left, thus leaving the right hand free for other uses. The eye will usually be found turned upward, hence the cornea will be hidden from view; but after a minute it will appear in the palpebral aperture. Care must be taken not to scrape the cornea and cause an abrasion, nor to exert any pressure upon the eyeball, on ac-

count of the danger of perforation in case the cornea has become weakened by ulceration.

It is sometimes necessary to use *retractors* (Fig. 10) in order to separate the lids under such circumstances, and with these the same caution is required against wounding the cornea or pressing upon the eyeball.



FIG. 9.—Method of Exposing the Eyeball

If the method of examining the eyes of infants just described should prove unsatisfactory, a general anæsthetic must be employed. When forcibly separating the lids we must remember that pent-up secretions are released suddenly and may squirt into the eyes of the examiner.

Then we examine the *anterior chamber* and notice its depth, whether normal, shallow, or increased, and whether the *aqueous humor* is clear; if the latter is altered, we observe whether the exudation consists of pus (hypopyon), blood (hyphæma), spongy exudation, or the like.

FIG. 10.—Lid Retractor.

The *iris* comes next. We observe its color, smoothness, and thickness, whether its markings are clearly defined or blurred ("muddy"), and whether it is steady or tremulous during movements of the eyeball. *Adhesions* to the cornea (anterior synechiæ) or to the capsule of the lens (posterior synechiæ) are looked for; these may require the instillation of a mydriatic for their detection.

Then we note the characteristics of the *pupil:* size, shape, and position, and compare its size with that of its fellow; also its reaction to light, and in accommodation and convergence as explained on page 175. Behind the pupil we see the central part of the anterior surface of the *lens* and

observe its transparency or any abnormality, such as cataract or deposits. To explore the lens fully, dilatation of the pupil and artificial illumination are required.

Palpation informs us of (1) presence or absence of *sensitiveness in the ciliary region;* (2) degree of *hardness of the eyeball*, and (3) existence of tumors and swellings in and about the orbit.

Fig. 11.—Testing the Tension of the Eyeball.

Ciliary Tenderness. — By pressing upon the sclera, just behind the cornea (Fig. 11), as described below, we may discover sensitiveness of the ciliary body; this is an important symptom of cyclitis.

Eyeball Tension.—To gauge tension, direct the patient to look down, and then gently palpate the sclera above the cornea with the two index fingers placed upon the upper lid (Fig. 11), just as in feeling for fluctuation in an abscess, but pressing more downward than backward. We estimate the degree of tension by comparison with the other eye, if normal, or with another healthy eye. Increase of tension is a prominent symptom of glaucoma; degenerated conditions of the eyeball cause diminished tension; alternations in tension are sometimes found in cyclitis.

Tension is expressed by the sign T. followed by n. when normal, by + or − when increased or diminished, with numerals indicating the degree of change, as follows:

T.n. = Tension normal.

T. + = Tension increased.	T. — = Tension diminished.
T. + 1 = Appreciable hardness.	T. — 1 = Appreciable softness.
T. + 2 = Decided hardness.	T. — 2 = Decided softness.
T. + 3 = Board-like hardness.	T. — 3 = Eyeball very soft.

This method serves to estimate and record tension roughly. For accurate measurement, an instrument known as the *tonometer* (Fig. 12) is employed, the model of Schiötz being in general use, although Gradle's modification is often substituted on account of greater ease in application. The tonometer records, in figures, the resistance offered to definite weights used to produce an impress upon the eye, by the movement of a needle upon a scale. The eye having been anæsthetized with repeated instillations of a 1-per-cent. solution of holocain, the patient either lying upon a couch or seated on a chair, the head is placed so that the cornea looks directly upwards; the lower end of the tonometer is then rested by its own weight upon the upturned cornea, different weights having been superimposed, depending upon the degree of suspected increase in tension; the needle of the instrument becomes deflected to a certain number which, upon comparison with an accompanying scale, will be found to indicate a definite number of millimeters of mercury. Normal tension varies from 15 to 25 mm. of mercury as registered by the tonometer.

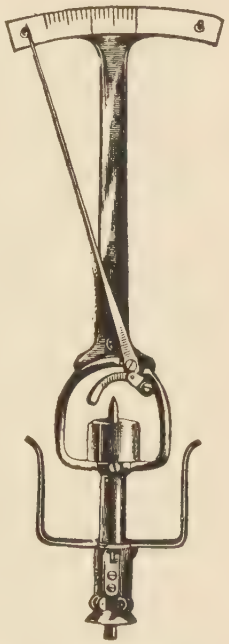

FIG. 12.—Tonometer of Schiötz.

Thus we conduct that part of the objective examination for which daylight furnishes suitable illumination. For minute inspection of the cornea, anterior chamber, iris, and lens, as well as for examination of the vitreous and fundus, we resort to oblique illumination and the use of the ophthalmoscope in the dark room (Chapter III.).

CHAPTER II

SUBJECTIVE OR FUNCTIONAL EXAMINATION OF THE EYE

The subjective examination, dependent upon the statements of the patient, comprises the testing of the function (vision or sight) of each eye separately. This function may be subdivided into (1) the form sense; (2) the color sense; and (3) the light sense.

The *form sense* is the faculty which the eye possesses of perceiving the shape or form of objects, and is expressed as *acuteness of vision*. The *color sense* is the power which the eye has of distinguishing light of different wave lengths, *i.e.*, distinguishing colors. The *light sense* is the faculty of perceiving different degrees of intensity of illumination (brightness). We distinguish between *a., central or direct*, and *b., peripheral or indirect vision.*

THE ACUTENESS OF VISION

Central or Direct Vision.—When we wish to obtain a distinct image, we look directly at an object so that the image falls upon the macula lutea, the portion of the retina which is adapted for the most acute vision; this constitutes *direct vision*. The acuteness is tested both for *distant* and for *near* vision.

Distant Vision.—In testing for distance a range of 20 feet (6 meters) is selected, since rays of light from this distance are practically parallel. For this purpose we make use of *Snellen's test types*, which are constructed upon the following principle: Each letter is inscribed within a square (Fig. 13) which subtends a visual angle of 5′ at the distance at which the normal eye should distinguish the letter. The visual angle is included between two lines drawn from the extrem-

ities of the object through the nodal point of the eye, which is situated 15 mm. in front of the retina and 7 mm. behind the cornea (Fig. 14). Each side of the square is subdivided into five equal parts; the smaller squares thus formed subtend a visual angle of 1′, which is the minimum visual angle for the normal eye—that is, if two black objects on a white ground are separated by a space subtending a smaller angle, they will no longer be seen separate, because the two images will fall upon the same cone in the layer of rods and cones of the retina. In order to subtend the same visual angle, the size of the letters must increase the farther they are removed from the eye (Fig. 14).

FIG. 13.—Construction of Snellen's Test Types.

Snellen's Test Types consist of square-shaped letters arranged upon a chart, the size of the letters diminishing from above downward. The height of each letter subtends a visual angle of 5′, the width of the component limbs a visual angle of 1′. The uppermost letter is of such a size that it

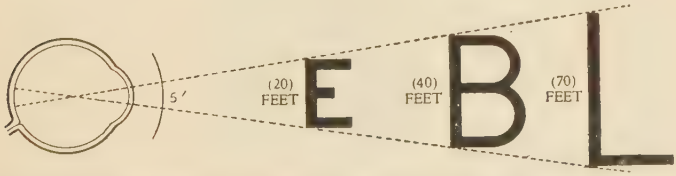

FIG. 14.—The Estimation of the Size of Snellen's Test Types at Various Distances.

can be read at 200 feet; then follow rows of letters which should be read at 100, 70, 50, 40, 30, 20, 15, and 10 feet respectively (Figs. 15 and 16).

The acuteness of vision is expressed by a fraction, the numerator of which corresponds to the number of feet separating the patient from the chart (preferably 20 feet), and the denominator to the number indicating the distance at which the smallest letters seen should be read by the normal

eye. If the patient's sight is normal, his acuteness of vision will equal $\frac{20}{20}$; this is expressed V. = $\frac{20}{20}$ (or $\frac{6}{6}$ if we use meters). If he can see only the third line from the top, V. = $\frac{20}{70}$. If he can not read more than the top letter, V. = $\frac{20}{200}$. If he reads some letters in the 50 line, but not all of this size, V. = $\frac{20}{50}-$ or $\frac{20}{70}+$. Many persons, especially during youth, can read the line which should be read at 15 feet, or even 10 feet, when

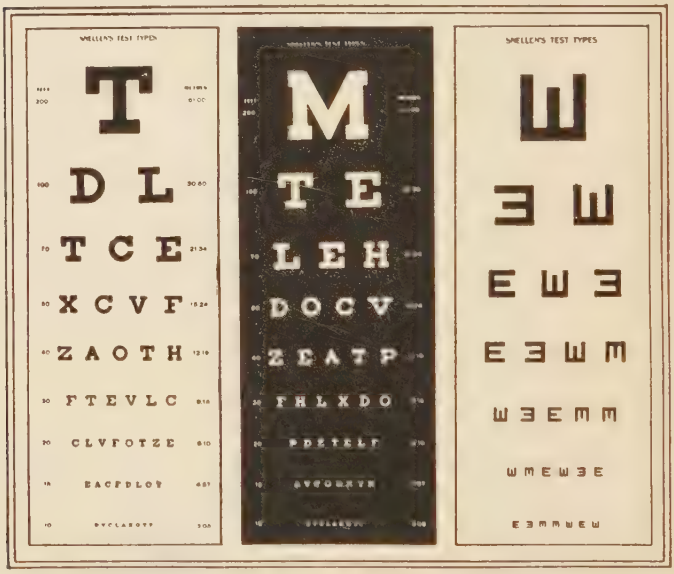
SNELLEN'S TEST TYPES
T
D L
T C E
X C V F
Z A O T H
F T E V L C
C L V F O T Z E
B A C F D L O Y
SNELLEN'S TEST TYPES
M
T E
L E H
D O C V
Z E A T P
F H L X D O
P D E T E L F
SNELLEN'S TEST TYPES

FIG. 15.—Snellen's Test Types. Usual Style of Chart.

FIG. 16.—Snellen's Test Types. White Letters on a Black Ground.

FIG. 17.—Test Types for Illiterates.

placed 20 feet from the chart; the fractions in these cases would be $\frac{20}{15}$ and $\frac{20}{10}$. Sometimes the acuteness of vision is expressed by 1 for $\frac{20}{20}$ and by smaller fractions for reduced sight, such as $\frac{1}{2}$ for $\frac{20}{40}$.

If the patient's vision is less than $\frac{20}{200}$, we reduce the distance from the chart. If he sees the largest letter at 8 feet, V. = $\frac{8}{200}$. If he cannot read the top letter at any distance,

we record the distance in feet or inches at which he can correctly *count the examiner's fingers* (extended) held against a dark background; for example, V. = Fingers at one foot or at 7 inches. If he has less sight than this, we move the hand before the eye, and if he is capable of appreciating such movements, we say he has "*perception of hand movements*" at so and so many inches or feet. If vision is still further reduced, we ascertain whether he has *perception of light* (P. L.) by alternately shading and exposing the eye by means of the hand, or by throwing light upon the eye with the ophthalmoscope or lens in the dark room, and noting whether he indicates the presence or absence of illumination.

Each eye is tested separately, one eye being covered with a card, or with the opaque disc supported in the trial frame. Daylight is the usual means of illuminating the chart, but artificial light thrown directly upon the test letters may be used. The test types are hung opposite a window, at about the level of the patient's eyes, and the patient is placed with his back to the source of illumination.

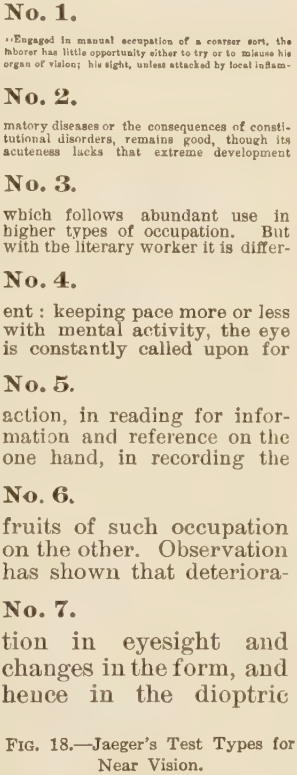
No. 1.
"Engaged in manual occupation of a coarser sort, the
laborer has little opportunity either to try or to misuse his
organ of vision; his sight, unless attacked by local inflam-
No. 2.
matory diseases or the consequences of consti-
tutional disorders, remains good, though its
acuteness lacks that extreme development
No. 3.
which follows abundant use in
higher types of occupation. But
with the literary worker it is differ-
No. 4.
ent: keeping pace more or less
with mental activity, the eye
is constantly called upon for
No. 5.
action, in reading for infor-
mation and reference on the
one hand, in recording the
No. 6.
fruits of such occupation
on the other. Observation
has shown that deteriora-
No. 7.
tion in eyesight and
changes in the form, and
hence in the dioptric

FIG. 18.—Jaeger's Test Types for Near Vision.

When the person is *illiterate*, we employ a series of letters E, with sizes corresponding to those of the Snellen types, in which the openings point downward, upward, and to the right and left (Fig. 17); the acuteness of vision is then fixed by the smallest row of

which the patient can correctly tell the direction in which the figures are open.

In the case of *children* who have not yet learnt the alphabet, we may employ a chart presenting the pictures of common objects conforming in size to the standard angle.

Near Vision.—When in a state of rest, the eye is adapted for parallel rays coming from a distant object. In order that divergent rays from a near object shall be focussed on the retina, there must be an increase in the refractive power of the eye: this change is known as *accommodation;* it will be more fully described in Chapter XXII.

The test types usually employed to determine near vision consist of different sizes of ordinary printer's types; the finest is numbered 1, successive numbers indicating coarser type. They are known as *Jaeger's test types* (Fig. 18).

The patient should be placed with his back to the light, so that the page is well illuminated, and each eye tested separately. His near vision is expressed by J., followed by the number corresponding to the finest print which he can read; thus, J. 3 means that the patient is able to read the third paragraph.

THE FIELD OF VISION

Peripheral Vision (Indirect Vision) is exercised when the image falls upon some part of the retina outside the fovea centralis; such vision is indistinct, but of great importance for our guidance and safety.

The Field of Vision represents the limits of peripheral or indirect vision; it is the space within which an object can be seen while the eye remains fixed upon some one point. It usually refers to one eye, the other being covered, and, when not otherwise stated, applies to a white object. The field can be outlined roughly by the hand, more accurately by a piece of chalk upon a blackboard, or a lighted candle, most exactly by means of a perimeter.

The Hand Test.—The patient is turned with his back to the light, and the examiner faces him at a distance of two feet.

After covering one eye, the patient is directed to fix that eye of the examiner, which is opposite; the examiner closes his other eye. The hand with extended fingers is then moved from various parts of the periphery inward, midway between examiner and patient, and the latter indicates when he sees the fingers. In this way the examiner can compare the patient's field with his own; if both be normal, patient and examiner must see the fingers simultaneously. This is a very simple and rapid method, and will reveal any large defect in the field. Instead of the hand, a 1 cm. white knob upon the end of a black rod may be used to measure the field in like manner.

The Blackboard Test gives us an approximately correct graphic representation. The patient is placed 12 inches in front of a blackboard, upon which we mark a cross to serve as the point of fixation. A piece of chalk is now gradually brought from the periphery toward the centre, and the patient indicates when he sees it in the several directions. These points are marked, and by connecting them an outline of the field is obtained.



Fig. 19.—The Perimeter.

The Candle Test — When the patient is no longer able to see the hand, we make use of a lighted candle or a small electric lamp, conducting the test in the dark room, covering the eye not under examination and, while moving the light about through the field of vision, requiring the patient not only to tell when the light is exposed or shaded but also where he sees it.

The Perimeter (Fig. 19) furnishes the most exact method. It consists of a metallic semicircle or quadrant, which can be revolved so as to take the direction of any meridian. This arc is marked in degrees, 0 corresponding to the middle point and 90 to either extremity. The patient's head is supported upon a chin-rest, one eye covered, and the other fixed upon a white spot located at the centre of the arc. The test object, a 10 mm. white square, is carried along the inner surface of the arc, either upon a black movable disc attached to the instrument or upon the end of a black rod. The points where the test object is first seen in the different principal meridians are marked upon diagrams of the normal field; the lines connecting these form the boundary of the field.

The Extent of the Normal Form Field with a 10 mm. white test object at the usual distance of $\frac{1}{3}$ m. is as follows: Outwards, 90° (or more); upwards, 55°; inwards, 60°; downwards, 70° (Fig. 20). The restriction in the field upward and inward is due to interference from the nose and brow, and because the percipient layers of the retina do not extend as far forward on the temporal as on the nasal side.

Pathological Alterations in the Field of Vision.—These consist of *limitation* and *defects*. Limitations may assume the form of contraction evenly in all directions (*concentric*), *irregular* contraction, or loss of part of the field on *one side* or the other.

Concentric contraction affects all parts of the periphery alike; when considerable, nothing but central vision may remain (Fig. 248); such contraction with preservation of good central vision is met with, for instance, in retinitis pigmentosa. The contraction may affect only or especially one side of the periphery; in such cases we speak of temporal or nasal contraction (Fig. 188), or upper or lower contraction. When one-half of the field is absent (Fig. 251), this constitutes *hemianopsia* (p. 289). *Sector-shaped* contractions sometimes exist; the defect then has the shape of a triangle the base of which is peripheral. Certain affections produce

characteristic contraction of the visual field; for instance, in atrophy of the optic nerve the contraction is concentric; in glaucoma, it is usually greatest on the nasal side.

A scotoma is a defect within the visual field. A physiological scotoma is *Mariotte's blind spot* situated about 15° to the outside of the point of fixation, corresponding to the entrance of the optic nerve (the black spot in Fig. 20). According to their situation, we divide scotomata into *central*, *paracentral*, *ring*, and *peripheral*. A *central scotoma* corresponds to the point of fixation (Fig. 245); when marked, it interferes with or abolishes central vision altogether; the scotoma accompanying hemorrhage at the macula furnishes an example. A *paracentral scotoma* is situated near the point of fixation and a *ring or annular scotoma* encircles this point. *Peripheral scotomata* cause little disturbance of sight and may exist without the patient's knowledge, especially when situated far from the point of fixation; disseminated choroiditis furnishes examples of scotomata of this sort (Fig. 171).



FIG. 20.—Normal Fields for White and for Colors (Blue, Red, and Green), with a 10 mm. test object.

Scotomata may be *positive*, when the patient sees them as black spots in his field, or *negative*, when they exist as defects in the visual field, but are not perceived by the patient until the visual field is examined. Positive scotomata are due to changes in the media or in the retina. If the opacities exist in the vitreous, the scotomata are *motile;* muscæ volitantes

represent one variety of defects of this sort. Negative scotomata may be *absolute*, when perception of light is entirely lost over the defective area, or *relative*, when there is only diminished perception of light, or loss of perception of certain colors over this area. Toxic amblyopia gives us an example of a scotoma which is central, relative, and often negative.

For the detection of scotomata, white and colored test objects having a diameter of 2 mm. should be moved in different meridians, and the spots where the object disappears or loses its color and then reappears or regains its color noted upon a chart. This test is best made upon a black screen (Bjerrum's curtain) at a distance of 1 to 2 meters so as to furnish a larger projection of the defect.

THE COLOR SENSE

The color sense as a whole (*i.e.*, the faculty of distinguishing different colors) is investigated by the methods described in Chapter XX. We distinguish between *central* and *peripheral perception of color*. The former is tested by the exhibition of samples of colored wool as described on page 282, the latter by small objects, such as squares of colored paper or small colored knobs 5 to 10 mm. in diameter, which are moved from the periphery toward the centre, on the perimeter, or in the coarser methods of testing the field.

The Field for Colors is smaller than that for white, but has the same general shape. It varies for different colors and its extent is influenced by the size, brightness, and saturation of the test object; that for blue is the largest, next comes red, while green has the smallest field. In rough dimensions the field for blue is 10° smaller than that for white; red 10° less than that for blue; and green contracted 10° as compared to red. The limits (given in Fig. 20) correspond to the points at which the *colors are recognized*, not to those points at which merely the presence of a moving object is perceived. The examination of the color fields is of considerable importance, since we frequently find that contraction of the field

for colors exists at an earlier period than that for white. It is a more delicate test, and detects diminution of visual power before it has become sufficiently pronounced to affect the field for white (form).

THE LIGHT SENSE

The light sense is the power of perceiving gradations in intensity of illumination (brightness); it is tested by means of an apparatus known as a *photometer*. We determine either the *lowest limit of illumination* with which an object is still visible (*light minimum* = L.M.), or the *smallest difference in illumination* which can be appreciated (*light difference* = L.D.). The estimation of the light sense is of some practical value in differential diagnosis of certain diseases of the fundus, though not generally made use of. Diminution in the light sense is not always proportionate to reduction in the acuteness of vision. Marked reduction of the light sense is seen in cases which are accompanied by night blindness—retinitis pigmentosa, for instance.

The examination of the *motility of the eye* is described in Chapter XXV.

CHAPTER III

OBJECTIVE EXAMINATION OF THE EYE CONDUCTED IN THE DARK ROOM: OBLIQUE ILLUMINATION AND THE OPHTHALMOSCOPE

The Examination in the Dark Room comprises the following steps, which are best taken in the order given:

1. *Oblique illumination,* for the physical examination of the anterior portions of the eyeball.

2. *Examination with the ophthalmoscope at a distance,* for exploring all the media of the eyeball.

3. *The indirect method of ophthalmoscopy,* for examining the fundus, giving an inverted picture of low magnification.

4. *The direct method of ophthalmoscopy,* for examining the fundus, giving an erect picture of greater magnification.

5. *Transillumination.*

The examining-room should be dark and all unnecessary light excluded. The source of illumination is either an Argand gas burner or an electric light with frosted globe, upon a "universal bracket," which permits the flame to be placed on either side of the patient, and to be raised or lowered at will. Patient and examiner may be either standing or seated.

OBLIQUE ILLUMINATION

Oblique (lateral or focal) illumination furnishes a very valuable means of minutely *exploring the cornea, anterior chamber, iris, and lens.* By means of a *strong convex lens* of two- or three-inch focus, light is concentrated upon the eye in such a manner that the apex of the cone of light corresponds to the part to be examined (Fig. 21). The source of illumination should be about eighteen inches to the side of the patient, several inches in advance, and on a level with the eye. The lens is grasped by its margin between the thumb

and index finger, held so that its surfaces are at right angles to the direction from which the light proceeds, and steadied by means of the little finger placed against the side of the patient's face. After having examined one eye, without removing the supporting finger, we turn the patient's head slightly toward the light and illuminate the other eye. The flame may be placed on either side; if on the patient's right,

FIG 21.—Oblique Illumination.

we use the left hand for holding the lens; if on the left, we use the right hand. After having examined the cornea the lens is brought nearer to the eye, so that the apex of the cone of light corresponds to the deeper structures which we wish to explore.

With a strong second convex lens held at its focal distance (two or three inches) in front of the patient's eye, we can magnify the illuminated area and thus obtain greater detail.

Opacities of the cornea, aqueous, or lens, seen by oblique illumination, appear as *grayish or white spots upon the black ground* of the pupil (Figs. 26, 28, 30, 32, Plate II).

THE OPHTHALMOSCOPE

The invention of the ophthalmoscope (Fig. 22) by Helmholtz in 1851 was not only an epoch in ophthalmology, but constituted an important event in general medicine. Its use enables us to explore the interior of the eye and thus diagnose lesions concerning which we had previously little knowledge

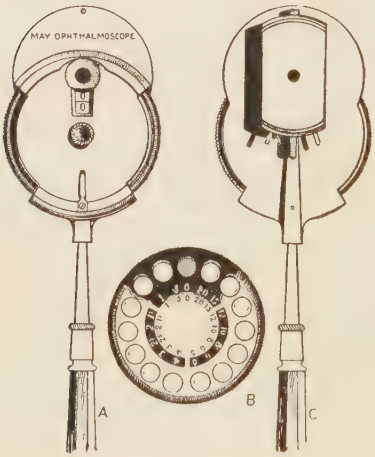

FIG. 22. –The Ordinary or Reflecting Ophthalmoscope, Author's Model. *A*, Rear side; *B*, Lens disc; *C*, Mirror side.

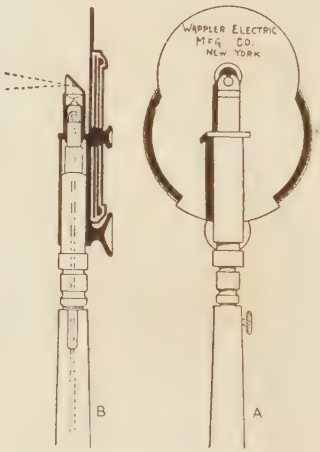

FIG. 23. The Electric Ophthalmoscope, Author's Model. *A*, Luminous side; *B*, Section.

during life. Of equal importance is the power of recognizing changes in the fundus which constitute valuable signs in the diagnosis of systemic disease.

The essential portion of this instrument is a *perforated mirror*. This is mounted upon a convenient handle and supplemented behind by a disc containing convex and concave lenses. The mirror serves to reflect light into the interior of the eye, while the aperture allows a portion of this light, after returning from the patient's eye, to pass into that of the observer. The mirror commonly employed is concave, of

about ten inches focus, either circular or of the form of a parallelogram, which allows it to be tilted to the right or left. The *lens disc* supports a series of lenses arranged successively from weaker to stronger. Any of these can be brought opposite the perforation in the mirror by means of the finger applied to the milled edge of the disc. Opposite each lens is a number indicating its strength in diopters.

The Electric Ophthalmoscope (Fig. 23) is self-luminous, a small electric lamp being placed within the handle, and its rays reflected into the patient's eye, by means of a reflector placed at a suitable angle. The lighting current is supplied either by a battery in the handle, a portable storage battery connected by cords, or the house current with interposition of a rheostat. Such instruments (introduced by Dennett) are widely employed, easier to use, and are supplanting the ordinary variety even for office examinations; they are indispensable at the bedside; their greatest advantage is with the direct method. *The May Electric Ophthalmoscope* has many advantages over other varieties, including improved illumination by a combination of converging lenses and a reflecting prism, so that there is neither reflex nor shadow and a satisfactory view of the fundus is obtained with the utmost ease; furthermore, the instrument is indestructible, the usual fragile mirror being replaced by a metal-encased solid reflector; it also serves as an efficient transilluminator.

THE OPHTHALMOSCOPIC EXAMINATION

Before attempting to see the fundus, we must explore the *media*. This preliminary step is important, since it will explain blurring in the picture obtained by subsequent methods, or failure to see the fundus when changes in the media exist. One mode of obtaining such information, oblique illumination, has already been described; it is particularly applicable to the anterior media. A second method is

Examination with the Ophthalmoscope at a Distance.—This method explores *all the media*—cornea, aqueous, lens, and

vitreous. The light is reflected from the mirror into the eye, and, returning from the background, traverses the media before reaching the eye of the examiner through the aperture in the mirror.

The source of illumination is placed on either side of the patient, on a level with the eye and several inches to the side and behind, so that the light strikes the patient's temple, leaving his face in darkness. The patient faces the examiner, the latter standing or sitting directly in front. The ophthalmoscope is held in front of either eye of the observer, so that he can look through the perforation, and is steadied against the side of the nose and supraorbital margin. The distance between patient and examiner is about *fifteen inches.*

From the mirror the light is reflected into the eye of the patient. Reaching the background, it is reflected and now has an *orange-red color* imparted by the choroid layer; this tinted light returns through the patient's eye and enters the eye of the examiner by means of the aperture in the mirror. The exact tint varies with the color of the background of the individual, depending upon the abundance of choroidal and retinal pigment; hence it is brighter in persons of light complexion, and darker in others. It is also influenced by the amount of illumination, and consequently the reflex is brighter when the pupil is dilated. The patient is told to move the eyes in various directions, and in this manner all parts of the media are explored.

In the normal eye a *homogeneous orange-red* reflex (*fundus reflex*) is obtained (Fig. 24, Plate II). If any details of the vessels of the fundus are seen, the eye is ametropic (Fig. 25, Plate II). If, when the observer moves his head from side to side, these vessels appear to move in the same direction, the eye is hyperopic; if in the opposite direction, it is myopic.

If *opacities* exist in any of the media, they will appear as *dark* or black *spots* upon the colored background of the pupil. They are dark because they intercept a certain part of the light (Figs. 27, 29, 31, 33, Plate II). Opacities of the media

PLATE II

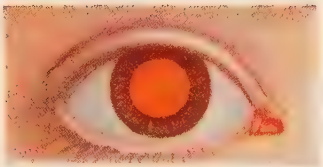

FIG. 24.—Normal Fundus Reflex; Ophthalmoscope at a Distance.



FIG. 25.—Fundus Reflex in Ametropia; Ophthalmoscope at a Distance.



FIG. 26.—Opacity of the Cornea; Oblique Illumination.



FIG. 27.—Opacity of the Cornea; Ophthalmoscope at a Distance.

FIG. 28.—Senile Cataract (Cortical) Oblique Illumination.

FIG. 29 —Senile Cataract (Cortical) Ophthalmoscope at a Distance



FIG. 30.—Senile Cataract (Nuclear); Oblique Illumination.



FIG. 31.—Senile Cataract (Nuclear); Ophthalmoscope at a Distance.

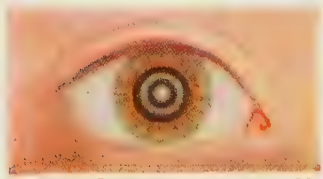

FIG. 32.—Lamellar Cataract: Oblique Illumination.

FIG. 33.—Lamellar Cataract: Ophthalmoscope at a Distance.

Figs. 24-33.—Examination of the Media with Oblique Illumination and the Ophthalmoscope at a distance.

may be either *fixed*, in which case they move only with the eye, or *movable* (floating), when they float about after the eye has been rapidly moved and then suddenly stopped: the latter occur only in an abnormally fluid vitreous.

The exact *situation of opacities* of the media can often be estimated by oblique illumination. Another method consists in noting the *displacement* of the opacity *with regard to the pupil*, when the observer's head is moved slowly from side to side. When there is no apparent motion of the opacity, it is in the plane of the iris; when it appears to move in the opposite direction, it is in front; and when in the same direction, it is behind this plane. A third method is based upon the *relationship of the motion* of the opacity to that of the *eyeball*. If, when the patient moves his eye, the opacity moves with (in the same direction as) the eye, it must be in front of the centre of rotation of the globe (which corresponds to the anterior portion of the vitreous, about 10 mm. in front of the retina); if it moves in the opposite direction, it must be behind this point; if it has no motion, it must be exactly at the centre. In both of these tests the greater the apparent motion the more removed is the opacity from the plane of the iris and the centre of rotation of the globe respectively.

Additional detail of changes in the media and iris may be obtained by placing *strong convex lenses* (from 5 to 20 D.) in the sight-hole of the ophthalmoscope, gradually approaching the eye as the strength of the lenses is increased, so as to bring the examined part into focus.

Having ascertained the condition of the media, we proceed to *examine the fundus*. The expert may succeed with a pupil of natural size; but it is often wise, and not infrequently necessary, to *dilate the pupil*. Moderate dilatation is secured by instilling one drop of a 4-per-cent. solution of *cocaine;* after 15 minutes the pupil will be of sufficient size, and the effects will pass off in half an hour, causing little discomfort. A 5-per-cent. solution of *euphthalmin* acts more energetically and the effects pass off within a few hours. Greater dilatation

follows the instillation of one drop of a 2-per-cent. solution of *homatropine*, or of a mixture of 2-per-cent. homatropine and 1-per-cent. cocaine; these cause mydriasis in from 20 to 30 minutes, and the effects last from 24 to 36 hours.

There are *two methods of examining the fundus:* (1) the *indirect*, (2) the *direct*.

The Indirect Method of Ophthalmoscopic Examination.—With the indirect method we obtain an *inverted image* of the fundus, *magnified about four diameters*. The source of illumi-

FIG. 34.—Indirect Method of Ophthalmoscopic Examination.

nation is in the same position as when we examine the media —behind, to the side, and on a level with the eye—and the examiner and patient retain the same relative positions. In the aperture of the ophthalmoscope we place a *3 or 4 D. convex lens*, which enables the examiner to obtain a clear image with his accommodation at rest. Placing the ophthalmoscope before either eye, at a distance of about 15 inches from the patient, we obtain the fundus reflex. A strong convex lens of 2 to 3 inches focus (called the *objective lens*) is now held at about its focal distance in front of the eye to be examined. This lens is grasped at its edges by the thumb and index finger of the left hand and steadied by placing one of the other fingers against the forehead of the patient (Fig.

34). If a clear view of some part of the background is not obtained, we vary the distance from the patient by slowly moving the head backward or forward, until there appears a distinct aerial, inverted image of the fundus at a short distance in front of the lens, corresponding to its focus.

After having seen the right fundus, we proceed to the examination of the left, without making any change in the position of the light, ophthalmoscope, patient, or examiner. We merely move the lens so as to cover the patient's left eye, now steadying it with the middle finger placed upon the forehead; the little and ring fingers are flexed into the palm of the hand, so that they will not obstruct the right or free eye of the patient and thus prevent him from gazing in any direction which we indicate. In the examination of the left eye we may, if we prefer, hold the ophthalmoscope in the left hand and the lens in the right.

We always begin the examination by looking for the *entrance of the optic nerve* (the disc or papilla), this being the most prominent feature of the background. The optic-nerve entrance is a little to the inner or nasal side of the visual axis; hence, in order to bring it into view, it is necessary to direct the patient to *move the eye in* somewhat, which will rotate the posterior pole of the eyeball outward. When we are directly in front of the patient, this is accomplished by causing him to look *over* our right *shoulder*, on a level with the upper border of the ear, when we examine the right eye, and over our left shoulder on a corresponding level, when we examine the left eye.

To see the *parts surrounding the disc*, we move the lens or the head slightly in various directions, always remembering that the image is inverted, and that it moves with the lens, but in the opposite direction to that taken by the head. More peripheral parts are brought into view when the patient moves his eye up, down, to the right, and to the left.

When the patient looks directly at the ophthalmoscope, it brings the *macula* into view; but since he must accommodate

when fixing so near an object, the pupil will contract. On this account it is well to dilate the pupil when we wish to get a view of the macular region with the indirect method.

The beginner may encounter a number of *difficulties* in using the indirect method. He may have trouble in bringing the disc into view, because the patient persists in watching the ophthalmoscope instead of looking across the examiner's shoulder. Owing to defects in the manufacture of the instrument, there are often very *confusing reflexes* from the margins of the sight-hole and perforation of the mirror. There is frequently a very *annoying reflection* of the flame from the cornea or from the surfaces of the lens which we hold before the patient's eye. These reflexes may be obviated by a slight inclination of the lens, a change in the angle of the mirror, or a little variation in the position of the examiner or source of illumination, which experience alone will teach us.

The Direct Method of Ophthalmoscopic Examination.—With the direct method we obtain an *erect* picture of the fundus *magnified about fourteen diameters.*

The examiner sits or stands to the side of and facing the patient (Fig. 35). The ophthalmoscope is supported as in previous methods, and brought directly in front of the patient's eye *as close as possible.* There should not be a greater distance than an inch between the eye of the patient and that of the observer. The light occupies about the same position as in previous methods.

When we examine the *right eye*, the examiner and the light must be on the *right side*, and consequently the ophthalmoscope must be placed before the right eye of the observer. When the left eye is being examined, the light and examiner must be to the left, and the observer must use his left eye. When the ophthalmoscope is provided with a tilting mirror, the surface of the latter must be turned toward the source of illumination.

When both examiner and patient are *emmetropic*, and both relax their accommodation, the observer looks through the

sight-hole and obtains a clear view of the fundus without any lens. The patient is told to look at the opposite wall, directly forward, over the shoulder of the examiner. This brings the *disc* into view. The parts around the disc are next examined. The periphery of the fundus is brought into view when the patient looks in various directions. The *macular region* is found to the outer side of the disc, the distance corresponding

FIG. 35.—Direct Method of Ophthalmoscopic Examination.

to about twice the diameter of the papilla. When the pupil has been artificially dilated so that it cannot contract in accommodation, the macula can also be brought into view by directing the patient to look into the aperture of the mirror.

The *size* of any particular lesion is *compared with* that of the *disc* (disc-diameters). Changes in the level of the fundus (elevations, depressions, new growths) are measured in diopters; an elevation of 1 mm. corresponds to 3 D.

The beginner is often annoyed by *reflexes* from the cornea and from the margins of the sight-hole and mirror perforation. The former can be obviated by a slight change in the angle of the mirror, the position of the examiner or that of the light; the latter are due to defects in the ophthalmoscope.

If the observer be ametropic, he must either wear his correcting distance glasses or have a special correcting lens fitted behind the aperture, or he may rotate his correcting lens before the aperture from one of those contained in the disc of the instrument. *When the patient is ametropic,* a suitable lens must be rotated into place behind the aperture; if he is myopic, this will be the weakest concave lens, and if hyperopic, the strongest convex lens, which will give a distinct picture. This gives an indication of the manner in which the direct method is employed for the estimation of errors of refraction.

The emmetropic observer will be unable to obtain a distinct view of the fundus of a myopic eye, by the direct method, without inserting a concave lens. He can examine a hyperopic eye either by putting up a convex lens or by using his accommodation. But in the direct method the observer must learn to *relax his accommodation.* The beginner often finds this difficult, since he cannot forget that he is looking at a very near object, and he accommodates accordingly. He is very apt to place a concave lens of about 4 D. in the sight-hole to neutralize the effects of such efforts, even though the patient has no myopia. Relaxation of accommodation is absolutely indispensable in using the direct method for the purpose of estimating errors of refraction. It is encouraged by *keeping both eyes open* and looking in the distance with the uncovered eye.

The Indirect and Direct Methods Contrasted.—The *indirect method* gives us a larger field, though a smaller magnification, and hence presents a *general view* of the background, which is *inverted.* It can be used successfully independent of errors of refraction in the patient's eye. On account of greater illumination we are often able to get details of the fundus, even when slight opacities of the media exist.

The *direct method,* on the other hand, gives us an *erect* picture, which is more highly magnified, though a smaller portion of the field is seen at a time; hence it permits of more *minute exploration* of particular parts to which our attention

has been directed by the indirect method. It is also the method of using the ophthalmoscope for the estimation of errors of refraction.

Theory of the Ophthalmoscope.—As ordinarily seen, the pupil appears black because the light which leaves it is nec-

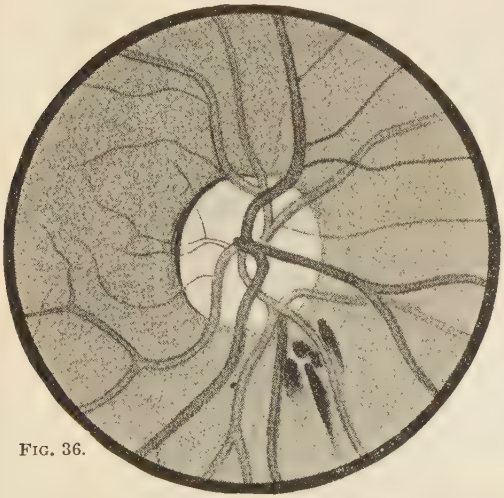

FIG. 36.

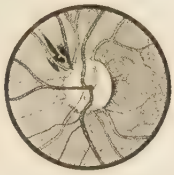

FIG. 37.

The Direct and Indirect Methods of Ophthalmoscopy Contrasted. The Picture of the Fundus Obtained by the Direct Method (Fig. 36) is Erect and Highly Magnified. That Obtained by the Indirect Method (Fig. 37) is Inverted and Less Magnified.

essarily reflected in the direction from which it came. If the eye of the observer be placed so as to intercept the returning rays, the interior of the observed eye will appear illuminated. With the ophthalmoscope light is reflected into an eye under examination, and the observer's eye is placed in the path of the returning rays and receives some of these through the perforation in the mirror.

Fig. 38 explains the illumination of the interior of the eye with the *ophthalmoscope at a distance.* E represents the eye of the examiner and P that of the patient. Divergent rays of light, proceeding from the Argand burner L, strike the ophthalmoscopic mirror O, are reflected

and made convergent, passing into the eye P, crossing in the vitreous, and illuminating the fundus between A and B. From any point of this illuminated area, C for instance, rays are reflected, pass out of the eye, being made parallel by its refracting apparatus, and proceeding,



FIG. 38.—Ophthalmoscopic Examination at a Distance.

pass through the aperture of the mirror O into the eye of the examiner E. The dioptric apparatus of E brings these rays to a focus on the retina, and they form at C′ an image of C.

Fig. 39 explains the *indirect method*. From L divergent rays proceed to the mirror O, are reflected and made convergent, passing into the examined eye P, crossing in the vitreous. They illuminate the



FIG. 39.—Indirect Method of Ophthalmoscopic Examination.

fundus between A and B. From any portion of this illuminated area, C D for instance, rays are reflected, and, passing out of the eye, are rendered parallel by its refracting apparatus. They fall upon the convex lens (L) and are brought to a focus a C′ D′, forming an enlarged, inverted image in the air at the focus of the lens (L), which image can be seen by the eye of the examiner E.

FIG. 41.—Normal Fundus. Average Tint.

FIG. 42.—Normal Fundus in a Person of Light Complexion

Fig. 40 illustrates the *direct method.* Divergent rays proceeding from L to the mirror O are reflected and made convergent, passing into the examined eye P, crossing in the vitreous. The fundus from A to B is lighted up. From any portion of this illuminated area, C D for instance, rays are reflected, pass out of the eye P, being made

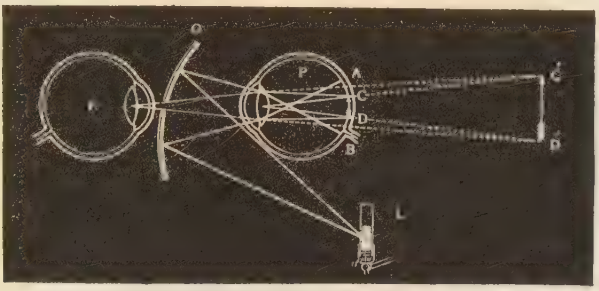

FIG. 40.—Direct Method of Ophthalmoscopic Examination.

parallel by its dioptric apparatus, through the perforation of the mirror O, into the eye of the examiner E. Here they are brought to a focus on the retina. They are convergent, and, being prolonged backward, form a magnified and erect image of C D, behind the eye of the patient P, at C′ D′.

The Normal Fundus.—The normal fundus exhibits a great many *variations* in details. It presents an *orange-red* surface, upon which we distinguish the *disc,* the *blood-vessels,* and the *macula* (*Plates* III, IV, IVa, V).

The Disc (*Papilla*) represents the *entrance of the optic nerve;* it is usually circular, but sometimes oval in form. Its color is light pinkish, more pronounced over the inner half, the outer portion being paler. The disc is much lighter in color than the rest of the fundus, and is separated from adjacent portions by a *sharply defined margin,* especially at the outer side. This margin often presents two *rings;* an inner, the *scleral* (*s,* Fig. 43), of white color, formed by exposure of the sclera when the opening in the choroid is larger than that in the sclera, and an external ring, the choroidal (*c,* Fig. 43), of dark color, formed by an accumulation of pigment at the

margin of the aperture through which the optic nerve passes. This pigmented ring may be complete or incomplete; in the latter case it is generally found at the outer border. The margins of the normal disc are occasionally slightly indistinct, especially above and below; this appearance is sometimes seen in hyperopic eyes of young subjects, and must not be mistaken for neuritis.

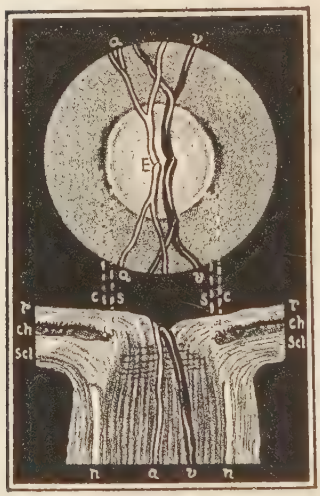

FIG. 43.—Opnthalmoscopic View and Longitudinal Section of the Disc. *a*, Central artery; *v*, central vein; *E*, physiological excavation; *s*, scleral ring; *c*, choroidal ring; *r*, retina; *ch*, choroid; *scl*, sclera.

The centre of the papilla presents a funnel-shaped depression (E, Fig. 43, Fig. 46, Plate V) formed by the separation of the nerve fibres; this appears whiter than the rest of the disc; it is known as the *physiological depression* or *cup*. It may be comparatively large and occupy one-half or more of the disc, but never the entire papilla, in which respect it differs from the pathological excavations of glaucoma and of optic-nerve atrophy (Figs. 185, 186, 187). At the bottom of this physiological excavation, when marked, we frequently see grayish spots; these represent the openings in the lamina cribrosa, the connective-tissue layer through which the fibres of the optic nerve pass (Fig. 46, Plate V).

The Central Artery and Vein of the optic nerve (*a* and *v*, Fig. 43) pass along the inner wall of the excavation, and upon reaching the surface of the disc usually divide into *superior and inferior divisions;* each of these soon divides and subdivides, giving off *nasal and temporal branches;* from these, smaller twigs are derived which become terminal and do not anastomose. Small branches are often given off from the

PLATE IV

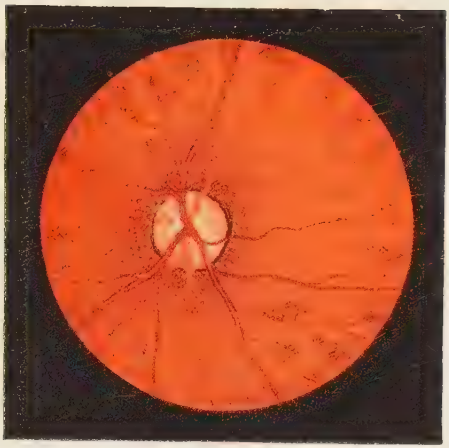

FIG. 44.—Normal Fundus in an Individual of Dark Complexion.

FIG. 45.—Opaque Nerve Fibres.

g.
th

PLATE IV-A

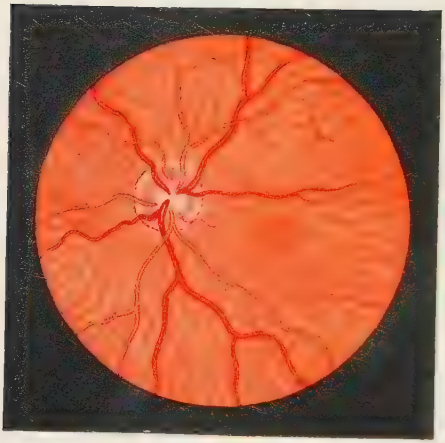

Normal Fundus in an Individual of Very Light Complexion.

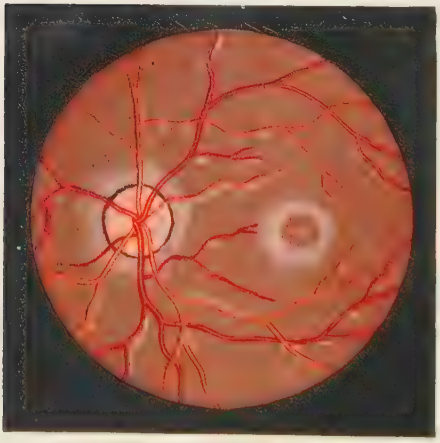

Normal Fundus in a Negro.

main trunks and pass across the disc. The macular region is devoid of larger vessels, though finer branches are seen to approach this area. The *arteries* are readily distinguished from the veins by their smaller calibre, bright red color, and straighter course; they present a bright reflex running along the centre. The *veins* are of greater thickness, of a darker red color, more tortuous, and the light-streak is fainter. Arteries and veins usually follow the same course. The veins sometimes present a distinct *pulsation*, most marked where the central trunk appears on the disc, and increased by pressure upon the eyeball; this is physiological. Pulsation in the retinal arteries, on the other hand, is pathological, and occurs in glaucoma and in cardiac disease.

The Retina itself is transparent. The *color of the background* is derived from the choroidal vessels, and modified by the pigment-epithelium layer of the retina and the pigment of the choroid. It is bright orange-red in persons of fair complexion, while in darker individuals it has a deeper, brick-red color. The fundus presents a granular or *stippled* appearance, caused by the pigment-cells. When the pigment-epithelium layer of the retina is well developed, the choroidal vessels cannot be seen. More often, considerable detail of the *vessels of the choroid* will be visible. This occurs under two conditions: In some cases there is no obscuration by the pigment layer of the retina, and the choroidal pigment is very abundant and collected into the intervascular spaces; then these stand out as dark islands separating bright-red lines and bands, which anastomose freely, the choroidal vessels (Fig. 44, Plate IV). In other instances, there is very little pigmentation in either retina or choroid, allowing the chorodial vessels to be seen plainly, now presenting the picture of bright-red anastomosing channels with brighter interspaces (Fig. 42, Plate III, Plate IVa). The chorodial vessels are most markedly visible in the periphery, and are readily distinguished from retinal vessels by being less sharply defined, flat, having no light-streak, by their free anastomosis, and by the

fact that they obviously lie in a plane posterior to the retina.

The Region of the Macula Lutea (Fig. 47, Plate V), physiologically the most important part of the fundus, is situated rather less than two disc-diameters to the temporal side of the entrance of the optic nerve, in the line of direct vision. Very often this region presents scarcely any distinctive feature. It is always *devoid of visible vessels*, and is somewhat *darker* than the rest of the fundus. Frequently a *bright spot* is seen in its centre corresponding to the position of the fovea centralis, or there may be two or three of these bright spots. Sometimes the macular region is represented by a bright spot surrounded by an area of dark-red color, about the size of the disc, oval horizontally, and this again encircled by a *bright halo;* this reflex is best seen in the indirect method and is most marked in children of dark complexion, especially if they be hyperopic; it is very pronounced in negroes (Plate IV, a).

Physiological Variations.—In children of dark complexion the fundus not infrequently presents a bright lustre, which changes its position with movements of the mirror, most marked along the blood-vessels; it resembles the shimmer of *watered silk*. Another peculiar but physiological appearance is sometimes occasioned by *opaque nerve fibres*. In such cases the axis cylinders of some of the optic-nerve fibres regain their medullary sheath at the disc, and continue in this condition for some distance beyond the papilla, presenting whitish areas extending for a variable distance from the disc and terminating in brush-like extremities (Fig. 45, Plate IV). The normal fundus presents *many minor variations;* hence experience is necessary to avoid regarding these as pathological.

TRANSILLUMINATION

This useful addition to the dark-room examination (also known as *Diaphanoscopy*) consists of the passage of a beam of *light* through the sclera, *from behind* or the side forward,

PLATE V

Fig. 46.—Physiological Excavation of the Disc (Direct Method of Ophthalmoscopy).

Fig. 47.—The Region of the Macula Lutea (Direct Method of Ophthalmoscopy).

causing a *reddish glow in the pupil;* anything which intercepts the light, such as a solid mass or dense opacity, will cause a more or less pronounced shadow; this method is used principally in the differential diagnosis between *simple retinal detachment* and that due to an *intraocular growth.*

FIG. 48.—The May Electric Ophthalmoscope arranged for Transillumination.

Various instruments, known as transilluminators, (Sachs and Würdemann models) are used; but these are unnecessary since the May Electric Ophthalmoscope serves as an excellent transilluminator: The upper part of this instrument (the disc supporting the series of lenses) is removed and the exposed electric bulb (Fig. 48) applied to the external surface of the eyelids and pressed firmly against the eyeball, causing the light to shine through lid and sclera from various directions. Good results are obtained only when the room is absolutely dark. No anæsthesia of the sclera is called for and there is no discomfort.

The May Electric Ophthalmoscope with exposed bulb, will be found useful in lighting up the anterior portion of the eyeball in place of the usual oblique illumination, the light being thrown directly upon the cornea, and also in muscle-testing (p. 363).

The Corneal Microscope and Slit-Lamp (Gullstrand's) furnish a useful combination for the study of minute changes in the anterior parts of the eye. The slit-lamp produces an extremely brilliant light which is condensed into a very sharp and minute image and thrown upon the part to be examined; the latter can then be examined with the naked eye, but better when magnified with the corneal microscope. With this intense, concentrated illumination and added magnification, we are enabled to study microscopic changes in the conjunctiva, cornea, iris, lens, circumlental space, ciliary body and even the anterior portion of the vitreous.

CHAPTER IV

AFFECTIONS OF THE EYELIDS

Anatomy and Physiology.—The eyelids (palpebræ) consist of movable folds formed, from before backward, of skin, loose connective tissue, muscular tissue, tarsus and fascia, and conjunctiva (Fig. 49). In addition, they present eyelashes, numerous glands, blood-vessels, lymphatics, and nerves.

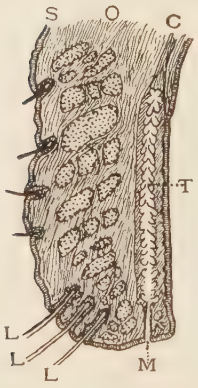

FIG. 49.—Longitudinal Section of the Upper Lid. *S*, Skin; *O*, orbicularis muscle; *C*, conjunctiva; *T*, tarsus; *M*, opening of Meibomian gland; *L*, lashes.

The *integument* is thin and delicate, and joined to the subjacent muscles by loose areolar tissue, free from fat. These characteristics explain the readiness with which extravasations of blood and œdematous swellings occur in this region.

The *margin* of each lid presents in front a rounded anterior lip from which the *eyelashes* (cilia) spring; these form two or three rows of short, thick, curved hairs, their roots deeply embedded in the connective tissue and muscle; they are provided with sebaceous follicles, known here as Zeiss's glands. In this situation are also found modified sweat-glands, known as the glands of Moll, which open into the hair-follicles of the cilia. Behind, the lid margin presents a sharp posterior lip; directly in front of this are the openings of the Meibomian glands. The surface between these two lips is known as the *intermarginal space*. The margins of the lids unite at an acute angle externally (*external canthus*). At the *internal canthus* the junction presents a rounded space which is occupied by a small, reddish elevation of modified skin, the *caruncle*.

In and behind the subcutaneous connective tissue we find the *muscles* of the eyelids. The *levator palpebræ superioris* is attached to the upper border and anterior surface of the tarsus and to the skin of the middle of the upper lid. The *orbicularis* muscle lies between tarsus and integument, being attached to the latter, but gliding loosely over the former; it forms a flat circle which surrounds the palpebral aperture; its function is to close the lids. We also find a layer of unstriped

muscular tissue inserted into the upper border of the tarsus and known as Mueller's muscle.

The *tarsus* consists of a thin plate of dense fibrous tissue, giving to each lid its firmness; it is larger in the upper than in the lower lid. The tarsi are connected with the lateral walls of the orbit by means of the internal and external *tarsal ligaments*, and to the upper and lower margins by an aponeurotic layer of fibrous tissue known as the *palpebral fascia* or ligament. In the substance of the tarsus, occurring in parallel rows, are found the *Meibomian glands*, thirty to forty in the upper and twenty to thirty in the lower lid. These are elongated sebaceous glands with blind extremities and numerous cæcal appendages, filled with fatty secretion, and opening on the free margin of the lid.

The palpebral *conjunctiva* is thin, vascular, and closely adherent to the tarsus.

The *arteries* are derived principally from the ophthalmic. The *veins* empty into the ophthalmic, temporal, and facial. The *lymphatics* pass to the pre-auricular, submaxillary, and parotid lymphatic glands. The *third nerve* supplies the levator, the *facial* the orbicularis, and the sympathetic the unstriped muscular tissue (Mueller's muscle). The sensory nerve supply is derived from the *fifth*.

The lids *protect the eyes* from external injury, foreign bodies, undue exposure, and excessive light. They serve to distribute the tears and the secretions from the various glands, thus lubricating the eyeball, keeping the surface of the cornea moist and transparent, and washing away any dust which may have found its way into the eye.

The Common Affections of the Eyelids are blepharitis, hordeolum, chalazion, trichiasis, entropion, ectropion, ptosis, tumors, and injuries.

BLEPHARITIS

Blepharitis Ciliaris is a very common, chronic inflammation of the margin of the lids, often associated with the formation of scales and crusts (Fig. 53, Plate VI). It occurs under two forms: (1) *non-ulcerative*, (2) *ulcerative*.

Symptoms.—In the *non-ulcerative form* (squamous blepharitis), the margins of the lids are *swollen and reddened*, and present numerous whitish *scales* at the bases of the lashes; the latter fall out readily, but are replaced, since there is no destruction of the hair-follicles. In this variety may be included cases of *simple hyperæmia* of the lid margin in which

there are no scales but the border of the lid is reddened and swollen; this condition is frequently seen in persons having a combination of fair complexion, delicate skin, and light-colored hair.

In the *ulcerative form*, the edges of the lids are reddened and swollen, and present yellowish *crusts* which glue the lashes together. On removing these crusts small *ulcers* are seen about the attachments of the lashes; these ulcers bleed readily. The *lashes* become distorted, fall out, and grow scarce, since they are not replaced on account of destruction of the hair-follicles.

In both forms there will be more or less *disfigurement*, the lids may be stuck together in the morning, and the patients complain of itching, soreness, epiphora, sensitiveness to light, and ocular fatigue during work, especially with artificial illumination.

Complications and Sequelæ occur especially in the ulcerative form. There may be conjunctivitis, styes, permanent *loss of a greater or lesser number of lashes*, hypertrophy of the lid margin, trichiasis, and ectropion.

Etiology.—*Poor hygienic surroundings;* debilitated conditions of the system; following *exanthemata*, especially measles; exposure to irritating atmosphere—smoke, wind, dust; late hours; insufficient sleep; uncorrected *errors of refraction*, especially hyperopia and astigmatism; chronic *conjunctivitis;* lacrymal disorders; nasal affections; lack of cleanliness. The disease occurs at all ages, but is very common in *children*.

Treatment.—The disease is apt to be obstinate. *Removal of the cause*, if possible, is of the greatest importance. Local cleanliness, change of faulty habits, and correction of errors of refraction are great aids to treatment. The edges of the lids must be *cleansed* thoroughly with soap and water, or water to which a little borax, bicarbonate of sodium, or hydrogen peroxide has been added (applied upon absorbent cotton), using enough friction to *remove all scales and crusts*,

dried, and then *massaged* with a 2-per-cent. *ointment of the yellow oxide of mercury*, ammoniated mercury, or ichthyol. In the ulcerative form an occasional application of 2-per-cent. solution of silver nitrate to the raw spots will prove useful. In severe and long-standing cases it will be necessary to pull out all diseased and suspicious-looking lashes, and then to apply the treatment given above.

Tarsitis is an infrequent form of chronic inflammation, usually syphilitic (tertiary, gummatous infiltration of the tarsus), though it may be tuberculous or trachomatous, in which the lid is much thickened and its skin tense and reddened.

Phthiriasis Palpebrarum is an uncommon affection, usually found in children, in which the lashes are covered with the black nits of the crab louse (pediculus pubis). There are redness and itching of the border of the lids. The parasites are quickly destroyed with blue ointment.

Syphilis of the Lids is occasionally seen as a primary sore, in the secondary stage, or in the form of gumma. *Chancre* having the same characteristics as when found elsewhere occurs upon the lid margin, usually near the inner canthus, accompanied by enlargement of the pre-auricular and submaxillary lymph glands; it might be mistaken for stye, suppurating chalazion, dacryocystitis, vaccinia, or rodent ulcer.

Vaccinia of the Lids is now and then met with as the result of the careless inoculation with the secretion from vaccine pustule elsewhere. It presents an ulcer covered with grayish exudate or crust, situated at the margin of the lid, usually the lower, sometimes upon both; it is accompanied by marked swelling and redness of the lids and by enlargement of the pre-auricular and submaxillary lymph glands.

Œdema of the Lids is a very common symptom, being favored by the structure of these parts. It may be (1) *inflammatory*, accompanying affections of the lids and adjacent parts, such as styes, dacryocystitis and affections of the nasal accessory sinuses, or existing as a symptom of violent inflammations of the interior of the eye, such as iridocyclitis, acute glaucoma, panophthalmitis, and orbital cellulitis; (2) *traumatic* when due to injuries, including the sting of insects; (3) *systemic*, in renal and cardiac disease; and (4) *non-*

inflammatory, of which a rather frequent type is *angioneurotic œdema*, a recurrent variety which comes on rapidly, is often marked enough to close the lids, is unaccompanied by any change in the eyes, causes much alarm to the patient, and disappears about as quickly as it came on; this form is most frequently seen in women, especially at the menstrual period; it is allied to urticaria and is most promptly relieved by a brisk saline cathartic and large doses of sodium bicarbonate.

Herpes Zoster Ophthalmicus is characterized by a unilateral, *herpetic eruption* following the distribution of the ophthalmic division of the *fifth nerve*. The affection begins with severe neuralgic *pain* of one side of the head and face, and constitutional disturbance. The eruption presents *vesicles* situated upon inflamed bases; the vesicles are at first filled with clear fluid, but this soon becomes cloudy; subsequently discolored crusts form and drop off, leaving permanent and disfiguring *scars*. In some cases, especially when the nasal branch is included, the eyeball becomes implicated; then the cornea presents one or more vesicles changing to ulcers, and the iris and ciliary body may become involved, leading to a very serious ocular condition.



FIG. 50.—Herpes Zoster Ophthalmicus.

The affection is due to disease of the Gasserian ganglion or the trunk of the trigeminus. It is most frequently observed in *elderly* patients of feeble constitution. Its *duration* is from three weeks to several months. The *prognosis* is usually good, but is serious when the cornea and deeper parts of the eye are involved.

Treatment.—At first cooling lotions; after vesicles have appeared, bland dusting powders (talcum, rice starch, zinc oxide) or 10-per-cent. ichthyol ointment; the galvanic current may be of service. Internally, quinine, iron, arsenic, and the salicylates are most useful. Severe pain may call for morphine.

HORDEOLUM OR STYE

A circumscribed, acute inflammation of the margin of the lid, originating from staphylococcus *infection of one of the sebacious follicles* of the lashes (Zeiss's glands), usually ending in suppuration. Styes are sometimes divided into (a) *external*, the common form here described, and (b) *internal*, a variety generally known as "suppurating chalazion" (p. 44).

Symptoms.—A red *swelling* (Fig. 51, Plate VI) appears at the *margin of the lid*, accompanied by pain, tenderness, and often by considerable œdema. Very soon a *yellowish point* will be seen, indicating suppuration.

Etiology.—Styes occur at all ages. They are very common in young adults. They often appear in *crops*. They are frequently associated with a deranged condition of the system, constipation, and uncorrected errors of refraction.

Treatment.—It is sometimes possible to abort a stye by the use of cold compresses. As a rule, however, this is unsuccessful. *Hot compresses* are then indicated to hasten suppuration. As soon as a yellow spot is seen, the pus should be *evacuated* either by pulling out a lash or by a horizontal incision, and then squeezed out. To prevent the formation of others, the *general health* should be looked after, constipation relieved, and *errors of refraction* corrected. When persistently recurring, calcium sulphide, hypophosphites, and general tonics are indicated; in very obstinate cases, the use of autogenous vaccine is of value. The tendency to recur is often checked by treatment of the blepharitis which is frequently present.

CHALAZION

Chalazion (tarsal tumor, *tarsal cyst*, Meibomian cyst) is a *chronic inflammatory enlargement* of one of the *Meibomian glands* in consequence of stoppage of its duct, accompanied by involvement of the surrounding tissues. It occurs most frequently in adults. Very often several are found at the same time, and there is some tendency to recurrence in crops. The contents consist of small, round cells with some giant cells (non-tuberculous); the centre undergoes mucoid degeneration; there is a fibrous envelope, but no true cyst wall.

Symptoms.—The process develops slowly with insignificant or no symptoms until, after weeks or months, it has reached the size of a small or large pea. Then it presents a noticeable *swelling* (Fig. 52, Plate VI), which feels hard, and is adherent to the tarsus, but not to the skin. On everting the lid its situation is shown by a red or purple (later gray) *discoloration* of the conjunctiva and sometimes by a small mass of granulation tissue. Sometimes chalazia disappear spontaneously. Occasionally they *suppurate* (internal stye, suppurating chalazion), this change being accompanied by *acute* inflammatory symptoms. Chalazia may be annoying merely on account of the *disfigurement*, or on account of the conjunctival *irritation* which they occasion.

Treatment.—When small, they need not be interfered with; occasionally we can cause their disappearance by the frequent application of ointments of the yellow oxide of mercury or ammoniated mercury, associated with *massage* and *hot compresses*. When larger, we remove them by *operation*, usually through the *conjunctiva:* The eye is anæsthetized with holocain or cocaine, the lid everted, the affected spot rendered prominent, and a *vertical incision* made through conjunctiva and wall of the chalazion with a Beer's knife (Fig. 58); the contents (Meibomian secretion, granulation tissue, and mucilaginous fluid) are removed and the walls thoroughly *scraped* with the chalazion curette (Fig. 59). If two

FIG. 51.—Hordeolum.

FIG. 52.—Chalazion.

FIG. 53.—Blepharitis.

FIG. 54.—Ectropion.

FIG. 55.—Chronic Dacryocystitis with Distention of the Lacrymal Sac.

FIG. 56.—Acute Dacryocystitis.

Figs. 51-56.—Diseases of the Lids and Lacrymal Sac.

or three drops of a 2-per-cent. solution of novocain in 1:3000 adrenalin are injected into or around the cyst, the operation will be painless and bloodless.

When the chalazion is more accessible externally, it may be advisable to operate through the *skin* by means of a *horizontal incision;* excision is better than mere incision with curetting; two or three sutures are employed. In such cases, the lid clamp (Fig. 60) or the chalazion forceps (Fig. 61) is applied with

FIG. 57.—Small Scalpel.

FIG. 58.—Beer's Knife.

FIG. 59.—Chalazion Curette.

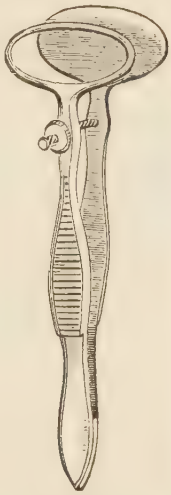

FIG. 60.—Desmarre's Lid Clamp.

FIG. 61.—Chalazion Forceps.

the ring blade surrounding the tumor on the cutaneous surface and tightened so as to furnish a bloodless field. Here also it is well to inject two drops of a 2-per-cent. solution of novocain in 1:3000 adrenalin previous to the incision.

Following the operation the cavity will be filled with a blood clot; this causes a continuation of the disfigurement for several days; absorption may be hastened by gentle massage for a few minutes several times a day.

Since chalazia occur rather more frequently in ametropic individuals than in others, correction of errors of refraction will tend to prevent recurrences.

TRICHIASIS

Trichiasis is an *inversion* of a varying number of *lashes*, so that they rub against the cornea (Figs. 63 and 68).

Distichiasis is an infrequent condition, usually congenital, in which the lashes can be separated into two rows, the pos-

Fig. 62. Fig. 63. Fig. 64. Fig. 65. Fig. 66.

Figs. 62–66.—Diagrammatic Section of the Upper Lid, showing Normal and Abnormal Position of Tarsus and Lashes. Fig. 62, Normal lid; Fig. 63, trichiasis; Fig. 64, distichiasis; Fig. 65, entropion; Fig. 66, ectropion.

terior of which is directed backward so as to rub against the eyeball (Fig. 64).

In both of these conditions the margins of the lids have a normal position, the displacement affecting the lashes only.

Symptoms.—The misdirected lashes cause *mechanical irritation* and *injury to the cornea*, with congestion, pain, lacrymation, photophobia, opacities, vascularization, and ulceration.

Etiology.—The most frequent cause is *cicatricial contraction* of the conjunctiva and tarsus in old cases of *trachoma*. Other causes are blepharitis, burns, injuries to the lids, and operations upon the lids.



Fig. 67.—Cilia Forceps.

Treatment. — 1. *Epilation.*—When the misdirected lashes are few in number, we may epilate with the cilia forceps (Fig. 67), repeating this every few weeks, since the lashes grow again. The misdirected lashes are

sometimes normal but often very fine, short, and of a pale color, and therefore not easily detected.

2. *Electrolysis.*—A sponge electrode corresponding to the positive pole is applied to the temple, and a fine platinum needle forming the negative pole is introduced into the hair-follicle, destroying the latter; a very weak galvanic current (2 milliampères) is employed. This method results in a permanent cure, but is quite painful; novocaine should be injected into the lid margin.

3. *Operation.*—When a great number or all of the lashes are misdirected, operations must be performed. These have for their object *correction of the faulty position* or *transplantation of the lashes.* Since trichiasis is frequently associated with entropion, these operations will be considered in connection with the latter disease.

ENTROPION

A rolling in of the margin of the lid (and with it the lashes) (Figs. 65 and 68).

Varieties.—There are two forms: (1) *Cicatricial,* due to cicatricial changes in the conjunctiva and tarsus, most commonly affecting the *upper lid.* (2) *Spasmodic,* due to spasm of the palpebral portion of the orbicularis muscle, almost always occurring in the *lower lid.* The second variety is generally found in old persons (*senile entropion*) who are predisposed through relaxation of the palpebral skin and the deep position of the eyeball resulting from the absence of fat.



FIG. 68.—Entropion of the Lower Lid. Trichiasis of the Upper Lid.

Symptoms.—Those due to *mechanical irritation* and *injury*

to the cornea: congestion, pain, lacrymation, photophobia, opacities, vascularization and ulceration of the cornea.

Etiology.—*Cicatricial form:* principal cause, the cicatricial changes in old cases of *trachoma*, also burns and other injuries to the lids, and operations upon the lids. *Spasmodic form:* atrophy or absence of eyeball, blepharospasm, inflammatory conditions of the lids and conjunctiva, and the prolonged wearing of a bandage (in senile patients).

Treatment.—*Non-operative* treatment may be of service in the *spasmodic variety*. If a bandage causes the entropion, we must either leave this off or apply a small roll of lint to the orbital margin beneath the bandage, exerting pressure in such a manner as to neutralize the inversion. In other cases we try to *remove the cause*. The lid may be kept everted for a few days by *collodion* painted on the external surface, or by *adhesive plaster* passing from the margin of the lid to the cheek. If these simple means do not answer, an *operation* is indicated. In the cicatricial form, operation is always necessary.

Operations for Trichiasis and Entropion.— The choice of an operation (there are a great many) is influenced



FIG. 69.—Horn or Metal Plate.

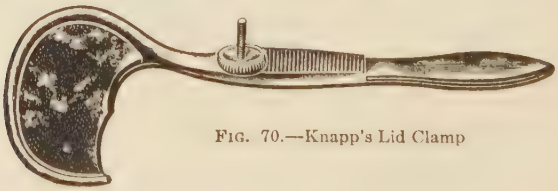

FIG. 70.—Knapp's Lid Clamp

by the peculiarities existing in the individual case. The object of these operations is to remove the displaced lashes from con-

tact with the eyeball either (1) by *changing the direction* of the lashes from a faulty to a correct one, (2) by *transplanting* the offending zone, or (3) by *straightening* the curved tarsus.

In these operations we use either a horn or metal plate (Fig. 69), or the lid clamp (Fig. 70), to protect the eyeball, check hemorrhage, and give proper support to the lid. The horn or metal plate is passed beneath the lid and pressed forward. If the lid clamp be used, its solid blade is passed beneath the lid, and the latter secured by tightening the screw of the instrument. The subcutaneous injection of 2-per-cent. solution of novocaine in 1:4000 adrenalin is sufficient to control pain and bleeding in most of these operations; occasionally general anæsthesia is required.

The Jaesche-Arlt Operation attaches the zone of hair-follicles at a higher level by *shortening the skin of the lid.* The lid is split through its entire length in the intermarginal

FIG. 71.—The Jaesche-Arlt Operation for Entropion. Incisions.

FIG. 72.—The Jaesche-Arlt Operation for Entropion. Completed.

space, so that the anterior lip contains the hair-follicles. A second incision, dividing the skin down to the tarsus, is made 4 mm. from and parallel to the margin of the lid. A third incision extends upward in a curve between the two ends of the second incision. The elliptical piece of skin bounded by the second and third incisions is dissected away (Fig. 71)

without injury to the orbicularis and the margins of the defect are united by fine silk sutures (Fig. 72). In this manner the strip of integument containing the cilia is drawn upward and the lashes are tilted forward, away from the cornea. The area from which the skin and lashes have been displaced may be allowed to cicatrize, or may be covered by the excised strip of integument properly trimmed, which will attach itself in a few days.

Hotz's Operation raises the zone of hair-follicles by *attaching the skin to the upper border of the tarsus.* A curved incision is made through the skin of the lid following the upper

FIG. 73.—The Hotz Operation for Entropion.

FIG. 74.—The Hotz Operation for Entropion (Shown in Section).

border of the tarsus, from 2 mm. above one canthus to a corresponding distance above the other. While the edges of the wound are separated, a narrow strip of orbicularis along the upper border of the tarsus is exsected. The sutures, three or more in number, are then passed through the lower wound margin, upper border of tarsus, returning through the orbito-tarsal fascia, and finally through the upper wound margin (Figs. 73 and 74). This operation may be modified by

the addition of an intermarginal incision, by grooving the tarsus, and by excising a horizontal strip of integument.

The Streatfeild-Snellen Operation aims at straightening the inverted lid by the *removal of a wedge-shaped piece from the*

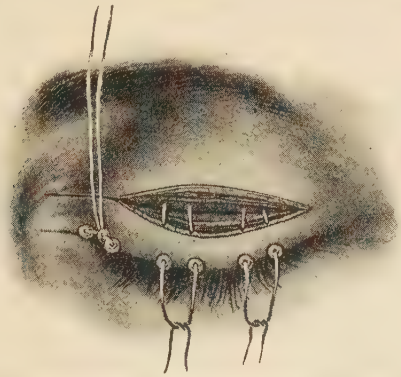

FIG. 75.—The Streatfeild-Snellen Operation for Entropion. One of the Threads has been Tied.

FIG. 76.—The Streatfeild-Snellen Operation for Entropion (Shown in Section).

tarsus. A transverse incision is made through the skin, 2 mm. above and parallel to the margin of the lid along its entire length. A strip of orbicularis is excised, thus exposing the tarsus. A wedge-shaped piece, the apex of which is directed toward the conjunctiva, is removed from the tarsus along its entire length. The cut surfaces of the tarsus are brought into contact by three sutures, provided with needles at both ends, in the following manner: One needle is passed through the tarsus above the groove; both needles are then carried down in front of the wound in the tarsus, and then between tarsus and skin, and brought

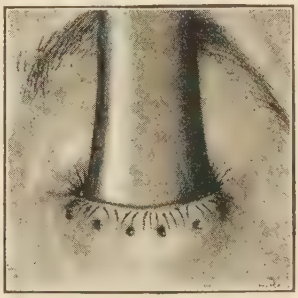

FIG. 77.—Ziegler Galvanopuncture Operation for Senile Entropion.

out just above the free margin of the lid (Fig. 76) about 4 mm. apart. The two threads are tied upon a bead (Fig. 75) and then turned up over the forehead and secured by plaster. The cutaneous wound closes of itself. More pronounced eversion is produced if the threads are passed behind the cilia, emerging just above the posterior lip of the lid margin.

Operations for Spastic (Senile) Entropion include (1) *excision of a horizontal strip of skin* with the underlying orbicularis, the width being gauged so that when pinched up it shall cause the disappearance of entropion without producing ectropion; the margins of the wound are then united by silk sutures; (2) *galvanopuncture* (Ziegler); a blunt-pointed electrode, heated to dull red, is made to penetrate the skin of lower lid 4 mm. from border, 4 mm. apart (Fig. 77), going into the tarsus but not perforating the conjunctiva; cicatrization results in eversion; this operation is useful only in entropion of limited degree and not infrequently has to be repeated after some months; (3) *Hotz's operation* and (4) *canthoplasty.*

FIG. 79.—Canthoplasty.

Canthoplasty consists in an *enlargement of the palpebral fissure* by division of the external canthus. The lids being separated and stretched at the external canthus with the fingers, one blade of blunt-pointed, straight scissors is introduced behind the external commissure as far as possible, and the entire thickness divided, the wound in the skin being made a little longer than that in the conjunctiva. This leaves

a rhomboidal wound. The conjunctiva at the apex of the wound is loosened from underlying tissue and stitched to the centre of the incision in the skin. A second suture is passed through the upper, and a third through the lower part of the wound, uniting conjunctiva to skin (Fig. 79).

The sutures are inserted so as to prevent reunion, thus making the effect *permanent*. If a *temporary* enlargement is desired, we omit the sutures; the operation is then known as *canthotomy* or *temporary canthoplasty*.

The indications for canthoplasty are blepharospasm, spastic entropion, and certain cases of trachomatous pannus. Temporary canthoplasty is indicated in acute purulent conjunctivitis, phlyctenular keratitis and other affections, when swelling of the lids exerts injurious pressure upon the eyeball, in blepharospasm, and in the removal of an enlarged eyeball or an orbital tumor.

ECTROPION

An *eversion of the lid* with exposure of more or less conjunctival surface (Fig. 54, Plate VI, and Fig. 66). It may affect the upper or the lower lid, or both.

Symptoms.—*Epiphora* (from eversion of punctum) causing excoriations and eczema of the lower lid, which, in turn, through contraction, increase the deformity. The *exposed conjunctiva* becomes reddened and hypertrophied. In marked cases the cornea may suffer, as a result of imperfect closure of the lids.

Etiology.—(1) Cicatricial contraction from wounds, operations, burns, ulcers, and caries of the orbital margin or surrounding surfaces (*cicatricial ectropion*). (2) Chronic conjunctivitis and blepharitis associated with considerable hypertrophy (*mechanical ectropion*). (3) Relaxation of the skin and orbicularis in old people (*senile ectropion*), affecting only the *lower* lid. (4) Affections of the facial nerve, causing paralysis of the orbicularis (*paralytic ectropion*), affecting only the *lower* lid. (5) Spasmodic contraction of the marginal

portion of the orbicularis (*spasmodic ectropion*), seen especially in children with acute forms of conjunctivitis associated with considerable blepharospasm.

Treatment.—*Non-operative:* The spasmodic form is frequently relieved by a suitable retaining *bandage* applied after the lid has been properly placed. In the paralytic form we employ a bandage, at the same time attempting to cure the facial paralysis. In the senile form we put on a bandage at night, and slit open the lower canaliculus; we instruct the patient, when wiping away the tears, to press upward and inward and not downward and outward. In slight cases of ectropion associated with much conjunctival hypertrophy, painting the exposed surface with 2-per-cent. solution of *silver nitrate* may be of service. Thorough and persistent *massage* of a cicatrix or of the thickened lid margin of blepharitis may give some relief. When these simple procedures do not answer, and especially in cicatricial ectropion, we must resort to *operative intervention.*

Operations for Ectropion.—In *senile and paralytic* forms of ectropion the lid may be replaced by (1) galvanopuncture; (2) by reduction of the length of the lid-border; and (3) by tarsorrhaphy.

Fig. 80.—Ziegler Galvanopuncture Operation for Senile and Paralytic Ectropion.

Galvanopuncture (Ziegler).—The conjunctiva of the lower lid, everted with Knapp's clamp (Fig. 70), is punctured by a blunt-pointed electrode heated to a dull red; punctures are 4 mm. apart on a horizontal line, 4 mm. from the lid margin (Fig. 80), penetrating the conjunctiva and tarsus but not the skin; cicatrization relieves the ectropion; however, the effects may prove temporary only and the operation may have to be repeated after some months.

Shortening the Margin of the Lid (*Adam's Operation*) is applicable when there is considerable elongation. A wedge-shaped piece is excised from the whole thickness of the lid (Fig. 82), the base corresponding to the margin of the lid and varying from 5 to 10 mm. in width, according to the amount of shortening required; the edges are brought together by a harelip pin and the cutaneous margins by silk sutures (Fig. 83). The piece may be excised from the centre of the lid; but, to prevent notching, it is better to operate at the external canthus.

For *cicatricial ectropion* a great many operative procedures have been advocated. An essential condition for success is the thorough division of all cicatricial adhesions, so that the lid assumes a natural position, the object of any operation being to prevent recicatrization. If the ectropion is slight and but little skin has been lost, it may be sufficient to *divide the cicatricial bands subcutaneously*, or to *cut out the scar*

FIG. 82.—Adam's Operation for Ectropion. Incisions.

FIG. 83.—Adam's Operation for Ectropion. Completed.

portion and bring the margins of the wound together by sutures. A procedure very frequently used is

The V Y Operation (*Wharton Jones*).—A V-shaped incision is made with the apex directed away from the palpebral margin, the incision including the cicatrix (Fig. 84). The skin is freed from underlying parts, not only in the V-shaped area,

but also to either side. The V-shaped area is slid upward until slight inversion of the lid margin is produced. The



FIG. 84.—The V Y Operation for Ectropion. The Incisions have been made and the Sutures are in Position.

FIG. 85.—The V Y Operation for Ectropion. Completed.

margins of the incisions are then brought together by sutures in such a manner that the figure Y results (Fig. 85).

In more extensive cicatricial ectropion a *plastic operation* is usually required (blepharoplasty).

Blepharoplasty consists in *covering the defect* formed by excision of a cicatrix, new growth, or extensive ulceration, with *skin-flaps with a pedicle*, taken from adjacent parts, or with *skin-grafts*. In such operations it is customary to close the lids temporarily by sutures so as to prevent contraction of the cicatricial tissue from undoing the result accomplished by the operation. Of the many blepharoplastic operations with pedunculate skin-flaps, Knapp's, Dieffenbach's, and Fricke's methods are the ones most commonly employed.

Knapp's Method (lower lid) consists in detaching a lateral flap on each side of the defect in the lid, freeing from adjacent tissue, drawing the two flaps over the defect, and uniting by a vertical row of sutures.

Dieffenbach's Method (lower lid) makes use of an adjacent quadrangular flap taken from the cheek and slid inward so as to cover the defect of the lid.

Fricke's Method (upper or lower lid) takes a tongue-shaped flap having the shape of the defect in the lid from the temple or cheek; the base of the flap adjoins one end of the lid wound, and is the part which becomes twisted when the flap is transplanted into the defect.

Skin-Grafting.—The defect is filled in by *one large piece* of skin, occasionally by *a number of smaller ones*, after the lid has been fastened in its proper position by temporarily suturing the two lids together. The grafts are taken from some part in which the skin is thin and delicate, such as the inner side of the arm or thigh, the temple, or the opposite upper lid according to the method of Wheeler. The area of the graft must be one-third larger than the defect to be covered, to allow for shrinkage. The graft may consist of the *entire thickness* of the skin (Wolfe's), or comprise only the *epidermis* (Thiersch's). If the entire thickness of skin is used, the subcutaneous connective tissue and fat are dissected off. The area to be covered must be clean and free from blood. When in place, the graft is covered with a layer of rubber tissue, next gauze, and then a firm bandage is applied. The dressing is not disturbed for four days, and the rubber tissue over the graft is left in place still longer.

Skin-grafting is used very extensively and with excellent results. If a portion of the graft should slough, the defect can be freshened and another graft applied. This method causes less disfigurement than when pedunculate flaps are used. Thiersch's grafts, being thinner and softer than Wolfe's, produce better results cosmetically, and the lid is not so heavy; however, when the graft is taken from the upper lid, the entire thickness of the skin may be employed with ease and with perfect effect.

Tarsorrhaphy.—The object of this operation is to *reduce the width of the palpebral fissure* by uniting the edges of the lids at the *outer commissure*. The edges of the lids are approximated at the outer canthus to the required extent, so as to give the operator exact knowledge as to how much union is desired. A horn or metal spatula is passed behind the outer commissure, and the desired length of the border of each lid is excised, including the hair-follicles. The length of the flap varies according to the effect desired (about 3 to 6 mm.);

its breadth is about 1 mm. To obtain firmer adhesion, the border of the lid, excluding the cilia, is denuded for 2 or 3 mm. beyond the point at which the first incision stops. The denuded edges are then brought together by silk sutures (Fig. 86). This operation is indicated in lagophthalmos, especially in exophthalmic goitre, in some cases of senile and paralytic ectropion, and in connection with blepharoplasty.



FIG. 86.—Tarsorrhaphy.

Ankyloblepharon is the adhesion of the margins of the two lids; it may be partial or complete, congenital or acquired; it is often associated with symblepharon.

Blepharophimosis is an apparent contraction of the palpebral fissure at its outer canthus due to this angle being covered and hidden by a vertical fold of skin. It is seen in lengthy cases of chronic conjunctivitis in which, as a result of epiphora, irritating secretions and blepharospasm, eczema develops and draws the adjoining skin over the canthus.

Symblepharon, a cicatricial attachment between the conjunctiva of the lid and the eyeball, is described in Chapter VII, p. 129.

PTOSIS

A drooping of the upper lid due to paralysis or deficient development of the levator. All degrees of ptosis occur. When marked, it interferes with vision by covering the pupil. Patients attempt to raise the lid by forced action of the occipito-frontalis muscle, wrinkling the skin of the forehead and raising the brow (Figs. 87 and 92); when the condition is bilateral, they also favor exposure of the pupil by throwing the head backward; these actions are characteristic accompaniments of this anomaly. Occasionally we find a curious

example of associated movement in which the patient elevates the upper lid only while moving the jaw.

Etiology.—Ptosis may be congenital or acquired. When *congenital*, it is usually bilateral, due to *deficient development* of the levator, and often associated with other congenital defects; not infrequently it is hereditary. *Acquired* ptosis is usually unilateral; it is caused by *paralysis* of the branch of the *third nerve* which supplies the levator, and is usually associated with paralysis of other ocular muscles supplied by the oculo-motorius; in rare instances, when not associated in this way, isolated acquired ptosis is the result of *cerebral disease.*

FIG. 87.—Ptosis (Right Side).

Mechanical ptosis is a variety due to increased weight of the lid (trachoma, tumors, etc.) or lack of support (atrophy of globe and after enucleation).

Treatment.—In the ordinary variety of the acquired form we *seek the cause of the paralysis* of the third nerve (p. 368) and treat this; syphilitic cases respond well to treatment; *electricity* is used. If such treatment fails to remedy the deformity after a lengthy trial, and in congenital and some mechanical cases, *operation* is indicated.

Operations for Ptosis.—Operations for ptosis are often followed by improvement, but perfect results are not the rule. Their aim is (1) to produce a shortening of the upper lid by excision of a strip of *tarsus;* (2) an elevation of the lid

by connecting it directly with the fibres of the *occipito-frontalis* muscle; (3) an advancement, resection, or both, *of the levator* muscle; (4) to make use of the services of the *superior rectus*.

Excision of an Elliptical Strip of Skin, often including a narrow band of orbicularis (Graefe's Operation), may answer in very slight examples of ptosis; but the effect produced is so limited that this procedure is now rarely employed.

Excision of a Strip of Tarsus (De Grandmont's Operation). —The amount of tarsus removed corresponds exactly to the excess in length of the lid. The tarsal strip may be removed from the external surface through an incision 4 mm. from the lid margin down to the tarsus, or through the mucous surface after eversion of the lid. In either case the conjunctiva covering the strip of tarsus is also excised. If the skin be redundant, a sufficient amount is exsected. The tarsal wound is closed with fine catgut, and the skin incision, if any, with silk. The results of this operation are comparatively satisfactory.

Pagenstecher's Sutures attempt to bring the occipito-frontalis to act on the lid by means of cicatricial bands.

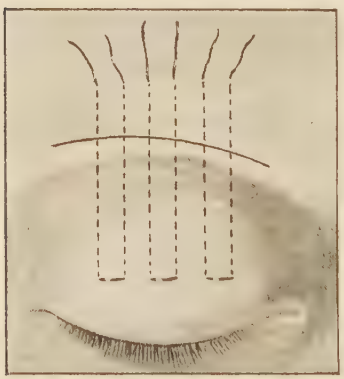

FIG. 88.—Hess' Operation for Ptosis. Incision and Sutures.

FIG. 89.—Hess' Operation for Ptosis. Completed.

Three double threads of silk are passed from near the lid border, where each forms a subcutaneous loop, upward under

the skin, emerging above the brow and tied over rubber tubing. The threads are gradually tightened until they cut their way out or removed after two weeks.

Hess' Operation is a modification of Pagenstecher's. A 3 cm. incision through the skin of the brow permits undermining down to the lid margin. Three double sutures are introduced so as to form loops about 7 mm. from the lid border and passed upwards, beneath the brow, emerging 1 cm. above the incision, where they are tied upon small rolls of gauze (Figs. 88 and 89). The skin wound is closed with sutures. The double threads are allowed to remain for two weeks. The skin of the lid, displaced upward, adheres and gives the occipito-frontalis greater purchase; hence the effects are better than when simple sutures are used.

Panas' Operation.—A horizontal incision (3 cm.) is made in the eyebrow down to the periosteum, and another (2 cm.)



FIG. 90.—Panas' Operation. The Incisions have been made and the Sutures are in place.

FIG. 91.—Panas' Operation. Completed.

equally deep, at the margin of the orbit; this bridge of skin and muscle is undermined. A tongue-shaped flap (15 mm. wide) is marked out, its surface denuded of epithelium, and separated from the lid, including muscle (Fig. 90). This flap

is drawn up under the bridge and stitched to the upper edge of the upper wound by three sutures (Fig. 91). This operation is apt to leave somewhat conspicuous scars.

Advancement of the Levator.—The attachment of the tendon of the muscle to the tarsus is exposed and either tucked on itself, or a portion exsected, producing shortening and increase of power. This operation gives fair results.

Motais' Operation endeavors to assist the action of the levator by exposing and freeing the middle third of the superior rectus muscle and stitching this to the upper border and anterior surface of the tarsus. The ptosis is often lessened, but there is risk of diplopia and depression of the eyeball from weakening of the superior rectus.

Blepharospasm, a tonic or clonic spasm of the orbicularis, closing the lids, is a symptom of ocular disease or of a neurosis. The *tonic form* is present with foreign bodies, fissure at the outer canthus, corneal affections and inflammatory conditions of the eye in general; it is due to irritation of the exposed terminal filaments of the *trigeminus;* rarely it is hysterical; treatment consists in removing the cause. The *clonic variety* often shows itself in *fibrillar twitchings* of a portion of the muscle, especially of the lower lid, and although of no importance, is annoying and often unduly alarming to the patient; in such cases it may depend upon errors of refraction, excessive use of the eyes, or conjunctivitis; clonic spasm may also be an example of "habit chorea"; a very obstinate variety is sometimes seen in elderly persons in whom the marked palpebral spasms are accompanied by similar movements of the neighboring facial muscles, constituting a form of *tic.*

Lagophthalmos is an *incomplete closure* of the palpebral fissure when the lids are shut, as a result of which there is exposure and consequent injury to the bulbar conjunctiva and the cornea. The condition may be due to congenital or acquired shortening of the lids, ectropion, paralysis of the

orbicularis, and protrusion or enlargement of the eyeball; it is seen also in unconscious and moribund individuals.

Epicanthus is a congenital condition, sometimes associated with ptosis, usually bilateral, in which a perpendicular fold of the skin extends from the root of the nose to the inner end of the brow, concealing the inner canthus and caruncle (Fig. 92). In Mongolians it is a racial characteristic. In slight degree it is often seen in young children associated with a flattened bridge of the nose, and often disappears with the development of the face. When sufficiently marked to constitute a deformity, it can be relieved by excising an elliptical piece of skin from the root of the nose, long axis vertical, and stitching together the free margins.

FIG. 92.—Epicanthus and Ptosis.

TUMORS OF THE LIDS

Benign Tumors include xanthelasma, molluscum, verruca (wart), fibroma, cyst, nævus, and milium.

Xanthelasma (*Xanthoma*) is a flat or slightly raised, yellowish discoloration beneath the skin, usually multiple, found most frequently near the inner canthus in elderly women; it is due to fatty degeneration of connective-tissue cells with pigment deposits. Xanthelasmata call for no interference except for cosmetic reasons; they may be removed by excision, monochloracetic acid, or by electrolysis.

Molluscum Contagiosum is a small, white, rounded tumor, about the size of a small pea, presenting a depression at its

apex; several usually occur upon the eyelids at the same time; they represent a diseased condition of the sebaceous glands, contain a small quantity of sebaceous material, and are often considered contagious. They should be incised, the contents forced out, and the base touched with the stick of silver nitrate.

Milium is a small, yellowish-white elevation about the size of a pin's head, due to retention in a sebaceous gland.

Small Cysts, with transparent contents, due to obstruction in the outlet of sweat glands, are often seen on the lid border; they give rise to irritation and should be punctured with a needle or knife point.

The others resemble tumors of the same class occurring in other parts of the body. Benign tumors of the lids may be *excised,* providing no deformity results from the operation.

Malignant Tumors.—Of these, sarcoma is rare, but carcinoma more common.

Carcinoma, when it attacks the lids, usually assumes that form of epithelioma known as *rodent ulcer.* This occurs in elderly persons, especially at the *inner end of the lower lid margin.* It begins as a small pimple or wart, covered by a crust, soon changes to an ulcer with indurated walls, and spreads, if unchecked, to neighboring parts. Its growth is, however, *slow,* and many years may elapse before it assumes considerable size. Treatment: Exposure to *x-rays or radium,* which is effective in early stages and indicated in every case. *Excision* is proper, but liable to leave disfigurement, since the growth includes lid margin. When advanced, *escharotics* (chloride-of-zinc paste, chloracetic acid, carbon dioxide snow) are also used. Cutaneous defects may require subsequent blepharoplasty.

INJURIES OF THE EYELIDS

These are quite common, and include contusions, wounds, burns, and insect bites. Ecchymosis and œdema are often marked symptoms on account of the looseness of the subcutaneous connective tissue.

Ecchymosis (*"black eye"*) is usually of no importance, merely causing disfigurement, which lasts one or two weeks. If seen immediately, *cold compresses* are of service. After a day or two, *hot compresses* and gentle *massage* are indicated to promote absorption of the extravasated blood. Occasionally in debilitated individuals, especially if associated with abrasion, abscess of the lid results, and may require horizontal incision. In fracture of the base of the skull, blood may travel along the floor of the orbit, and after a day or two appear in the lower lid and bulbar conjunctiva.

Insect-bites give rise to a great deal of *swelling*, which is best controlled by *cold compresses*.

Incised Wounds cause considerable gaping, if vertical, on account of division of the orbicularis, and then the scar is apt to be noticeable; if horizontal, the lips of the wound do not tend to separate, and usually heal without deformity. Incised wounds should be *cleansed* and *stitched* at once, using fine silk and delicate needles. A vertical wound of the margin must be carefully sewed so that no indentation will remain.

Lacerated and Contused Wounds, if extensive and accompanied by much swelling, should not be closed at once. The wound should be thoroughly *cleansed*, and after the swelling has subsided the edges may be *brought together*. Injured parts, however slenderly attached, should not be removed if there is any chance of union. Care must be taken not to produce deformity or shortening. It may be advisable to use skin-grafts.

Burns should be irrigated with solution of boric acid, dried, and covered with a bland oil or *ointment;* covering with gauze wet with a solution of sodium bicarbonate will be soothing and lessen the pain; when granulating, skin-grafts should be supplied if the defect is extensive. In *powder burns*, the particles should be picked out with a fine needle or removed with hydrogen peroxide.

Emphysema associated with injury to the lids denotes a solution of continuity of the walls of the orbit, permitting

communication with the neighboring nasal or nasal accessory cavities. The lids will present a *soft swelling* of considerable size, often closing the palpebral aperture; bubbles of air, becoming displaced in palpation, give rise to the sensation of *crepitation*. A firm *bandage* will hasten the disappearance of the air. The patient must be instructed to avoid any straining efforts such as blowing the nose, which will increase the emphysema.

CHAPTER V

DISEASES OF THE LACRYMAL APPARATUS

Anatomy and Physiology.—The lacrymal apparatus consists of a *secretory portion*, the lacrymal gland, and an *excretory portion*, which collects the tears and conducts them into the inferior meatus of the nose.

The lacrymal gland is a small, oblong body, placed in the upper and outer part of the orbit and divided into two portions. The upper part, the larger, about the size of a small almond, is situated in a depression in the orbital plate of the frontal bone, the lacrymal fossa, to which it is fixed by connective tissue; the lower division, the smaller, is known as the accessory lacrymal gland, and is placed just beneath the outer part of the conjunctiva of the fornix. In structure the lacrymal resembles the salivary glands, consisting of acini containing cuboidal cells. The excretory ducts of both portions of the gland, the lacrymal ducts, six to twelve in number, pass downward and empty into the external half of the superior fornix conjunctivæ by separate orifices.

Fig. 93. — Diagrammatic Illustration of the Excretory Portion of the Lacrymal Apparatus.

The excretory portion of the lacrymal apparatus (Fig. 93) consists of the puncta, the canaliculi, the sac, and the duct. The *puncta* are two minute openings, one of which is seen upon an elevation on each lid about 6 mm. from the inner canthus; they are the orifices of the *canaliculi*. The latter extend vertically for a short distance, and then, continuing at right angles, pass horizontally inward in a curved course, and empty separately or together into the lacrymal sac.

The *lacrymal sac*, situated at the inner side of the internal canthus, is the upper, dilated portion of the lacrymo-nasal duct, and is placed in a groove formed by the lacrymal bone and the nasal process of the superior maxillary bone; it measures 12 mm. in the vertical and 6 mm. in the horizontal and transverse diameters; its walls are thin; it is covered in front by the internal tarsal ligament and some fibres of the orbicularis muscle.

The *nasal duct* passes downward and slightly outward and backward in a canal formed by the superior maxillary, lacrymal, and infe-

rior turbinated bones, and terminates below in the fore part of the inferior meatus of the nose; its length varies from 18 to 24 mm., and its diameter from 4 to 6 mm.; it is somewhat contracted where it joins the sac and again at its lower extremity. Both sac and duct are formed of fibrous and elastic tissues, and mucous membrane lined with columnar epithelium which may be ciliated; the lower part of the duct is surrounded by a dense plexus of veins.

The *lacrymal secretion* is a slightly alkaline liquid containing a comparatively large amount of sodium chloride. Ordinarily the lacrymal gland secretes just enough to moisten the eyeball, and this is lost by evaporation. As the result of psychical stimulation or of irritation of the eye or the nose, there is increased secretion. The conveyance of tears from the conjunctiva to the lacrymal sac is effected by the act of winking, the lubrication of the margins of the lids by fatty material ordinarily preventing the tears from flowing over.

Epiphora ("watery eye"), an *overflow of tears* upon the cheeks, is a prominent symptom in all affections of the tear-conducting apparatus. It may also be dependent upon increased secretion (foreign bodies, inflammations, exposure to bright light and smoke, affections of the nose, irritation affecting the terminal twigs of the trigeminus). The two forms may be combined.



FIG. 94. FIG. 95. FIG. 96.

FIG. 94.—Probe-Pointed Canaliculus Knife.

FIG. 95. Punctum and Canaliculus Dilator.

FIG. 96. - Lacrymal Knife.

Anomalies of Puncta and Canaliculi. — Normally, the lower punctum is directed backward and upward toward the eyeball.

Eversion of the Punctum.— In this anomaly the lower punctum looks forward and away from the depression in which the tears accumulate, and the result is *epiphora*. The condition may be due to a relaxed state of the lids in old age and in facial palsy, to conjunctivitis, blepharitis, and ectropion. It is remedied by *slitting* the lower canaliculus with

the probe-pointed canaliculus knife (Fig. 94), and keeping it open by separating the edges of the incision daily for two or three days. It is sufficient to open up the outer two-thirds of the canaliculus.

Contraction and Obliteration of the Puncta and Canaliculi may be congenital, or acquired as a result of wounds and inflammations of this region. Foreign bodies, such as an eyelash or a concretion (streptothrix), may obstruct the canaliculi; treatment consists in their removal with delicate forceps, slitting the canaliculus if necessary. In stenosis, *dilatation* with a canaliculus dilator (Fig. 95), or *slitting* the canaliculus is indicated.

Diseases of the Lacrymal Apparatus may be divided into those of the gland and those of the conducting portion.

The former (acute and chronic *dacryoadenitis*) are very *rare;* the latter (acute and chronic *dacryocystitis*) are very *common.*

CHRONIC DACRYOCYSTITIS

A *chronic inflammation of the lacrymal sac* usually due to an *obstruction* in the nasal duct. It is also known as blennorrhœa of the lacrymal sac.

Symptoms.—The constant symptom is *epiphora,* increased by exposure to cold, wind, dust, smoke, etc. There may be *fulness* in the region of the lacrymal sac; this distention is known as *mucocele* (Fig. 55, Plate VI). By pressing upon the distended sac, a *viscid fluid* of whitish, yellowish, or slightly greenish color (depending upon the amount of pus) escapes from the puncta; but sometimes the sac is emptied in the reverse direction, and the accumulation is pressed into the nose. A form of chronic conjunctivitis affecting chiefly the inner canthus (*lacrymal conjunctivitis*) and blepharitis are frequently present; eczema occurs sometimes, and there may be ectropion. As a result of contamination by micro-organisms from the conjunctiva (especially streptococci and pneumococci (Figs. 117 and 114, Plate VIII), a *purulent inflam-*

mation of the lining of the sac is set up. The *infectious* character of the accumulation is shown, when any abrasion or ulcer of the cornea exists, by the readiness with which the wound or ulcer becomes infected and hypopyon keratitis results. In operations upon the eye, such a condition is a very frequent cause of infection.

Course is chronic and extends over *years;* a long period may elapse before the patient seeks relief. After the muco-purulent material has filled the sac for a long time, there is atrophy of its mucous membrane and the character of the contents of the distended, atonic walls changes; the accumulation becomes more watery and consists principally of the tears contaminated with an abundance of micro-organisms. There exists constantly the danger of development of lacrymal abscess.

Etiology.—In most cases there is *obstruction of the nasal duct,* either from swelling or organic stricture, the result of an affection of the nasal cavity, usually *rhinitis.* Less frequently, nasal polypi and hypertrophy of the inferior turbinate are causes and, more rarely, ulcerations, caries, and periostitis are responsible.

The affection is not very uncommon in the new-born and in young infants in whom it is supposed to be due to adhesion of the lining of the duct or congenital obstruction of its lower end.

Treatment.—In recent and slight cases, we may relieve the epiphora by *curing the nasal affection* which produces the obstruction. Locally, *stimulating and astringent remedies,* such as a solution of zinc sulphate, may be dropped upon the inner part of the eyeball, followed by gentle *massage* over the sac so as to favor entrance of some of the remedy, after the patient has emptied the sac by pressure. The sac should be washed out with *warm and weak solutions* of salt, boric acid, or zinc sulphate, using a small syringe with delicate nozzle (Fig. 97). Semi-weekly irrigations of *argyrol* (5 to 10 per cent.) are used; but there is risk attending the employment of this remedy,

since, if for any reason the solution escapes into the surrounding tissues, permanent staining and other serious consequences may result. *Dilatation of the lower punctum* is advisable and often a necessary preliminary to syringing; for this purpose we use a fine conical sound, the canaliculus dilator

FIG. 97.—Anel's Lacrymal Syringe.

(Fig. 95). If the nasal duct is pervious, the solution will enter the nose and escape from the anterior nares when the patient inclines the head forward.

Conservative treatment as outlined above will be successful in a fair proportion of cases, especially if the nasal affection and the conjunctivitis be looked after; such management is



FIG. 98.—Weber's Conical Sound.

FIG. 99.—One of Bowman's Lacrymal Probes.

almost always sufficient in dacryocystitis of the new-born and young infants.

If, however, such treatment, conscientiously and persistently carried out, is unsuccessful, we may resort to *dilatation with probes*—either Weber's conical sound (Fig. 98), or Bowman's probes (Fig. 99) which are numbered from 1 to 8,

the largest (8) being about 2 mm. in thickness; they are curved before use. Probes of greater calibre (Theobald's) are sometimes used. Though the smallest probes may be passed through the natural opening after dilatation, it is customary to slit the lower canaliculus in advance. Probing is facilitated and rendered less painful by the preliminary syringing of a few drops of a solution of 2-per-cent. novocain in 1:3000 adrenalin into the sac and duct.

To Slit the Canaliculus.—The surgeon stands behind and supports the patient's head against his body, or he may stand in front. Weber's probe-pointed canaliculus knife

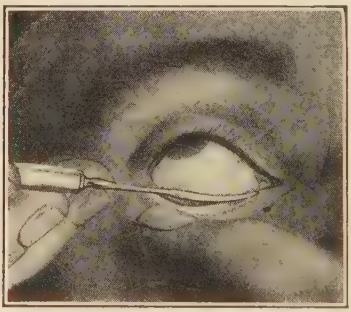

FIG. 100.—Slitting the Lower Canaliculus. First Step.

FIG. 101.—Slitting the Lower Canaliculus. Final Step.

(Fig. 94) is most frequently used. The lower lid is pulled outward by the thumb of one hand, and with the other the knife is introduced vertically, until it passes the punctum, and then horizontally; its edge is upward and looks toward the eyeball so as to cut into the conjunctiva and not into the integument (Fig. 100). It is pushed horizontally inward until its extremity meets with the firm resistance of the inner bony wall of the sac; then the knife is raised into a vertical position (Fig. 101).

To Pass Probes into the Nasal Duct.—Commencing with a small size, say a No. 3, we pass this horizontally inward exactly as the knife is passed, the surgeon standing behind (or

in front of) the patient. When the probe reaches the inner wall of the sac, which we can be certain of when in lifting the probe there is no wrinkling of the skin of the lower lid, it is raised so that its lower end points toward the furrow between nose and cheek. It is then pushed downward *gently*, until it reaches the floor of the nasal fossa (Fig. 102). If the probe does not pass readily, we *must not use force* for fear of injuring the wall of the duct or creating a false passage, but withdraw it slightly and try again, or try a smaller or larger size. The probe is left in from fifteen to thirty minutes, and the proceeding is repeated every other day, gradually using larger probes; then the intervals between probing are increased.

FIG. 102.—Passing a Probe into the Nasal Duct.

Sometimes the stricture is cut, a strong, narrow knife (Fig. 96) being passed in the same manner as a probe, and the obstruction divided in two or three directions; this is immediately followed by probing.

In some cases leaden or silver *styles* are passed and left in for days or weeks, being removed from time to time for cleansing.

Even with all this treatment, permanent cures are rather the exception in severe cases; there will be *temporary relief* and then the affection returns. The most favorable cases are those in which there is merely swelling of some part of the duct and the condition has not existed for too long a period.

When *complete occlusion* exists, we cannot expect a cure. In such cases and in others of an *obstinate* nature, we may *slit both the upper and lower canaliculi* and divide the tissue between these two, keeping open the cavity thus formed until there is no longer any tendency to unite; this converts the sac into an open space which the patient can keep clean.

In obstinate and long-standing cases in which other measures have failed and the sac is dilated, a lacrymal fistula is present, impermeable stricture exists, or the patient cannot or will not submit to the tedious process of probing, or we wish to prepare an eye for operation, radical treatment (*extirpation of the sac*) is indicated. In such instances operation is advisable in order to relieve the discomfort of epiphora, to remove the liability to repeated attacks of abscess, and to get rid of an ever-present infectious collection which, when the cornea is affected, becomes a source of danger to the eye.

Extirpation of the Lacrymal Sac.—Local injection anæsthesia with 2-per-cent. novocaine in 1 : 4000 adrenalin is used; general anæsthesia is rarely needed. A curved incision, commencing just above the internal canthal ligament, which may or may not be divided, and passing downward and outward along the orbital margin for 2 cm., divides successively the skin and underlying fasciæ until the sac is exposed (Fig. 103). Hemorrhage is annoying, but can be controlled by retractors (special instruments, Mueller's and Axenfeld's, have been devised), by compression, and by the use of adrenalin solution. Using the anterior crest of the lacrymal groove as a guide, the sac is separated from periosteum with the aid of the handle of a scalpel and

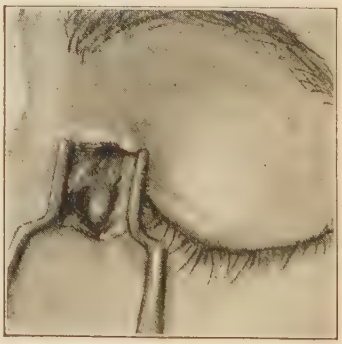

FIG. 103.—Extirpation of the Lacrymal Sac.

blunt scissors, beginning internally, care being taken not to penetrate the wall; its upper extremity is freed and the canaliculi divided; it is cut off as low down in the canal as possible. The excised sac is examined carefully to make sure that no portion has been left behind. The nasal canal is curetted. After thorough disinfection, the edges of the incision are brought together with three sutures, dusted with iodoform, and a dressing applied by means of which pressure is exerted; this is kept on for a few days. There is usually primary union with obliteration of the cavity, and little or no scar ensues. This operation abolishes the conduction of the tears, but there is generally little annoyance from epiphora, probably through cure of the lacrymal conjunctivitis.

Incision into the lacrymal sac for treatment or destruction of its lining is now rarely resorted to since extirpation is considered a more certain and better procedure.

ACUTE DACRYOCYSTITIS

An acute purulent inflammation of the region of the lacrymal sac occurring in the course of chronic dacryocystitis, ending in *abscess*. It is also known as *Abscess of the Lacrymal Sac* (Fig. 56, Plate VI).

Symptoms.—The skin over the lacrymal sac becomes *reddened, swollen,* and *brawny;* this condition extends to *adjacent portions* of the lids and conjunctiva, and is often sufficiently pronounced to lead to a suspicion of erysipelas. There are great *pain* and *tenderness,* some *fever* and constitutional disturbance. After two or three days a yellow discoloration appears at a point usually somewhat below the sac, indicating the formation of an *abscess*. The evacuation of the *pus* is followed by relief and a subsidence of symptoms.

The opening may *heal* completely, and the case again have the symptoms and slow course of chronic dacryocystitis. In other cases the opening *persists,* often encircled by granulations, and the escaping fluid changes its character and be-

comes watery; this constitutes *lacrymal fistula*. As long as this remains open, the patient is safe; as soon as it closes, he is liable to have a recurrence of abscess. Sometimes merely a minute passage is left, insufficient to admit a probe, from which a drop of fluid escapes from time to time.

Etiology.—Lacrymal abscess involves not only the sac, but the surrounding connective tissue as well. The germ-laden contents of the sac find a small defect in the lining, through which they reach the neighboring tissues and excite inflammation and suppuration.

Treatment.—If the case is seen *early*, we try to prevent the formation of abscess by *pressing out* the accumulation and *syringing* with mild antiseptic solutions (boric acid or bichloride 1:6000). If this cannot be done on account of the marked swelling and tenderness or is not effective, as is often the case, we hasten the formation of pus by means of *hot compresses*.

As soon as *fluctuation* occurs, we make a *free incision* through the abscess, entering the knife where the pus presents and cutting downward and outward. After evacuation, the incision is *kept open* by a strip of gauze which is changed daily, until all inflammatory signs have disappeared and the fluid is no longer purulent. We try to *restore permeability* of the duct, after which the fistula often closes spontaneously. If this does not happen after the duct becomes pervious, we freshen and unite the edges of the opening, or scrape out the track with a sharp curette. In most instances, however, it will be advisable and necessary to *extirpate the sac*, but never until all acute symptoms have subsided.

CHAPTER VI

DISEASES OF THE ORBIT

Anatomy.—The orbit is formed of bony walls having the shape of a quadrilateral pyramid; the apex corresponds to the optic foramen; the base is directed forward and corresponds to the strong, thick, projecting, anterior margin. The nasal wall, the thinnest, is formed by the lacrymal bone and the os planum of the ethmoid; it presents in front the groove for the lacrymal sac. The inner walls of the orbits are almost parallel, but the outer diverge considerably from each other from behind forward.

The apex or posterior portion of the orbit presents three *openings* leading to adjacent cavities: (1) the optic foramen, transmitting the optic nerve and the ophthalmic artery; (2) the sphenoidal fissure, transmitting the ophthalmic vein, the nerves for the ocular muscles, and the first branch of the trigeminus; (3) the sphenomaxillary fissure, transmitting branches of the second division of the trigeminus.

Besides communicating with the cavity of the skull by means of the openings at the apex, the orbit is *surrounded by a number of other cavities*. These are the nasal fossæ and accessory cavities—the ethmoidal and sphenoidal sinuses, the frontal sinus, and the antrum of Highmore; these relations are important.

The *contents* of the orbit consist of the eyeball and optic nerve, the ocular muscles, the lacrymal gland, blood-vessels, and nerves; the spaces between these are filled with fat and fasciæ.

The *eyeball* is composed of the segments of two spheres; the anterior (cornea), about 12 mm. in diameter, is the smaller and more prominent; the larger, posterior, corresponds to the sclera. The eyeball measures about an inch in diameter (24.5 mm. from side to side, 24 mm. from before backward, and 23.5 mm. from above downward).

The orbital fascia is extensive and presents numerous subdivisions. It serves as *periosteum* to the walls of the orbit (*periorbita*). A portion closes in the opening of the orbit forming an anterior wall and extending from the margin of the orbit to both tarsi, and to the external and internal tarsal ligaments, thus constituting the *septum orbitale*. Prolongations of the orbital fasciæ surround the muscles and connect them with one another, the lids, and the margins of the orbit.

In addition, a layer of fascia surrounds the globe from the cornea to the posterior part, separating the organ from the orbital fat and form-

ing an articular socket, which permits free movement of the eyeball in every direction. This investment is known as *Tenon's capsule.* The contiguous surfaces of the sclera and of Tenon's capsule are smooth and lined with endothelium. In this manner a lymph space is formed, known as Tenon's space, which is continuous posteriorly with the

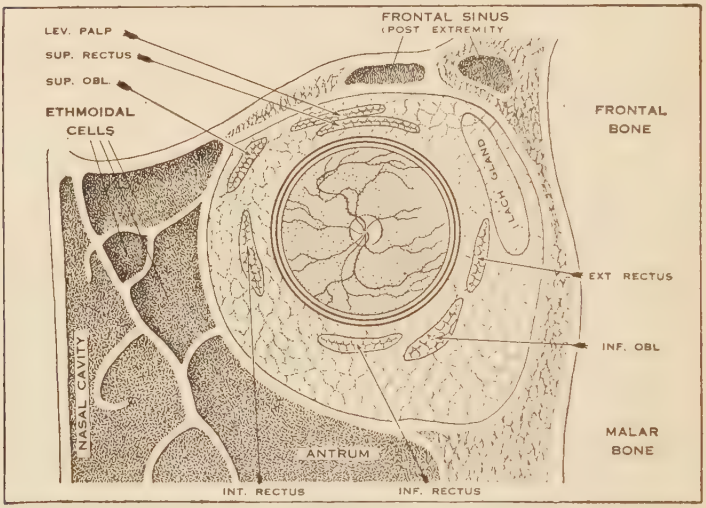

FIG. 104.—Coronal Section Showing the Orbit and Adjacent Cavities.

supravaginal space surrounding the external sheath of the optic nerve. Where the tendons of the ocular muscles pierce Tenon's capsule, the latter is reflected upon them, becoming continuous with their fasciæ.

The *arteries* of the orbit are derived from the ophthalmic. The *veins* empty into the ophthalmic veins, which pass through the sphenoidal fissure to the cavernous sinus. The *nerves* of the orbit are motor and sensory; the motor nerves, the third, fourth, and sixth, supply the ocular muscles; the sensory nerves are the first and second branches of the trigeminus. The *ciliary ganglion* lies to the outer side of the optic nerve; it receives motor fibres from the third, sensory fibres from the fifth, and sympathetic filaments from the carotid plexus; it gives off the short ciliary nerves which enter the eye at its posterior part. The orbit contains no lymph-vessels or lymphatic glands.

Affections of the Orbit include periostitis, cellulitis, thrombosis of the cavernous sinus, tenonitis, pulsating exophthal-

mos, ocular manifestations of disease of the nasal accessory sinuses, tumors, and injuries.

Exophthalmos (proptosis), a *protrusion of the eyeball* from the orbit, is a common sign in affections of this region (Fig. 105). It is caused by inflammations, tumors, and injuries of the orbit, enlargement of the eyeball from various causes, dilatation of adjoining cavities, pulsating exophthalmos, thrombosis of the cavernous sinus, Graves' disease, and sometimes chronic nephritis and acromegaly, and some cases of paralysis and tenotomies of the recti muscles. It is apt to produce conjunctival congestion and epiphora; when marked it may cause *interference with* the *mobility* of the eyeball, *imperfect closure* of the lids (lagophthalmos), with resulting keratitis from exposure, ectropion of the lower lid, *diplopia* (if lateral displacement is added), and interference with vision from optic nerve inflammation and atrophy. *The Exophthalmometer* is an instrument for measuring the degree of proptosis.

FIG. 105.—Exophthalmos (Right Eye).

Enophthalmos is the *recession of the eyeball* into the orbit. With the exception of the cases seen in the aged and in extreme emaciation, due to the decrease of orbital fat, it is rare. Other causes are cicatricial contraction following orbital injuries and cellulitis, fracture of the wall of the orbit, paralysis of the sympathetic, and congenital defect.

ORBITAL PERIOSTITIS

An inflammation of the orbital periosteum, either *acute* or *chronic* in its course, and either *limited* to a portion of the margin of the orbit or *spreading* more deeply. The products of inflammation often consist merely of a *thickening* of the membrane; sometimes there is a *deposit* of bone or gumma (syphilis); there may be the formation of an *abscess*, with or

without subsequent *caries* or *necrosis* of a part of the wall of the orbit.

Symptoms.—These depend upon whether the affection runs an acute or a chronic course, the part of the orbit involved, and whether a subperiosteal abscess results.

The most common variety is that attacking the *margin* of the orbit. In such a case there may be no other symptoms than pain, tenderness on pressure at the orbital margin, hard immovable *swelling* in this situation, and some swelling of the lids and conjunctiva; the amount of constitutional disturbance will depend upon the acuteness of the process. Such a case frequently results in complete *absorption* of the products of inflammation; less commonly, periosteal *thickening* or bony deposit remains. If, on the other hand, there is pus, a subperiosteal *abscess* is developed at the margin of the orbit, which perforates the skin, leaving a *fistula* through which the probe detects either bare or necrosed bone. Such a fistula remains open for months until all the dead bone has been extruded, and after it heals there is a depressed *scar* and sometimes ectropion and lagophthalmos.

If the periostitis is situated more *posteriorly*, there will be more pain, and this will be of a deep-seated character and accompanied by tenderness on pressure upon the globe; there will be considerable swelling and redness of the lids and conjunctiva and sometimes exophthalmos; the constitutional symptoms will be pronounced. Such cases may result in *absorption* of the products of inflammation, or in periosteal *thickening* or bony deposit; the diagnosis of this type is often difficult. But if such a deep-seated process goes on to the formation of an *abscess*, it becomes much more serious and presents the *symptoms of orbital cellulitis*, from which it frequently cannot be differentiated; the pus finds its way to the surface, but this may take some time; cases of this sort, especially if they involve the roof, may be dangerous to life through extension to the cranial cavity and the occurrence of meningitis or cerebral abscess.

Etiology.—*Injuries; tuberculosis* (in children); *syphilis* (tertiary stage, in adults); rheumatism; extension from affections of nasal accessory sinuses. With all causes, traumatism is often the exciting factor. Rheumatic and syphilitic cases usually run a chronic course and produce periosteal thickening without any tendency to suppuration.

Treatment.—That of syphilis, rheumatism, or tuberculosis, when these are present. Locally, moist, *warm compresses. Incision* as soon as we suspect suppuration. A deep incision by means of a narrow knife, keeping along the wall of the orbit, is indicated early, even before fluctuation, so as to prevent extension to the brain; the opening is *drained* by means of a strip of iodoform gauze, until pus no longer escapes. Caries and necrosis may require subsequent operative intervention.

ORBITAL CELLULITIS

Orbital Cellulitis is an inflammation of the *cellular tissue* of the orbit, usually terminating in *suppuration*, in which case it is also known as *Orbital Phlegmon* or *Retrobulbar Abscess.* It runs a more or less *acute* course, generally accompanied by marked constitutional symptoms.

Symptoms.—Great *swelling* of the lids, chemosis, *exophthalmos*, *impairment of mobility* of eyeball, violent *pain* in the orbit increased by pressure upon the eyeball; these local signs are accompanied by marked *constitutional symptoms*, with high fever; cerebral symptoms may be added. Vision may not be affected, but usually it is reduced and it may be abolished owing to the occurrence of optic neuritis followed by atrophy. After these symptoms have lasted about a week *pus* appears at a certain part of the skin of the lids (usually below the supraorbital margin) and perforates or, less frequently, it may empty into the fornix. After the evacuation of pus, the symptoms subside and the opening heals, often leaving the eye with some permanent damage.

Occasionally we see *mild forms* of orbital cellulitis with

very moderate local symptoms, little if any constitutional disturbance and no sequelæ; in such cases the exudate is absorbed without formation of pus.

Complications.—Optic neuritis; less frequently, thrombosis of the retinal veins and of the cavernous sinus; occasionally panophthalmitis. The process may extend to the brain and be fatal.

Etiology.—Extension of disease of the *nasal accessory sinuses*, especially ethmoid, or from neighboring foci such as orbital periostitis or the teeth; injuries and operations of the orbit followed by *infection;* foreign bodies in the orbit; facial erysipelas; metastasis (pyæmia, puerperal septicæmia, etc.); acute infective diseases, especially influenza; cold (idiopathic).

Treatment.—*Hot fomentations. Early and deep incision* at the spot where we suspect the abscess to be situated, being careful not to injure the orbital contents. Even when we do not strike pus, we relieve tension, promote bleeding, add to the patient's comfort, and prepare a route for the subsequent evacuation of pus; this is then drained with tubing or gauze. Foreign bodies should be removed. Neighboring infecting foci must be exposed and treated.

Tenonitis, a rare affection, is a *serous inflammation of Tenon's capsule* resulting in a cure in a few weeks. Its symptoms are moderate swelling of the upper lid, chemosis, slight exophthalmos, limitation of movements of the eye, and some pain on motion of eyeball. It may follow an injury or tenotomy of one of the recti muscles, exposure to cold, be idiopathic, or due to rheumatism or gout. Treatment consists of warm fomentations and the treatment of the rheumatism or gout if present.

Thrombosis of the Cavernous Sinus (almost always infective) may be due to extension of a thrombus in the orbital veins occurring in orbital abscess, or may be caused by other neighboring pus foci situated in the pharynx, tonsils, teeth, and the nasal accessory sinuses, or may follow erysipelas, caries of the petrous bone, and metastasis in pyæmia and the infective diseases. The signs and symptoms are similar to those of orbital abscess; in addition there are neuroretinitis

and *marked distention of the retinal veins* and *severe cerebral symptoms.* The disease is always fatal.

Pulsating Exophthalmos presents the following symptoms: Exophthalmos, pulsation of the eyeball and surrounding parts, bruit heard over the eye and forehead, noises in the head, pain, marked distention of the blood-vessels of the retina, conjunctiva, and lids, and occasionally optic neuritis. Compression of the carotid of the same side causes a diminution or disappearance of the pulsation and bruit. It is most frequently produced by an arterio-venous aneurism involving the internal carotid artery and the cavernous sinus, generally caused by traumatism such as a penetrating wound of the orbit or a severe blow or fall on the head; it may be due to aneurism of the ophthalmic artery or one of its branches, or of the internal carotid, or to a vascular tumor. The condition may be fatal from hemorrhage. Treatment consists in digital or instrumental compression or ligation of the common carotid; or ligation of the ophthalmic veins or the angular vein. Many but not all cases are cured by these means.

Intermittent Exophthalmos is a rare condition, due to varicose veins in the orbit, in which there is exophthalmos when the head is depressed, followed by a natural position of the eyeball or enophthalmos when the head is erect.

The Ocular Manifestations of Disease of the Nasal Accessory Sinuses comprise not only affections of the orbit and its contents due to *extension,* but include *characteristic visual defects* which are of great value in the diagnosis of certain chronic forms of sinus disease. The accessory sinuses of the nose (frontal sinus, anterior and posterior ethmoidal cells, sphenoidal sinus, and maxillary antrum) surround the orbit, being separated by bony walls which are very thin in spots. They are lined by an extension of the nasal mucous membrane and as a result of such relationship often become *infected.* Whenever the natural outlet for each sinus becomes blocked, there will be an accumulation of secretion and consequent *distention* of the walls of the sinus, often with encroachment upon the orbit and exophthalmos. If this retention is of a mucoid character the condition is known as *mucocele;* if of a purulent character, as *empyema.* Such a sinusitis may run an acute or a chronic course.

Frontal Sinusitis is often accompanied by a *bulging* at the upper and inner angle of the orbit with tenderness on pressure over this area and sometimes redness of the overlying skin, severe frontal headache and dizziness on stooping. There may be protrusion of the eyeball downward and outward, diplopia, *œdema of the lids*, conjunctival and episcleral congestion, and lacrymation. Orbital periostitis and cellulitis may result.

Ethmoiditis may present a *tumefaction* at the upper and inner part of the orbit with *swelling* of the integument of the adjacent lids, *displacement of the globe* downward and outward, diplopia, marked pain, conjunctival and episcleral congestion, and lacrymation. The process may involve the orbit, causing periostitis or cellulitis. The affection is responsible for certain cases of uveitis and iritis.

Disease of the Sphenoidal Sinus is usually associated with ethmoiditis. The walls of this cavity and the *optic nerve* are contiguous and this close relationship explains the frequent occurrence of optic neuritis and retrobulbar neuritis in affections of the sphenoidal sinus. Many examples of disease of this sinus (including ethmoiditis) present no external evidences of inflammation and yet give well-marked and frequent ocular complications among which are *optic neuritis*, *neuroretinitis*, and *retrobulbar neuritis*, leading to optic-nerve atrophy if the cause is not removed. *Uveitis and iritis* may also be sequels. There is frequently present a central, paracentral, or annular *color scotoma*, which later may become absolute, usually without any or with but little contraction of the visual field. Another fairly constant symptom is *enlargement of the blind spot*. *Asthenopia* and deep-seated *pain* are often complained of. These functional symptoms are important indications for exploring the sphenoidal and ethmoidal sinuses.

Antrum Disease is not often accompanied by ocular symptoms. There may be pain, swelling of the lids, conjunctival congestion, and lacrymation, but involvement of the orbit is rare.

Exophthalmic Goitre.—The exophthalmos and other ocular symptoms accompanying this disease are described in Chapter XXVII, p. 415.

Tumors of the Orbit are of *infrequent* occurrence; they may arise from the walls or contents of the orbit or spring from neighboring cavities. The symptoms will depend upon the size, position, and nature of the tumor. *Exophthalmos* is usually present; the direction of the protrusion and the impairment of motion of the eyeball will be determined by the exact situation of the tumor. Pressure upon the optic nerve may cause optic neuritis or retrobulbar neuritis and, later, atrophy. When located forward or after it has reached a certain size, the tumor may be felt by the tip of the finger passed between the margin of the orbit and the eyeball. Benign tumors usually grow slowly and frequently give rise to but few symptoms; malignant tumors are apt to increase in size very rapidly. *Benign* tumors of the orbit include dermoid cyst, aneurism, angioma, pulsating exophthalmos, meningocele, osteoma, and distention of neighboring cavities. *Malignant* tumors are sarcoma (the more common) and carcinoma.

Benign tumors demanding excision and certain encapsulated sarcomata should be removed with preservation of the eyeball, if possible; Krönlein's operation may be resorted to (p. 91). Non-encapsulated malignant tumors and others of large size, the excision of which would certainly be followed by destruction of the globe, call for exenteration of the orbit (p. 91) with sacrifice of the eyeball even though it possesses useful vision.

Injuries of the Orbit include contusions, penetrating wounds, foreign bodies, and fracture of the bony walls. A prominent sign is *hemorrhage* into the orbit, causing *exophthalmos* and sometimes ecchymosis of the lids and conjunctiva. *Contusions* may rupture the globe or occasionally result in dislocation of the eyeball in front of the lids; such displacement is sometimes produced by gouging with the

thumb in insane patients. *Penetrating wounds* may destroy the eyeball, injure the optic nerve, causing blindness, or sever some of the muscles, resulting in paralysis and diplopia; if infected, such wounds are followed by orbital abscess. *Foreign bodies* may be tolerated if aseptic; if infected, suppuration ensues. *Fracture* may involve the anterior wall, or the inner wall causing emphysema, or the apex involving the optic canal and injuring the optic nerve; the last may result from direct injury or indirectly (contrecoup) and produce blindness without ophthalmoscopic evidence, followed in a few weeks by atrophy of the optic nerve.

Treatment consists in cleansing and disinfecting wounds and endeavoring to extract foreign bodies (with the aid of an *x*-ray examination). If the situation is such that extensive manipulation would be necessary for its removal, and we have reason to believe that the substance is aseptic (such as shot), it is often better to allow the foreign body to remain. Free exit for secretions must be maintained. A bandage aids in the absorption of blood and air.

Congenital Anomalies of the Eyeball are rare; they are usually bilateral. *Anophthalmos* is a small solid or cystic mass occupying the place of the eyeball. *Microphthalmos* consists of an eyeball of diminished size in all diameters. *Buphthalmos* (congenital glaucoma) is an increase in size of the eyeball with symptoms of glaucoma, usually resulting in blindness (p. 218).

OPERATIONS UPON THE EYEBALL

Enucleation of the Eyeball.—*The Instruments Required* are: (1) eye speculum (Fig. 353); (2) fixation forceps (Fig. 351); (3) toothed forceps (Fig. 352); (4) curved, blunt-pointed strabismus scissors (Fig. 356); (5) two squint hooks (Fig. 355); (6) strong, curved enucleation scissors (Fig. 106); (7) needle holder (Fig. 357); (8) fine, curved needle, thin black silk and fine catgut.

Operation.—A general anæsthetic is ordinarily given. After

introduction of the speculum, the conjunctiva is divided all around the cornea, as close to its border as possible, and dissected back as far as the insertions of the recti muscles. A squint hook is passed beneath the tendon of the internal rectus, and the latter is divided with the strabismus scissors close to its insertion; then all the other muscles are cut in the same way, together with the subconjunctival connective tissue for some distance beyond the equator. The points of the scissors must always be directed toward the eyeball and the latter stripped as clean as possible to avoid unnecessary removal of tissue. Instead of commencing with a circumcorneal division of the conjunctiva, we may begin with a tenotomy of the internal rectus and then divide the conjunctiva as we pass from tendon to tendon. The hook is passed around the globe to make sure that the attachments of the muscles have been completely divided. The eyeball is then dislocated forward by pressing the speculum backward, and thus the optic nerve is put on the stretch (Fig. 107). The enucleation scissors, closed, are passed between sclera and conjunctiva, feeling for the optic nerve; they are withdrawn a little, slightly opened, and the nerve is divided close to the sclera. The eyeball is then held between the thumb and index finger of the left hand, pulled forward, and all unsevered attachments divided. The socket is irrigated with bichloride solution, 1:5000, and hemorrhage arrested. The severed ends of the recti muscles should be sutured (internal and external rectus, superior and inferior rectus) to one another by means of

FIG. 106.—Enucleation Scissors.

fine catgut to prevent their retraction and thus give better movement to the stump. The conjunctiva is closed either with a single suture, which is passed through its edge at intervals and tied like the string of a pouch, or with five or more interrupted sutures. A wet or dry dressing is applied, a bandage, and the patient kept in bed for two days.

FIG. 107.—Enucleation of the Eyeball.

Care should be taken to avoid rupturing the eyeball, since a collapsed globe makes the operation more difficult. Troublesome hemorrhage may occur; it can be controlled by pressure. When an eyeball containing a malignant growth is enucleated, as much of the optic nerve as possible should be removed. Very rarely, infection of the wound has led to abscess, thrombosis, and even fatal meningitis. The tendency to meningitis is somewhat increased in enucleation of an actively suppurating eyeball; hence most oculists consider panophthalmitis a contraindication to enucleation, and postpone this operation until after the suppurative process has ceased.

The Indications for Enucleation are: (1) Injuries of the eyeball, especially those involving the ciliary region, when the eye is blind, or the traumatism so extensive that the form of the eyeball cannot be preserved; (2) traumatic iridocyclitis, to prevent sympathetic ophthalmitis; (3) severe pain in a blind eye which cannot be relieved by less radical means; (4) iridocyclitis, phthisis bulbi, and glaucoma, when accompanied by severe pain or inflammatory symptoms, and when the eye is blind or is certain to become so; (5) malignant

tumors, either intraocular or epiocular (excepting small tumors of the iris which can be entirely removed by iridectomy); (6) anterior staphyloma, if the eye is blind, troublesome, and disfiguring; (7) panophthalmitis after the suppurative process has ceased; (8) foreign bodies in the eye when they cannot be removed and cause irritation; (9) cosmetic improvement in blind and disfiguring eyes.

Enucleation with Insertion of an Artificial Globe.—After enucleation, as just described, Tenon's capsule is filled with a glass, gold, or paraffin sphere, or with a piece of fat exsected from any convenient part of the body. The tendons of the recti muscles, the margins of Tenon's capsule, and the conjunctiva are then successively sutured. This method is intended to improve the cosmetic effect; when fat is used, this result is accomplished with very little increase in the reaction which follows ordinary enucleation.

Evisceration of the Eyeball.—In this operation the cornea and entire contents of the eyeball are removed, the sclera alone remaining.

The Instruments Required are: (1) eye speculum (Fig. 353); (2) fixation forceps (Fig. 351); (3) curved strabismus scissors (Fig. 356); (4) Graefe knife (Fig. 194) or Beer's knife (Fig. 58); (5) sharp curette; (6) needle holder (Fig. 357); (7) small curved needles, catgut and silk sutures.

Operation.—After insertion of the speculum the eye is transfixed just behind the cornea with a Graefe or Beer's knife, which is made to cut its way out at the upper sclerocorneal junction; the other half of the cornea is separated with the scissors. The contents of the eyeball are then removed thoroughly with a sharp spoon, care being taken that nothing but sclera is left. The cavity is irrigated, wiped out, and hemorrhage arrested. The scleral edges are brought together in a vertical line with catgut sutures, and the conjunctiva is united horizontally with silk sutures.

Recovery is less rapid than after enucleation, and the pain and reaction are greater; the support for an artificial eye

is usually better. The operation may be substituted for enucleation after panophthalmitis, but is contraindicated in malignant tumors, foreign bodies, shrunken eyeballs, and sympathetic ophthalmitis.

Evisceration with Insertion of an Artificial Vitreous (Mules' Operation).—Following evisceration, after the scleral cavity has been cleansed and hemorrhage checked, a hollow sphere of glass (silver, gold, platinum, paraffin) is introduced. This ball must not be too large; its introduction is facilitated by slitting the sclera and by the use of a special inserting instrument. The wound is then closed and dressed as after the ordinary evisceration. There is considerable reaction after this operation; this may require cold compresses. The patient is confined to bed for several days or a week. The stump is undoubtedly superior to that furnished by any other method, but it sometimes happens that the ball is extruded; sympathetic ophthalmitis has followed this operation in rare instances.

Artificial Eyes (Fig. 108) are worn after enucleation and evisceration, for cosmetic purposes, and to fill out the cavity

FIG. 108.—Artificial Eyes. *a*, Outer Surface; *b*, Inner Surface; *c*, Section of Shell Eye; *d*, Section of Snellen ("Reform") Eye.

left between the lids. They can be worn as soon as the socket is free from inflammation, usually after several weeks. The artificial eye should be washed frequently, and must be removed every night. After a year its surfaces and edges become roughened, and it must be replaced by a new one. When there is a stump of good size, a shell-shaped artificial

eye may be indicated; but with a small stump or after enucleation, the more modern Snellen " reform " artificial eye gives better cosmetic effect; the latter has a certain thickness and is hollow.

Exenteration of the Orbit is a radical operation resorted to in certain cases of malignant disease. The periosteum and all the contents of the orbit, including the eyeball, are removed.

Krönlein's Operation consists of a temporary loosening and displacement of the external wall of the orbit for the purpose of exploration and the removal of deep-seated tumors.

CHAPTER VII

DISEASES OF THE CONJUNCTIVA

Anatomy.—The conjunctiva is a thin layer of mucous membrane which lines the eyelids and is reflected on to the eyeball, forming a sac, the *conjunctival sac* (Fig. 182). We distinguish three divisions: (1) The *palpebral* conjunctiva, covering the under surface of the lids; (2) the *ocular or bulbar* conjunctiva, coating the anterior portion of the eyeball; and (3) the *fornix*, the transition portion, forming a fold between lid and globe. The conjunctiva differs somewhat in structure in each of these portions.

The palpebral conjunctiva is thicker than the other portions. In the greater part of its extent it is closely adherent to the subjacent tarsus, allowing the Meibomian glands to show through. Its surface is smooth, but presents a number of minute projections, or *papillæ*. It is covered with cylindrical epithelium. Its stroma is of an adenoid character, containing a large number of lymph corpuscles, which may in some cases be collected into small rounded masses (lymphoid follicles). It is a disputed question, however, whether these are normal or are the result of pathological processes. Numerous mucous glands are also found.

The conjunctiva of the fornix is similar in structure to that of the lids. It constitutes a very loose fold (*retrotarsal fold*), insuring great freedom of movement to the eyeball. It is richly supplied with blood-vessels. This and its lax condition explain its liability to marked swelling in inflammations of the conjunctiva. It has opening into it the lacrymal ducts and numerous mucous glands.

The bulbar conjunctiva, thin and transparent, covers the anterior surface of the eyeball, being loosely attached to the sclera by connective tissue (*episcleral tissue*), with the exception of the margin representing the boundary between cornea and sclera (*limbus*), where it is firmly adherent. In structure it resembles the rest of the conjunctiva but contains no glands. It is covered with laminated pavement epithelium which is continued uninterruptedly over the cornea and constitutes its outer layer. Near the inner canthus it forms a crescentic fold (plica semilunaris), the rudiment of the nictitating membrane or third eyelid of the lower animals.

The vascular supply of the conjunctiva is derived from the blood-vessels of the fornix—the *posterior conjunctival* (derived from the palpe-

bral) and from the *anterior ciliary*. The latter pass forward along the recti muscles and pierce the sclera near the limbus to reach the interior of the eye, giving off one set of branches which form *vascular loops* surrounding the cornea and supplying it with nourishment, and another set (*anterior conjunctival*), which pass backward in the conjunctiva and anastomose with the posterior conjunctival. This arrangement, together with the posterior ciliary arteries and the retinal system of vessels, constitutes the entire vascular system of the eye. Thus the bulbar conjunctiva presents *two vascular systems*—the posterior conjunctival and the anterior ciliary. The nature of the injection in any given case is of some value in locating the seat of the congestion.

The *nerves* of the conjunctiva, branches of the fifth, terminate in end-bulbs, and are especially abundant in the palpebral portion. *Lymphatic vessels* are found in considerable numbers.

Pinguecula is a small, slightly raised *spot of yellowish color* situated to the inner and outer sides of the cornea where the conjunctiva is most exposed to wind, dust, etc., especially marked in *old people* and most conspicuous when the conjunctiva is reddened. It is not formed of fat as its name implies, but of thickening of the conjunctiva due to excessive development of yellow elastic tissue and the deposit of hyaline substance. It never calls for interference.

Conjunctival and Ciliary Injection.—The differences between conjunctival and ciliary or circumcorneal injection (Plate VII) are as follows:

Conjunctival Injection.	Ciliary Injection.
1. Derived from posterior conjunctival vessels.	1. Derived from anterior ciliary vessels.
2. Accompanies diseases of the conjunctiva.	2. Accompanies diseases of the cornea, iris, and ciliary body.
3. More or less muco-purulent or purulent discharge.	3. Often lacrymation, but no conjunctival discharge.
4. Most marked in fornix conjunctivæ.	4. Most marked immediately around the cornea; hence called "circumcorneal."
5. Fades as it approaches the cornea.	5. Fades toward the fornix.
6. Bright, brick-red color.	6. Pink or lilac color.
7. Composed of a network of	7. Composed of small, straight

coarse, tortuous vessels, anastomosing freely, and placed superficially, so that the meshes are easily recognized.	vessels, placed deeply, so that the individual vessels cannot be recognized easily, but are seen indistinctly as fine, straight lines radiating from the cornea.
8. Can be moved with the conjunctiva by pressure on lower lid.	8. Cannot be displaced by movement of the conjunctiva.

In severe forms of diseases of the anterior part of the eye these two types of congestion are often found *associated,* as we would expect when we remember that the two systems of vessels anastomose freely.

When very pronounced, particularly when there is much venous congestion, ciliary injection assumes a *violet* color. A form of injection of this sort involves the *episcleral* tissue between the equator of the eyeball and the cornea, presenting a deeply placed, violet-colored patch seen in scleritis and glaucoma (Fig. 111, Plate VII).

Subconjunctival Hemorrhage results in bright or dark red patches, of greater or lesser size, involving more or less of the bulbar conjunctiva (Fig. 112, Plate VII), unaccompanied by inflammatory symptoms. This condition (*ecchymosis*) is often seen after injuries, operations, and inflammations of the eyeball. It is frequently observed in old persons with brittle blood-vessels, being excited by various straining efforts, such as sneezing, and in children after whooping-cough. Sometimes the hemorrhage occurs without any exciting cause, the subject being unaware of its existence until he notices the discoloration. The hemorrhage itself is of *no importance* and the blood becomes *absorbed* within a week or two; the disappearance of the discoloration can, however, be hastened by gentle massage of the affected area with the finger over the lid, using a 1-per-cent. ointment of ammoniated mercury and following this with hot, moist compresses for ten minutes at a time.

Hyperæmia of the Conjunctiva (*Dry Catarrh*) is a very common condition which manifests itself in a congestion

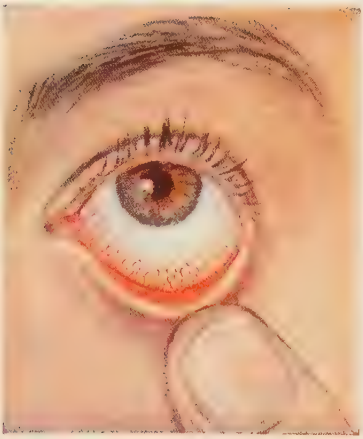

FIG. 109.—Conjunctival Injection.

FIG. 110.—Circumcorneal (Ciliary) Injection.

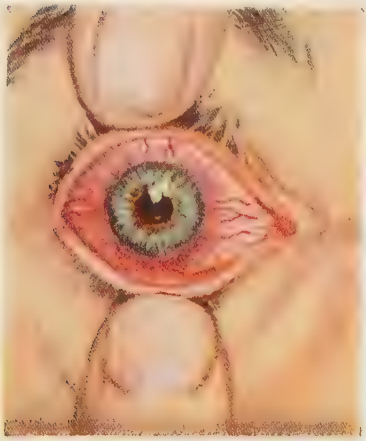

FIG. 111.—Ciliary and Episcleral Injection.

FIG. 112.—Subconjunctival Hemorrhage.

Figs. 109-112.—Types of Conjunctival and Ciliary Congestion. Subconjunctival Hemorrhage.

affecting chiefly the palpebral portion of the conjunctiva. It may be only a *transitory* condition or it may exist in *chronic* form, in which case it is often merely the first stage of chronic catarrhal conjunctivitis.

Etiology —The transitory form is often caused by local *irritants* such as foreign bodies, dust, wind, smoke, exposure to bright light or to glare, such as exists at the seashore or on the water, or it accompanies acute coryza and hay fever. The chronic form is frequently the result of uncorrected *errors of refraction* or the use of *faulty glasses*, misplaced lashes, vitiated or smoky atmosphere, *alcoholism*, overuse or *abuse of the eyes* especially with insufficient illumination, or it accompanies nasal catarrh, blepharitis, and lacrymal obstruction. A recurrent form has been attributed to gout.

Symptoms.—There is *congestion* of the palpebral conjunctiva with slight swelling and roughness and little or no discharge. The patient complains of a dry, hot, gritty, *smarting sensation*, the eyes feel *tired*, water easily, and are *uncomfortable* when exposed to light, and the lids feel *heavy*. These symptoms are most pronounced with near use of the eyes, especially with artificial illumination.

Treatment consists of *removal of the exciting cause*, especially the correction of errors of refraction. Irrigation with solution of *boric acid*, *alkaline solution* (p. 396) and *cold* compresses will relieve the discomfort. The use of a one-half-of-one-per-cent. solution of holocaine in 1: 10000 adrenalin may be permitted occasionally; but though very grateful, the continuous use of the latter remedies is objectionable.

CONJUNCTIVITIS

Inflammations of the conjunctiva are known as *conjunctivitis* or *ophthalmia*.

The *varieties* are:

1. Catarrhal: (a) acute, (b) chronic, (c) follicular.
2. Purulent: (a) ophthalmia neonatorum, (b) gonorrhoeal.

3. Membranous: (a) diphtheritic, (b) non-diphtheritic or croupous.
4. Granular or trachoma.
5. Phlyctenular.

ACUTE CATARRHAL CONJUNCTIVITIS

This is an acute catarrhal inflammation of the conjunctiva accompanied by *mucoid or muco-purulent discharge.* It is also known as acute muco-purulent and *acute simple conjunctivitis.*

Objective Symptoms.—The palpebral conjunctiva and that of the fornix are of a brilliant *red* color and are *swollen* (Fig. 121, Plate IX). There is usually but slight congestion of the bulbar conjunctiva; but in severe cases this may become marked, and there may be added œdema of the bulbar conjunctiva (chemosis, Fig. 119), small conjunctival hemorrhages, and œdema of the lids. The *secretion,* which is *increased* in amount and *altered* in character, varies according to the severity of the affection. In mild cases, it is at first *watery* with some flakes of mucus, later *mucoid;* in severer forms, it is *muco-purulent;* in very marked examples, the amount of pus may be so considerable that the character of the discharge, together with the severity of the objective signs, may leave us in doubt for twenty-four hours whether the disease is not the beginning of a purulent inflammation and may prompt us to make a microscopic examination of a smear of the discharge. The secretion accumulates during the night and dries upon the edges of the lids during sleep.

Subjective Symptoms.—There are *itching* and *smarting* sensations referred to the lids; the latter feel hot, heavy, and as though sand or a foreign body were underneath. There is more or less photophobia. There may be some blurring of sight when the altered secretion lies upon the cornea. The symptoms are usually worse toward evening; they vary in severity with the degree of inflammation. The affection may be limited to one eye, but usually *both eyes* are implicated, either from the start or after two or three days.

Course.—Most patients get well in a *few days*, or in a week or two. Sometimes the acute symptoms subside and a subacute or chronic catarrhal conjunctivitis remains. Blepharitis may be present. In severe cases small, grayish infiltrations (catarrhal ulcers) may form at the corneal margin. The coalescence of a number of these may cause a marginal ulcer, which is usually unimportant, superficial, and heals readily, but occasionally becomes deep and serious. Rarely iritis occurs as a complication.

Etiology.—The disease occurs at *all ages* and at all times during the year, but is most common in the spring and autumn. The causes may be divided into:

1. *Mechanical*—foreign bodies, exposure to wind and dust (automobiling), smoke, etc.

2. *Epidemic*—in spring and autumn, depending upon the presence of certain micro-organisms—usually the Koch-Weeks bacillus or the pneumococcus.

3. *Infection*—through contact with fingers, towels, handkerchiefs, etc., of patients suffering from the disease. The discharge is *contagious*, especially when it is abundant and when it contains much pus; hence the affection often presents a number of examples in the same household or school.

4. *Exanthemata*, accompanying or following measles, less frequently scarlatina and smallpox.

5. *Associated* with coryza, rose cold, hay fever, and grippe.

Clinical Varieties.—Certain forms of this disease are distinguished by qualifying adjectives, indicating the etiology.

Traumatic Conjunctivitis is the name given to acute catarrhal conjunctivitis when excited by the presence of a *foreign body* or by *traumatism*. Under this head may be included the forms of conjunctivitis due to *intense light* (*photophthalmia*), for example the electric arc light or that used in electric welding (*electric ophthalmia*), and that produced by reflection from snow (*snow blindness*). In the cases due to intense light, there are symptoms of conjunctivitis, and, in addition, marked photophobia, lacrymation, intense smarting of the

lids, contraction of the pupil, and sometimes œdema of the lids and superficial ulceration of the cornea.

Lacrymal Conjunctivitis accompanies dacryocystitis; it is generally limited to the inner third of the palpebral and ocular conjunctiva; it is caused by infection from the secretion of the diseased lacrymal sac containing streptococci (Fig. 117, Plate VIII).

Exanthematous Conjunctivitis is the name given to that variety which is associated with the exanthemata; this form is most commonly seen in measles.

Acute Epidemic Conjunctivitis (acute contagious conjunctivitis), popularly known as *"pink eye,"* is a very *contagious* form of acute catarrhal conjunctivitis occurring most often in spring and autumn, presenting *marked symptoms* and *profuse discharge* and excited by the Koch-Weeks bacillus or the pneumococcus (Plate VIII). This is the variety which not infrequently gives rise to such severe objective symptoms including swelling and redness of the lids and copious discharge, that one may be in doubt whether the affection is an example of the catarrhal or of the purulent form of conjunctivitis. It is advisable, when first called to treat severe cases of this sort, to examine a smear of the conjunctival secretion under the microscope, and to decide definitely upon the nature of the infection only after the responsible organism has been identified.

Other Clinical Varieties of acute catarrhal conjunctivitis have been classified according to other *micro-organisms* than those mentioned above, which seem responsible. One form, which attacks chiefly young children and infants, is due to the *influenza bacillus*. *The micrococcus catarrhalis* occurs in some cases. Staphylococci are present to a greater or lesser extent in all forms of conjunctivitis.

Attempts have been made to base the classification of conjunctivitis upon the findings of bacteriological examination of the secretion. But up to the present time no system of nomenclature of this sort has been found practical, since

PLATE VIII

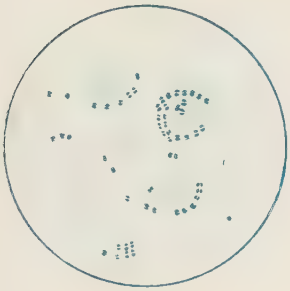

FIG. 113.—Gonococcus.

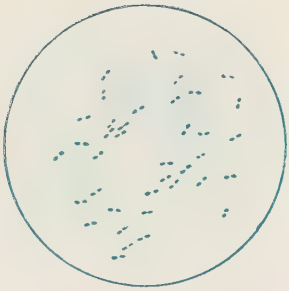

FIG. 114.—Pneumococcus.



FIG. 115.—Koch-Weeks Bacillus.

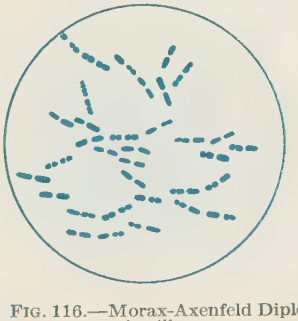

FIG. 116.—Morax-Axenfeld Diplobacillus.



FIG. 117.—Streptococcus.

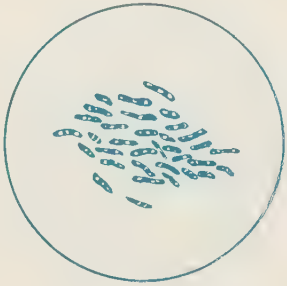

FIG. 118.—Diphtheria Bacillus.

Figs. 113-118. Micro-Organisms Found in Various Forms of Conjunctival, Corneal, and Lacrymal Disease. (Zeiss $\frac{1}{12}$ Im., Oc. 4 = 950 ×.)

mixed infections are encountered so frequently and in only a few varieties of conjunctivitis have the pathogenic micro-organisms been isolated. The normal conjunctival sac is never free from micro-organisms; staphylococci, the xerosis bacillus, and diplococci, morphologically identical with pneumococci, are practically always present.

Follicular Conjunctivitis is considered by some authorities as a variety of *catarrhal conjunctivis*, by others as a form or stage of *trachoma*. It will be described separately.

Treatment.—Though the disease tends to get well without interference, treatment reduces the duration, adds to the patient's comfort, and prevents the change into subacute or chronic conjunctivitis. *Iced compresses* should be applied for from fifteen minutes to an hour, three times a day. The conjunctival sac should be *irrigated* several times a day with solution of *boric acid* or the *alkaline solution* described on p. 396. A small quantity of *bichloride ointment* (1:3000) placed in the conjunctival sac three times a day is of great benefit; used just before retiring, this ointment prevents the edges of the lids from becoming glued together during sleep. A very common remedy is 25-per-cent. solution of *argyrol* or 5-per-cent. solution of protargol, instilled several times a day, as long as the discharge is abundant; with these remedies the best procedure is to instil a few drops of either solution, allow these to remain in the conjunctival cul-de-sac with closed lids for five minutes, and then to irrigate thoroughly with either solution of boric acid or the alkaline solution.

It is important to caution the patient concerning the *contagiousness* of the discharge.

If the disease shows a tendency to become obstinate or chronic, instillations of a one-grain-to-the-ounce solution of *zinc sulphate* twice a day are indicated; often an occasional and very light application of the stick of alum or *copper sulphate* to the everted conjunctiva, followed immediately by abundant flushing with boric acid solution, will hasten the return of the conjunctiva to a normal state.

CHRONIC CATARRHAL CONJUNCTIVITIS

A chronic catarrhal inflammation of the conjunctiva, presenting somewhat similar symptoms to those found in the acute form, but associated with only *slight changes* in the quantity and quality of the normal secretion. It is also known as *chronic simple conjunctivitis.*

Objective Symptoms.—The conjunctiva of the lids is *reddened* and smooth; in old cases it may be *hypertrophied* and *velvety.* The *secretion* is usually but slightly altered, and there is very little increase; there may be enough to glue the eyelids in the morning or to present some dried secretion at the inner canthus; in some cases there is less than the normal amount of secretion. There is apt to be some *excoriation* at the outer angle.

Subjective Symptoms are the same in kind as in the acute form: *Itching,* burning, and *smarting* sensations; a feeling of dryness; an annoyance as though there were a foreign body in the eye; *heavy, sleepy feeling* in lids which the patient may have some difficulty in keeping open, especially at night; some sensitiveness to light; the eyes water and tire easily. These symptoms are *worse at night.*

Course.—The disease is probably the most *common* of ocular affections. It usually occurs in *adults,* and frequently in old persons. It is apt to be of *lengthy* duration, lasting some months and even years.

Complications.—*Blepharitis* is frequently present. Eczema of the lower lid, and eversion of the inferior punctum producing epiphora are not uncommon; sometimes ectropion and corneal ulceration.

Etiology.—It may be the sequel of acute catarrh. It may be caused by improper hygienic *surroundings,* vitiated atmosphere (overcrowding), *irritating atmosphere* (smoke, dust), continuous exposure to wind, insufficient sleep, late hours, alcoholic excesses, exposure of the conjunctiva in ectropion, *eye-strain,* overuse, local irritation such as trichiasis, chronic

dacryocystitis, etc. It is usually *bilateral;* when due to local irritants it may be unilateral.

Treatment.—We must endeavor to *remove the cause* of the inflammation. *Locally: Astringent* solutions (*zinc,* borax, alum, tannic acid, silver nitrate gr. $^1/_{10}$ or $^1/_5$ to ℥ i.); ointments of the yellow oxide and ammoniated *mercury; silver nitrate,* 1 per cent., brushed on the everted lids once a week; the occasional application of the alum or *sulphate-of-copper* stick; bland ointments to the edges of the lids at night to prevent adhesion and excoriation. As in all chronic catarrhal affections, the remedies must be changed from time to time.

Diplobacillus Conjunctivitis, a variety of chronic catarrhal conjunctivitis caused by the bacillus of *Morax-Axenfeld* (Fig. 116, Plate VIII), is *subacute or chronic* and often tedious in its course and usually occurs in adults. There is moderate redness and swelling of the palpebral conjunctiva and the lid margins, especially at the *angles,* on which account the affection has been called *Angular Conjunctivitis.* The symptoms include *smarting and itching* and a feeling of foreign body in the eye; there is slight, grayish, tenacious *discharge,* which is found gluing the lashes together upon awakening. Instillations of *zinc sulphate* (0.2 to 0.4 per cent.) or zinc chloride (0.2 per cent.) act as a specific in this form of conjunctivitis.

FOLLICULAR CONJUNCTIVITIS

This disease, also known as *Follicular Catarrh,* is characterized by the occurrence of "*follicles,*" *with or without the symptoms of catarrhal conjunctivitis* (Fig. 123, Plate IX).

Objective Symptoms.—The conjunctiva of the *lower retrotarsal fold* (less commonly also the upper fornix) presents a variable number of small, round or oval, pinkish, translucent bodies, each about the size of a pin-head; when abundant they are arranged in rows. These follicles consist of circumscribed aggregations of lymphocytes (*adenoid tissue*) identical

in structure with the granulations of trachoma; on this account follicular catarrh is sometimes looked upon as an early stage of trachoma. But this is regarded as unlikely by most authorities since there is neither papillary hypertrophy, cicatricial changes nor other sequelæ, no evidence of contagiousness, and the affection subsides without leaving any traces.

The disease presents *three clinical types:* (1) The presence of follicles accompanied by the signs of *acute catarrhal conjunctivitis;* (2) the addition of follicles to the objective signs of *chronic catarrhal conjunctivitis;* and (3) the existence of follicles without any other changes in the conjunctiva—a very frequent form to which the name *folliculosis of the conjunctiva* is sometimes given.

Subjective Symptoms vary with the type of disease; they are identical with *those of catarrhal conjunctivitis* in those varieties which are accompanied by inflammatory manifestations. In the form known as folliculosis there will be slight itching, very moderate sensitiveness to light, and some complaint of the eyes tiring easily; in many cases patients do not complain of any symptoms whatever, and the existence of the granulations is discovered accidentally.

Course.—The disease may be *acute* but is much more frequently *chronic;* in either case the course is *obstinate;* in chronic cases the follicles may persist for months and even years. It is sometimes difficult, in acute cases, to differentiate between follicular catarrh and granular conjunctivitis, and we may have to await the results of several weeks' treatment in order to decide definitely. At the end of this period, however, it will be possible to decide, since in follicular conjunctivitis the follicles disappear after a time, leaving the conjunctiva in a natural condition, they affect principally the lower lid, and there are neither corneal nor other complications or sequelæ.

Etiology.—It occurs most frequently in *children* and in young persons, and is often found in schools, asylums, and other places where there is overcrowding. *Poor hygienic sur-*

roundings, especially indoor life, anæmia, and errors of refraction are predisposing factors. The various causes of catarrhal conjunctivitis act as exciting agents.

Treatment.—The same as that given for acute and chronic catarrhal *conjunctivitis*, when inflammatory manifestations are present. It is of special importance to correct any interference with the general health and to place such children under the *best hygienic surroundings*. Locally, irrigations with *boric-acid* solution and the ointment of the *yellow oxide of mercury;* the occasional use of 1-per-cent. solution of nitrate of *silver* or of the sulphate-of-*copper* stick may be of service. When the patient no longer complains of any symptoms and the follicles persist, they may be allowed to remain and treatment discontinued.

Purulent Conjunctivitis is an *acute* purulent inflammation usually due to *contagion from gonorrhœal virus*. The infecting elements are the *gonococci* (Neisser); they are found in the pus cells and conjunctival epithelium, and are arranged in pairs (diplococci) and generally in colonies (Fig. 113, Plate VIII). The disease is also known as *acute blennorrhœa of the conjunctiva*.

Clinical Varieties: (1) *Adult* Purulent Conjunctivitis or Gonorrhœal Ophthalmia or Conjunctivitis. (2) *Infantile* Purulent Conjunctivitis or Ophthalmia Neonatorum (occurring in the new-born).

GONORRHŒAL OPHTHALMIA, OR ADULT PURULENT CONJUNCTIVITIS

Symptoms.—First Stage, *Infiltration.*—After a period of incubation varying from twelve hours to two days (short in severe cases), there occur great *swelling, redness, and tenseness of the lids*, so that the latter cannot be opened voluntarily and can be separated only with difficulty. The *conjunctiva* of the lids and fornix is intensely *swollen* and *reddened*, uneven, and in severe cases it may be covered with a membranous deposit; there is *chemosis* (œdema of the ocular conjunctiva [Fig. 119],

causing it to swell up around the cornea) and infiltration. The *secretion* is at first *serous*, somewhat colored with blood, and containing a little pus. The eye is tender to touch. The patient complains of a hot, smarting *pain* in the eye and a dull aching in the brow and temple. As a rule only *one eye* is affected. There are some constitutional disturbance, slight fever, and some swelling of the preauricular gland. This stage lasts about two days and is followed by the

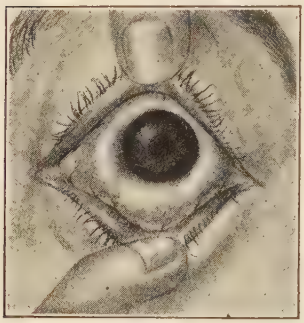

FIG. 119.—Chemosis of the Conjunctiva.

Second Stage, *Purulent Discharge.*—The *swelling* of the lids and conjunctiva and the chemosis *diminish* and the eye becomes less tender. A very *profuse purulent discharge* appears and escapes continually from between the lids. This condition continues for two or three weeks, all symptoms gradually diminishing.

Third Stage, *Convalescence or Papillary Swelling.*—The eye may return to a *normal* condition in two or three weeks. More frequently, however, there is a stage of *papillary swelling*, a chronic inflammation of the lids; the palpebral and retrotarsal conjunctiva remaining thickened and red and presenting, especially over the tarsus, an uneven granular or velvety appearance, with hyperæmia of the ocular conjunctiva, lasting several weeks.

Course.—The disease is always a *serious* one, but exhibits various degrees of severity. Cases in which there is slight infection, or in which the disease has been contracted from a chronic gonorrhœa (gleet) are the mildest. The very intense cases have probably been acquired through contagion from the secretion of a very virulent gonorrhœa, and especially from contamination during the early stages.

Etiology.—The disease is always acquired through infection from *gonorrhœal secretion*, either *directly*, the fingers of the patient transferring the virus from the genitals, or *indirectly* by means of contaminated towels, etc.

Complications.—A very frequent and important complication is *corneal ulceration*. This begins with a circumscribed grayish infiltration, becoming yellow and breaking down, so that *ulcers* are formed. The ulcers vary in situation, size, and course. They may be central or marginal; the latter may be confluent, so as to form an annular ulcer. The ulcers may *perforate* and this be followed by cicatrization with or without incarceration of the iris, staphyloma, and other sequelæ of corneal ulceration. Panophthalmitis may result. Severe and early involvement of the cornea is most common in intense attacks; in such cases, *serious* and permanent damage or *loss* of the eye is very common.

Prognosis depends upon the severity of the case, and upon the behavior of the *cornea*. It is always *grave*.

Treatment.—*Prophylactic:* Great precautions must be observed to *prevent infection* of the eyes of the physician, nurse, and attendants through spurting of the discharge during examination or treatment; *protecting glasses* should be worn whenever exposed to this risk. Contaminated fingers must be carefully *disinfected*. Materials which have been used for cleansing the eye must be *burned*.

The non-affected eye should be protected from infection by the application of *Buller's shield* (Fig. 120). This consists of a watch glass, securely held in place by adhesive plaster applied to the side of the nose, the cheek, and forehead. The junction of skin and plaster is sealed by a layer of collodion. The centre of the glass is left uncov-



FIG. 120.—Buller's Shield.

ered by plaster to permit inspection of the eye, and a small part of the outer margin of the covering is left free for ventilation and to prevent the deposit of moisture upon the watch glass. The patient is not allowed to lie upon the non-affected side so that no pus will flow across the nose.

Treatment of the First Stage: Iced compresses are used more or less continuously, day and night. The eye must be carefully *cleansed* and the *secretion removed* as rapidly as it forms. When very abundant, this will be necessary every quarter or half an hour. For this purpose a saturated solution of *boric acid* is most frequently employed, being allowed to trickle in between the lids from a piece of absorbent cotton dripping with the remedy, or poured in from an undine (Fig. 367); then the secretion which has been washed out is gently wiped off from the margins of the lids.

The iced compresses may be used continuously at first if grateful to the patient. But when the tense, reddened, and swollen condition of the lids becomes less marked the *application of cold must be reduced* to every other hour, or every third hour; too much refrigeration interferes with the nutrition of the cornea. When the cornea is involved, we must carefully gauge the amount of cold so as not to use an excess. In the *later stages*, when there is little swelling, and corneal infiltration or ulceration exists, *hot applications* may be used in order to improve nutrition by stimulating the flow of blood to the part. Atropine should be instilled.

Instead of boric acid, other cleansing and antiseptic solutions are often used: Mercuric bichloride (1:6000, or 1:10,000), sodium chloride (0.75 per cent.), sterilized water, permanganate of potassium (1:500).

During the stage of purulent discharge, a few drops of 25-per-cent. *argyrol* or 10-per-cent. *protargol* should be instilled every hour; in addition, a 1-per-cent. solution of *silver nitrate* may be brushed upon the everted conjunctiva once daily; this may be done even though the cornea be implicated.

In the initial stage, if the disease be very severe, from three to six *leeches*, applied to the corresponding temple, may be of service. Occasionally there is so much *tension* that the eye cannot be cleansed on account of the difficulty in separating the lids, and in addition harmful pressure is exerted upon the eyeball; in such cases it may become necessary to widen the palpebral fissure by a division of the external canthus (*canthotomy*, p. 53). It may also be advisable to *scarify* the ocular conjunctiva if the chemosis and infiltration are extreme and likely to have an injurious effect upon the cornea.

All manipulations must be *most gentle* so as to avoid injury to the cornea or perforation when an ulcer is present.

Treatment of the Later Stages: The applications of *silver nitrate* should be continued until the patient is well, or until the papillary swelling has persisted for some time. Then, if silver no longer exerts a favorable influence, we may apply glycerole of *tannin* (5 to 10 per cent.), the *alum* stick, or *sulphate-of-copper* pencil once a day.

The treatment of corneal complications resembles that of infected corneal ulcers, and is described in the next chapter.

Metastatic Gonorrhœal Conjunctivitis is an uncommon form of inflammation of the conjunctiva excited by the presence of gonorrhœal virus in the circulation and, like arthritis and iritis, is a complication of gonorrhœa. The symptoms resemble those of catarrhal conjunctivitis of moderate severity, consisting of some swelling and redness of the lids and conjunctiva, a little pain, and limited discharge which is free from gonococci. The affection is usually bilateral, runs its course in two or three weeks, and yields to the ordinary treatment of conjunctivitis (together with iodides internally), as a rule without complications, and never with sequelæ.

OPHTHALMIA NEONATORUM OR INFANTILE PURULENT CONJUNCTIVITIS

An *acute purulent conjunctivitis occurring in the new-born*, presenting similar symptoms, complications, and course, and

requiring the same treatment as in the gonorrhœal ophthalmia of adults.

Symptoms.—The period of incubation being the same as in adults, the first symptoms are usually noticed on the *second or third day* after birth; when the onset is later than the fourth day, infection has taken place subsequent to birth.

The symptoms (Fig. 122, Plate IX) are the *same in kind as in the adult form*, very often less severe, and more apt to be limited to the palpebral and retrotarsal conjunctiva, hence chemosis is slight. *Both eyes* are usually involved, but the disease is monolateral in about one-fifth. The *cornea* is implicated much less frequently, especially if the affection is treated from the start. If seen early, before the cornea is affected, and properly managed, this part very often escapes destruction or damage.

Prognosis, therefore, *with early and proper treatment, is generally favorable.*

Etiology.—*Infection* from vaginitis of the mother *during parturition.* In rare cases, infection occurs before birth. Sometimes it occurs *after* the birth of the child, through infection from sponges, napkins, towels or fingers of the nurse, which have been in contact with the genitals of the mother.

Two-thirds of all cases of ophthalmia neonatorum are produced by infection from a *gonorrhœal vaginitis;* one-third are the result of infection from simple *catarrhal vaginitis.* In these non-gonorrhœal cases, gonococci are absent in the conjunctival discharge, though the pneumococcus, bacterium coli, and other germs are found; such forms occur later, run a mild course, and are not usually complicated by corneal ulcers.

Treatment is similar to that employed in adult purulent conjunctivitis: *Iced compresses*, frequent *cleansing*, and instillations of *argyrol* 25 per cent., or *protargol* 10 per cent., from the start. As soon as the discharge becomes purulent, daily applications of 1-per-cent. solution of *silver nitrate* continued throughout the stage of papillary swelling; canthotomy may be necessary; atropine should be instilled.

In applying the *iced pads*, we must be careful *not* to use them *too continuously*, as soon as the redness and swelling begin to diminish. In adults, the sensations of the patient guide us to a certain extent, and we use the pads less often when they no longer feel grateful, as happens when the redness and swelling subside. In infants, we cannot receive this information; hence great care must be used not to injure the cornea by excessive cooling, especially if there is corneal infiltration; in such cases, *hot compresses* are often substituted for the cold.

The general health of the infant must be looked after, since enfeebled conditions render treatment unsatisfactory and favor corneal complications.

In the monolateral cases, the child should be *kept lying on the affected side* so as to favor limitation of the disease to the involved eye, since it is not practicable to seal the healthy eye with a Buller's shield or otherwise.

Credé's Method of Prophylaxis.—*Ophthalmia neonatorum is preventable.* Credé's method has made it infrequent in lying-in asylums and in private practice whenever employed. The method consists in *cleansing* the lids immediately after birth, and instilling one drop of a *2-per-cent. solution of nitrate of silver*, thus destroying any gonococci which may have entered the conjunctival sac. This often causes a slight redness of the conjunctiva for a day or two. A 1-per-cent. solution of silver nitrate may be substituted, but 25-per-cent. argyrol or 10-per-cent. protargol, though often used, are not so reliable for this purpose. Antiseptic irrigation of the vagina of the mother before delivery is also useful as an additional prophylactic measure.

As a result of Credé's method of prophylaxis, greater attention to the eyes of the new-born, education in this subject, regulation and control of midwives and improved management, the proportion of total blindness which twenty-five years ago amounted to 30 per cent. from ophthalmia neonatorum has been reduced to 10 per cent.; such results, though

showing improvement, can be excelled, because blindness from this disease is *absolutely preventable.*

Purulent Conjunctivitis of Young Girls.—This disease is sometimes met with in young girls in whom the conjunctiva has been infected, directly or indirectly, through an existing vaginal discharge. The secretion may contain gonococci or be free from these. The symptoms resemble those of ophthalmia neonatorum but are much less severe, with less tendency to involvement of the cornea. The prognosis is good if the usual treatment for purulent conjunctivitis be properly carried out.

Catarrhal Conjunctivitis in the New-Born.—Sometimes we meet with a slight catarrhal conjunctivitis in the new-born, lasting a few days and presenting merely hyperæmia, slight swelling, and a little mucoid discharge. These are not examples of ophthalmia neonatorum. But at the start we may be in doubt whether they are not purulent cases, and it will be safer to treat them as such until the character of the inflammation becomes certain. In such cases, bacteriological examination of the conjunctival discharge is a great aid.

Membranous Conjunctivitis.—This term comprises two clinical varieties: 1. *Diphtheritic* Conjunctivitis, and 2. *Croupous* Conjunctivitis. This subdivision is based upon the clinical pictures presented. The bacteriological findings in the exudation may be, and often are, identical.

DIPHTHERITIC CONJUNCTIVITIS

An *acute* inflammation of the conjunctiva, associated with exudation and *infiltration*, purulent discharge, with tendency to *necrosis* of the involved tissues. The disease is rather rare and occurs in *children*. It spreads by *infection*. The secretion contains the Klebs-Loeffler bacillus (Fig. 118, Plate VIII) and other micro-organisms and is *contagious*.

Symptoms. –The *lids* are very much *swollen*, reddened, hot, and tender. The *conjunctiva* of the lids and fornix is in-

tensely *inflamed* and the tarsal conjunctiva is covered by a grayish-yellow *exudation*, which also *infiltrates* the underlying tissues. In this way the lids become hard and cannot be everted. The exudation causes compression, and, as a result, there is a tendency to *sloughing* of the infiltrated parts. Besides this fibrinous exudation, there is a *discharge* of a thin, cloudy fluid. The preauricular and submaxillary glands are swollen. With these local signs, there are the prostration and other *constitutional symptoms* of diphtheria, and there may be local evidences of the disease in other parts of the body.

At the end of a week the exudation disappears, partly through *absorption*, partly through necrosis and *sloughing*, causing a loss of substance covered by *granulations*. The secretion now becomes more abundant and *purulent*.

The defects in the lining of the lid gradually cicatrize, this process causing various *deformities:* symblepharon, trichiasis, and entropion. There is frequently *corneal ulceration*. When the diphtheritic process is severe, the infiltration spreads to the ocular conjunctiva, destroys the nutrition of the cornea through pressure, and sight is always lost.

Etiology.—The disease is due to *contagion* from another case of diphtheria; sometimes a purulent conjunctivitis changes its character and becomes diphtheritic; occasionally it occurs in the course of scarlatina and measles. Though the Klebs-Loeffler bacilli are responsible for the disease, other micro-organisms such as streptococci, pneumococci, and xerosis bacilli are found in the discharge. Some very serious cases having all the clinical manifestations of severe diphtheritic conjunctivitis may present streptococci exclusively.

The Prognosis in regard to sight is always *serious;* in regard to life, it depends upon the constitutional effects and general condition of the child.

Treatment.—*Prophylaxis:* The precautions described under gonorrhœal ophthalmia must be employed in this disease, to protect physician, nurse, and attendants. Besides being con-

tagious, the disease is infectious, hence the patient should be *isolated;* other children must be removed. The *unaffected eye* must be *shielded.*

Treatment of the Affected Eye: Careful *cleansing* with weak antiseptic solutions (boric acid, corrosive sublimate). *Cold* compresses may be applied, but must be used cautiously on account of the enfeebled circulation. After a short period, *hot compresses* are used. When the exudation has separated, we apply a 1-per-cent. solution of *nitrate of silver.* We endeavor to *prevent sequelæ* due to cicatrization, by frequent separation of the lids from the globe, and by keeping the two surfaces apart by a roll of absorbent cotton smeared with some bland ointment. Corneal ulceration must be treated as described in the next chapter. Canthotomy and scarification are inadvisable.

Constitutional: We must remember that the eye affection is merely the local manifestation of a constitutional disease. Hence the general treatment of diphtheria including *injections of antitoxin* and supporting measures, must be carried out; the serum should also be instilled into the conjunctival sac.

CROUPOUS CONJUNCTIVITIS

A rather uncommon form of inflammation with deposit of an *exudation upon the surface* of the conjunctiva, upon which it hardens into a membrane. There is *no infiltration* into the tissues; this constitutes the essential anatomical difference between croupous and diphtheritic conjunctivitis. There are *no constitutional symptoms* such as accompany diphtheria.

Symptoms.—Those of acute catarrhal conjunctivitis; the lids and conjunctiva swell and redden but *remain soft.* After a few days a *fibrinous membrane* forms upon the palpebral conjunctiva; when this exudation is pulled off, a raw surface presenting a few bleeding points is seen; under such circumstances the membrane re-forms. The cornea is not involved except in very severe cases, and then usually escapes serious

injury. The disease lasts two or three weeks and there are usually no sequelæ.

Etiology.—Examination of the membrane or discharge often discloses Klebs-Loeffler bacilli together with other micro-organisms; in these cases the disease is thought to be a *mild form of diphtheritic infection.* In other examples the diphtheria bacillus is absent. Membrane formation may complicate gonorrhœal conjunctivitis or accompany pneumococcus or Koch-Weeks conjunctivitis. In a third class of cases the affection is caused by *irritants* (mechanical, chemical, or thermic), such as nitrate of silver, acids, lime, molten lead, burns, and injuries in general.

Treatment.—That of *acute catarrhal conjunctivitis.* As soon as the membrane shows no tendency to re-form, applications of 1-per-cent. solution of *nitrate of silver* are useful. Occasionally there is recurrent formation of the membrane for many months. Smears and cultures should be made in every case; when the diphtheria bacillus is found, and in doubtful cases, antitoxin is indicated.

GRANULAR CONJUNCTIVITIS, TRACHOMA OR GRANULAR LIDS

A chronic form of conjunctivitis accompanied by *hypertrophy* of the conjunctiva and the formation of follicles ("*granulations*"), with subsequent *cicatricial changes.* It is a *common* disease, occurs at *all ages,* and usually affects *both eyes.* There is more or less secretion, which is *contagious.* It is a very important affection on account of its disastrous complications and sequelæ, which are responsible for many cases of partial or total blindness.

Subjective Symptoms.—More or less photophobia, lacrymation, itching and burning sensations, feeling of foreign body, pain, and visual disturbance. In a good many cases there are no subjective symptoms.

Objective Symptoms.—There may be *swelling* of the lids, narrowing of the palpebral aperture, and *drooping* of the

upper lid (from weight and swelling), but very often these external evidences are absent. There is a variable amount of muco-purulent *discharge*, marked in recent cases, scanty in chronic forms. The *conjunctiva* of the tarsus and fornix is *reddened*, thickened, and uneven, on account of *hypertrophy* and the occurrence of *granulations*. The ocular conjunctiva is often somewhat injected.

Varieties and Pathology.—Basing the subdivision upon variations in appearance, we distinguish three forms: (1) papillary, (2) granular or follicular, and (3) mixed.

(1) *Papillary Form.*—A large number of small elevations (*papillæ*) are seen upon the greatly *thickened conjunctiva*, giving the latter a velvety appearance, or, if the papillæ are larger, a raspberry-like aspect. This form affects only the *tarsal* conjunctiva, and chiefly the *upper* lid. The papillæ are caused by the hypertrophied conjunctiva being thrown into folds and depressions; they are covered by an increase in epithelium and the connective-tissue interior is infiltrated with round cells.

(2) *The Granular or Follicular Form* presents a preponderance of *trachoma granules* (Fig. 124, Plate IX). These are gray, rounded, *translucent* bodies showing through the conjunctiva; they have been likened to frog's spawn. They may be small and *rounded*, larger and *oval*, projecting or *flattened*, succulent or warty. They are present principally in the *fornix*, and when numerous are arranged in rows. In the tarsal conjunctiva they are less numerous, smaller, and less distinct, being hidden by the papillæ. Occasionally, trachoma granules are formed upon the semilunar folds and the bulbar conjunctiva. The granules are rounded *collections of cells in a delicate connective-tissue reticulum;* the cells are lymphocytes in the peripheral zone, and mononuclear leucocytes with a few phagocytes in the interior; the granules usually merge with the surrounding tissue, but in old cases they may present an incomplete capsule.

(3) *The Mixed Form* represents the *common* condition, the

FIG. 121.—Acute Catarrhal Conjunctivitis.

FIG. 122.—Ophthalmia Neonatorum.

FIG. 123.—Follicular Conjunctivitis.

FIG. 124.—Trachoma.

FIG. 125.—Phlyctenular Conjunctivitis.

FIG. 126.—Episcleritis.

Figs. 121-126.—Diseases of the Conjunctiva and of the Episcleral Tissue

papillary and granular varieties being almost always found together, the former more prominent in the palpebral conjunctiva, the latter predominating in the fornix.

Occasionally trachoma granules undergo a fibrous change and appear as hard, flattened projections upon the tarsal and retrotarsal conjunctiva of the upper lid.

Course.—The process progresses up to a certain point, and is then followed by cicatricial changes in the conjunctiva (*cicatricial stage*). This cures the trachoma, and the *papillæ and granules disappear;* but the conjunctiva does not return to a normal condition, the cicatricial changes and contraction leading to certain *sequelæ;* the seriousness of the latter depends upon the severity of the process and the amount of hypertrophy and subsequent cicatrization. In the tarsal conjunctiva the cicatricial process causes narrow, whitish bands and *scars* (Fig. 138, Plate X), sometimes a network; in advanced and severe cases the entire surface may be replaced by a pale, smooth *cicatricial membrane.* In the fornix, cicatrization changes the conjunctiva into a pale, bluish-white membrane, and as a result of contraction the *transition fold is shortened* or disappears.

Clinical Varieties.—Clinically, trachoma presents a number of variations in its course. Occasionally the invasion is acute, *acute trachoma*, and accompanied by marked inflammatory symptoms and profuse purulent discharge; such cases resemble purulent conjunctivitis; the absence of gonococci in the secretion and the presence of the trachoma granules serve to differentiate, but frequently the swelling hides the latter; we may have to wait several days, until the swelling subsides somewhat, before we can decide.

Most frequently the disease begins *insidiously;* it may exist unknown for months, before the subjective symptoms become annoying. Most cases of trachoma are *chronic* in their course and the duration is months or years.

Not infrequently we meet with a form of trachoma designated by H. Knapp as *simple or non-inflammatory trachoma,*

in which there is abundant production of large, soft granulations of the follicular variety in the palpebral and retrotarsal portions of the conjunctiva of both lids, without evidence of inflammation and with slight or no symptoms of irritation or discomfort.

Besides these differences in the intensity of the inflammatory symptoms, there are great variations in the amount of change in conjunctiva and cornea. There are *mild cases*, in which there are but little hypertrophy and insignificant cicatricial changes in the conjunctiva, so that afterward we can scarcely be sure that trachoma has existed; such mild cases usually remain free from corneal complications.

In *moderate and severe cases* there always remain permanent *cicatricial changes*, which enable us to diagnose the previous existence of trachoma. When the cornea is implicated, the case is always a *serious* one.

Trachoma does not always progress uninterruptedly; there are often *intermissions* and *exacerbations*. *Relapses* are quite frequent, especially when treatment has been discontinued too soon.

Complications.—The most frequent are pannus and corneal ulceration, both causing disturbance of sight.

Pannus consists of a newly formed *vascular tissue*, which usually covers the upper part of the cornea (Fig. 138, Plate X). The affected portion of the cornea presents a *cloudy* appearance, and is grayish and translucent; its surface is *uneven* and *vascularized*, the blood-vessels springing from the conjunctival vessels at the limbus. The process advances until it covers the *upper half* of the cornea. Finally, the entire cornea may be covered and *vision be reduced* to perception of light. Unless subsequent changes occur, complete retrogression is possible, so that the cornea can become transparent again. In marked cases *iritis* is apt to develop. Pannus is not merely due to mechanical irritation, but to a change similar to that which occurs in the conjunctiva; it is a lymphoid infiltration with new blood-vessels be-

tween Bowman's membrane and the epithelial layer of the cornea.

Ulcers of the Cornea occur with or without pannus, leave opacities, interfering with vision according to seat and density.

Sequelæ.—Complete cure occurs usually in mild cases only, or in some of the severer forms when subjected to early treatment. Sequelæ are very common, affect the conjunctiva, cornea, and lids, and produce permanent disability of the eye.

1. *Trichiasis and entropion* result from cicatricial contraction of the conjunctiva with curving of the tarsus; they are more marked in the upper lid. As a result of this distortion of the lid with changes in the position of the cilia, there is mechanical interference with the cornea, causing ulceration.

2. *Ectropion* (usually of lower lid) sometimes follows from hypertrophy of the conjunctiva and contraction of the orbicularis.

3. *Symblepharon* results from cicatricial contraction of the conjunctiva; when marked, there is obliteration of the fornix. This condition restricts the movements of the eyeball.

4. *Corneal opacities* result from pannus and corneal ulcers. After lasting some time, pannus changes into a thin, permanent layer of connective tissue.

5. *Staphyloma of the cornea* follows in some cases.

6. *Xerosis*, a contracted, dry, and scaly state of the conjunctiva, with changes in the cornea, may occur in severe forms.

Etiology.—Trachoma is caused by *contagion* from another eye transferred through the *secretion*. The transfer from one eye to another may take place by the fingers, but usually by towels, handkerchiefs, and the like, which are used in common by many persons. The liability to infection is in direct proportion to the amount of discharge; the more profuse the discharge, the greater the danger of infection. The disease spreads most extensively in schools, asylums, and barracks,

and among people who live *crowded* closely together, who are careless in regard to *cleanliness*, and who are handicapped by *bad hygienic surroundings*. It is found most frequently among the *poorer classes*. It is common in Russian and Polish Jews, Hungarians, Italians, the Irish, Japanese, and Chinese. It occurs with especial frequency in *certain countries*—Arabia, Egypt; it is endemic in the latter country and a majority of the natives are afflicted (hence often called *Egyptian ophthalmia*). It is supposed that the soldiers of Napoleon added to the prevalence of the disease in Europe upon their return. In Europe it occurs much more extensively in the East than the West, and much more frequently in low lands (Belgium, Holland, Hungary) than in elevated countries (Switzerland). In America it is common among the foreign population of Eastern cities, especially immigrants from Eastern Europe; but it is also fairly common among native Americans, especially in some parts of the Middle West; it is frequently found among Indians, while negroes are rather exempt.

It seems likely that the contagious principle in the secretion is a *micro-organism* or its toxin; a number of such have been described, each in turn failing to be accepted as the cause of trachoma. The latest claimants are very small diplococci isolated from the discharge and the follicles and called *Trachoma Bodies* (also *clamydozoa*); it is uncertain whether they are protozoa or bacteria, but they are not the specific cause of trachoma since they have also been found in other conditions such as non-gonorrhœic ophthalmia neonatorum and in chronic conjunctivitis.

Treatment consists in an attempt to reduce the inflammatory symptoms and secretion, and to check and remove hypertrophy of the conjunctiva, thus shortening the duration and diminishing the liability to conjunctival cicatrization and to sequelæ. This is accomplished either by the use of certain irritating applications, or by mechanical and surgical means.

Irritating Applications: Sulphate of copper in the form of a crystal or pencil is the favorite local application. Nitrate

of silver (1 or 2 per cent. solution), glycerole of tannin (5 to 25 per cent.), copper citrate (cuprocitrol) in 5 to 10 per cent. ointment, solution of mercuric bichloride (1: 1000), and the alum stick are also employed.

Mechanical and Surgical Treatment includes expression, grattage, abscission of the granulations, excision of a strip of the fornix, excision of the tarsus and a strip of the fornix, electrolysis, *x*-rays, radium, and carbon-dioxide snow. *Expression* is the most popular of these mechanical methods, and has the widest range of usefulness. The kind of treatment best suited depends upon the nature of the case, the presence or absence of inflammatory symptoms, and the stage of the disease. *Mechanical treatment* is indicated in the granular form of trachoma, with *well-marked translucent granulations*, when there is an absence of severe inflammatory symptoms, and in the form which Knapp called non-inflammatory. *Irritating applications* are indicated as supplementary treatment to surgical procedures, and for cases of chronic trachoma, in which the granulations are of smaller size, or of the papillary variety, particularly when there is considerable *thickening of the conjunctiva.*

FIG. 127.—Sulphate of Copper Stick.

In *acute* forms and in acute exacerbations of chronic cases, when there is *much discharge*, solution of *nitrate of silver*, 1 or 2 per cent., is applied to the conjunctiva, the excess being washed away with water or salt solution. In many cases of this sort, however, it is advisable to suspend temporarily all irritative treatment and to prescribe *cold compresses*, instillations of 25-per-cent. solution of argyrol, and *mild* cleansing and antiseptic washes.

During the *cicatricial stage* copper is no longer indicated; the ointment of the *yellow oxide of mercury* is then of service.

If treatment is not continued until every trace of hypertrophy has disappeared, *relapses* are very common.

Sulphate of Copper.—The pencil is applied to the everted lids once a day, or every other day; it is drawn *lightly* across the conjunctiva two or three times, but applied only to the *hypertrophied portions*. The application should include the palpebral portion of the *transition fold* of the upper lid; in passing the copper stick under the tarsus, the cornea is protected by the lower lid (Fig. 129). The stick of copper sulphate should have a *flat, blunt end*, as shown in Fig. 127, and not be pointed or conical. After each application, the excess of copper sulphate is *washed off* with water or solution of boric acid; subsequently iced compresses may be applied for half an hour or longer. This treatment is *continued for months*, until every trace of hypertrophy has disappeared; after a time the applications are made more lightly and less frequently. Preliminary instillation of holocain may be resorted to for diminishing the pain.

Expression is performed with Knapp's roller forceps, or an instrument of similar construction, by means of which the granulations are *squeezed out* between two fluted rollers at the

Fig. 128.—Knapp's Roller Forceps for Trachoma.

end of the shafts (Fig. 128). The operation is painful and usually general anæsthesia is required. After eversion of the upper lid, one extremity of the instrument is passed back into the fornix and the other over the tarsus; using moderate compression, the forceps is drawn forward, pressing out the contents of the granules (Fig. 130). This procedure is repeated until the lid is free from granulations and presents a dark-red surface with small red points. The lower lid is then operated upon in the same manner. After expression, the conjunctiva is often brushed vigorously with a solution of mercuric bichloride, 1:500. Care must be taken *not to cause abrasions of*

the cornea and *not to tear the conjunctiva*. If the granulations are hard and horny, it may be well to scarify them before using the roller forceps. There are swelling and perhaps ecchymosis for two or three days after the operation. *Cold compresses* and *irrigations* with solution of boric acid are indi-

FIG. 129.—Method of Applying the Sulphate of Copper Stick to the Conjunctiva of the Upper Lid.

FIG. 130.—The Operation of Expression for Trachoma, as Practised upon the Upper Lid.

cated for a week; then any remaining roughness is treated with gentle applications of the sulphate-of-*copper* crystal every other day for a few weeks, or until the lids are normal.

The other mechanical or surgical means of treating trachoma are used much less frequently than expression. *Grattage* consists in scrubbing the granulations, with or without previous scarification, with a stiff toothbrush until all the granules are removed, and then thoroughly rubbing in a solution of mercuric bichloride, 1:500. *Excision* consists in the

removal of a strip of the retrotarsal conjunctiva, about 10 mm. broad, containing the granules, sometimes including the entire tarsal cartilage. Exposure of the everted conjunctiva to *x-rays* and to *radium* and the application of *carbon-dioxide snow* are also used.

Operative procedures alone seldom cure trachoma; they must be followed by other measures. But they often shorten the duration of treatment.

Treatment of Complications.—Recent *pannus* is best relieved by the treatment of the conjunctiva. In addition, we may use *atropine* occasionally, so as to keep the pupil dilated and prevent posterior synechiæ, since iritis is frequently present in these cases. If the pannus is very dense, we may apply the sulphate-of-copper stick directly to the cornea.

In well-marked cases of pannus of long standing, without corneal ulceration, and unaccompanied by much purulent conjunctival discharge, a freshly prepared 3-per-cent. infusion of *jequirity* is occasionally rubbed into the everted conjunctiva or the powdered drug is dusted upon this surface; a very violent corneal and conjunctival inflammation is set up, accompanied by the formation of a croupous membrane (iced compresses are indicated in this stage); upon the subsidence of the process the pannus is often much improved and occasionally cured; this remedy must be used with extreme caution, since it has been the cause of destruction of the cornea. *Jequiritol*, an extract made from the seed, is somewhat safer for this purpose, since the dosage can be controlled.

The operation of *peritomy*, the excision of a narrow strip of conjunctiva surrounding the cornea with a view of cutting off the vascular supply, is occasionally performed for the relief of severe cases of pannus. For active *ulceration*, nitrate of *silver* is often used, and *atropine*, if iritis is suspected.

General Treatment must not be neglected. The eyes should be kept *cleansed* by the frequent use of solution of salt, boric acid, or bichloride of mercury (1:10,000). The *hygienic surroundings* of the patient should be made as perfect as pos-

sible, with proper ventilation, plenty of outdoor exercise, and good food.

Prophylaxis is very important. The patient and his family must be warned of the *contagiousness* of the secretion, and impressed with the necessity for keeping the patient's handkerchiefs, towels, wash basin, etc., apart from those of other persons. In schools, asylums, institutions, and barracks the *prevention of epidemics* of trachoma is a very serious matter, requiring constant vigilance, careful inspection of every new addition or inmate, and the *isolation* of trachoma cases so long as the latter are capable of conveying the disease.

Parinaud's Conjunctivitis is a rare, infectious disease of unknown cause, having for its chief features large reddish and yellowish granulations and small, superficial ulcers in the palpebral conjunctiva, constitutional disturbance, and swelling of the pre-auricular gland. It is usually limited to one eye. Prognosis is favorable, cure resulting in a few weeks or months.

PHLYCTENULAR CONJUNCTIVITIS

This disease, also known as *Eczematous Conjunctivitis* and as *Scrofulous Ophthalmia*, is a *circumscribed* inflammation of the conjunctiva, accompanied by the formation of one or more small reddened projections called *phlyctenulæ*. The latter consist of accumulations of lymphoid cells, which soften at their apices, forming small *ulcers*. The phlyctenulæ may appear upon the ocular conjunctiva, and then the disease is called phlyctenular *conjunctivitis;* they may be found upon the cornea, when the affection constitutes phlyctenular *keratitis;* or they may occur, and most frequently do occur, at the *limbus*, and then we speak of phlyctenular *keratoconjunctivitis* or *marginal keratitis*. Very frequently they occur in all three situations in the same individual. The pathology, symptoms, and treatment being the same in all cases, it is convenient to describe the three varieties collectively under the title of *Phlyctenular Ophthalmia*, whether the phlyctenules

occur in the epithelial layer of the ocular conjunctiva or its extension on the cornea.

Objective Symptoms.—The essential sign is the occurrence of one or more small, grayish *elevations*, or nodules, about the size of a millet seed (1 or 2 mm.), at some part of the conjunctiva or cornea, frequently at the limbus. The phlyctenule is surrounded by an area of conjunctival *hyperæmia* (Figs. 125, Plate IX, and 139, Plate X). The non-affected parts of the ocular conjunctiva are but slightly changed from the normal. The phlyctenule soon presents a small *ulceration* at its apex, which then occupies the level of the surrounding conjunctiva. It heals without leaving any changes in the conjunctiva. The entire process lasts from a few days to two weeks.

Occasionally one or more phlyctenules are of large size with purulent contents; such cases have been called *pustular ophthalmia*.

Generally, a number of phlyctenulæ appear at the same time; in this manner the entire ocular conjunctiva may be reddened; in such cases the palpebral conjunctiva will be congested. The nodules may become absorbed without going through the stage of ulceration.

When the phlyctenule appears upon the *cornea*, the infiltrations and subsequent ulcers are usually *superficial* and heal without the production of lasting changes in the cornea. But sometimes they spread into the corneal substance, and then leave a permanent *opacity*. Rarely, the ulcer perforates; or a number of ulcers may, by confluence, spread along the surface of the cornea.

Fascicular Keratitis.—The ulcer resulting from the phlyctenule may advance from the margin to the centre of the cornea, drawing after it a fascicle of blood-vessels. In this manner there is formed a narrow, red band of vessels, extending some distance over the cornea; at the apex of this fascicle is seen a small, gray crescent, corresponding to the advancing margin of the ulcer, which has healed in the peripheral parts.

This form of ulceration always remains superficial; when the process terminates, the blood-vessels gradually disappear and a superficial linear opacity remains.

Occasionally, as a result of persistent recurrence of phlyctenules, the cornea becomes clouded, uneven, and covered by superficial vessels; this condition is known as *phlyctenular pannus* and usually disappears by absorption.

The phlyctenule may, in severe cases, involve the *deep layers* of the cornea, forming a deep infiltration; this either becomes absorbed completely or leaves an opacity of the cornea; or it may become purulent and a deep ulcer result.

There is usually considerable *lacrymation;* if there is any discharge, it is mucous or muco-purulent and not abundant. As a result of constant lacrymation, there are frequently added *blepharitis*, excoriations at the external angles, *eczema* of the lids, ectropion of the lower lid, and occasionally blepharophimosis.

Subjective Symptoms.—*Photophobia* is marked when the cornea is involved, slight in conjunctival cases. When this symptom is prominent, there is considerable *blepharospasm*, so that the child will remain in a dark corner or bury its face in a pillow, and the eyes can be examined only with difficulty. There is discomfort, but not usually any pain.

Course.—The phlyctenules usually occur in *crops;* before one is completely cured another is apt to appear. In this way the course may become *protracted* and may extend over weeks. Each phlyctenule lasts from a few days to a week or two. *Relapses* are very common. Phlyctenulæ occur most frequently in *children* and in young persons, but are also seen in adults; in the latter, a single large phlyctenule may present the local appearances of episcleritis.

Etiology.—The disease is very *common*. It seems dependent upon some *constitutional error*. It occurs frequently in children who suffer from the so-called *scrofulous* diathesis; it is pretty certain that a large proportion of cases are associated with *tuberculosis*. It is especially frequent among the *lower*

classes, in whom dirt, poor food, and improper hygienic surroundings are contributory factors; also in children debilitated from disease and in those recovering from the exanthemata, especially measles. Improper diet and *errors of refraction* are predisposing causes. One frequently sees other manifestations of the predisposing diathesis, such as swelling of the cervical lymphatic glands, adenoids, eczema, coryza, blepharitis, chronic otorrhœa, etc. Sometimes, however, the affection occurs in children of the better classes apparently in good health.

Pathology.—The nodules consist of lymphoid cells situated between the epithelial layer and the sclera and Bowman's membrane, respectively; the epithelial covering is pushed forward, softens and is cast off, leaving an ulcer; the loss of substance is finally replaced by epithelium.

Prognosis is *favorable;* serious results are uncommon. The phlyctenulæ often leave no traces. In some cases corneal opacities of greater or lesser density remain, and if these are central, sight will be interfered with.

Treatment.—*Local: Calomel* dusted upon the eyeball once a day; this is believed to be slowly changed to corrosive sublimate by the action of the tears, and in this way to keep the eye bathed in an antiseptic fluid; calomel should not be employed if the patient is taking iodine, since such a combination produces the very irritating mercuric iodide in the tears. A favorite remedy is the ointment of the *yellow oxide of mercury* (1 or 2 per cent.); a piece about the size of a hempseed is deposited in the conjunctival sac and rubbed about with the lids; when there is a great deal of irritation, it is wise to withhold this ointment until less inflammation exists. If the symptoms of irritation are very prominent, it is better to irrigate with solution of boric acid, and to apply *cold pads* if the phlyctenulæ involve the conjunctiva, and *hot compresses* if they form upon the cornea; 25-per-cent. solution of argyrol may be useful under these circumstances, but must not be used too continuously.

If there is infiltration or *ulceration* of the cornea, *atropine, hot compresses,* and mild antiseptic washes are indicated. If there is fascicular keratitis, the ointment of the *yellow oxide of mercury* is employed; in such cases we can often cut short the progress of the disease by *cauterizing* the advancing edge of the ulcer with a fine electro-cautery point (Fig. 141), or with tincture of iodine. Bandages should not be applied; it is only in extreme cases of very deep ulceration that a bandage is indicated.

In corneal cases, the *photophobia and blepharospasm* are often very annoying symptoms. Instillation of solution of *holocain* will give not only temporary relief, but by encouraging the opening of the eyes produce a more or less lasting effect in breaking the spasm. Douching the eye with cold water, several times a day, may be effective. If a *fissure* of the outer canthus is present, touching this with 2-per-cent. solution of silver nitrate, or the stick of copper sulphate, is of value. In extreme and persistent cases of blepharospasm, if nothing else answers, canthotomy (p. 54) may be resorted to.

General treatment is of great importance. Suitable and nourishing *diet* with avoidance of sweets, improved hygienic *surroundings,* plenty of *fresh air,* and cold sponging and bathing are useful. The *nose* and naso-pharynx should receive proper treatment. These patients should not be allowed to remain in the house and in the dark, as they are inclined to do on account of the photophobia. *Smoked glasses* are prescribed to relieve this symptom. Calomel (gr. $\frac{1}{20}$ t.i.d.), *iron,* quinine, and arsenic are useful for internal administration, and cod-liver oil is of great benefit.

SPRING CATARRH

A rather uncommon disease of the conjunctiva, of *chronic* course, lasting for years, continuing *during warm weather* (more marked in summer than in spring) and disappearing entirely or to a great extent with the beginning of winter. It

is also known as *Vernal Catarrh.* The disease occurs chiefly in *children,* most frequently in boys. It may attack the tarsal or the bulbar conjunctiva, or both.

Objective Symptoms.—The *tarsal conjunctiva* presents hard, flattened *papillæ*, separated by furrows, giving a cobblestone appearance, and is covered by a delicate, bluish-white *film.* The *bulbar conjunctiva* shows at the inner and outer portions of the limbus hard, gelatinous *hypertrophies*, sometimes slightly pigmented, which may involve the cornea for a short distance, and which sometimes surround it. There are conjunctival congestion and some mucoid secretion. Either the palpebral, the more common, or the bulbar form predominates. During the winter these changes become less marked or disappear; they return with the advent of warm weather.

Subjective Symptoms include a feeling of *heat, lacrymation, intense itching,* and *photophobia;* these become worse in warm weather and disappear in the winter.

The *pathological changes* consist of hypertrophy of the subconjunctival connective tissue and of elastic fibres which undergo hyaline degeneration superficially; this gives rise to the bluish-white film; there is also proliferation of the conjunctival epithelium. Eosinophile leucocytes are abundant in the nodules and in the secretion.

Course.—The disease usually attacks *both eyes* and lasts in this intermittent way for several years or longer, finally becoming extinct and leaving no traces behind. Its *etiology* is *unknown.* It may be associated with hay fever. The disease is not contagious.

Treatment.—There is no certain cure. The subjective symptoms can be made less annoying by the remedies in use for catarrhal conjunctivitis. The agents most frequently resorted to are boric acid, corrosive sublimate (1 : 5000), the alkaline wash (page 396), acetic acid (2 drops of the dilute acid to an ounce of water), and salicylic-acid ointment (1 per cent.). Temporary relief from the distressing subjective

symptoms may be obtained by the instillation of 1-per-cent. solution of *holocain* in 1:10,000 *adrenalin*, the use of *cold compresses*, and the wearing of *smoked glasses*. Exposure to *radium* gives the best results when the granulations are of large size. X-rays and carbon-dioxide snow have also been credited with good results.

SYMBLEPHARON

A *cicatricial attachment* between the conjunctiva of the lid and the eyeball (Fig. 131). It may affect both lids, but usually the *lower;* sometimes it includes part of the cornea. It is called *anterior* or *partial*, when extending bridge-like from lid to globe, leaving a free portion of conjunctiva corresponding to the fornix; *posterior*, when it involves only the fornix; and *complete* when it affects all the conjunctiva.



FIG. 131.—Symblepharon.

Etiology.—It is caused by the junction of two opposing granulating surfaces; hence, it occurs after *injuries*, especially *burns* from lime, acids, and molten metal; also after operations; sometimes it follows *trachoma*, and occasionally diphtheritic conjunctivitis.

Symptoms.—Symblepharon often *interferes* with the movements of the eyeball, and this may cause diplopia. Traction upon the adherent parts excites *irritation*. In severe cases the cornea is included and sight interfered with; or, if there is inability to close the lids, lagophthalmos and its sequelæ may be present.

Treatment.—If anterior and not extensive, we divide the band and keep the two raw surfaces from uniting by *separating* them daily with a probe until they have cicatrized

separately; the interposition of a small roll of absorbent cotton saturated with some bland oil or ointment may aid in this purpose.

In more *severe forms*, and in all cases of posterior and complete symblepharon, the separated raw surfaces must be *covered with conjunctiva* or with *grafts* of skin or mucous membrane to keep them from uniting. This may be done (1) by *loosening* the adjacent bulbar conjunctiva and sewing it over the defect, (2) by *transplanting* pieces of mucous membrane from the lip or from the rabbit's conjunctiva, (3) by *skin-flaps* passed from adjacent surfaces, and (4) by Thiersch or Wolff skin-*grafts*, taken from other parts of the body and supported on an artificial eye or piece of sheet lead until adhesion has taken place; the last method is often successful.

PTERYGIUM

A triangular fold of membrane, extending from the inner or outer part of the ocular conjunctiva to the cornea (Fig. 132); the apex is immovably united to the cornea, the base spreads out and merges with the conjunctiva.



Fig. 132.—Pterygium.

Symptoms.—When recent, pterygium is rich in blood-vessels and hence of a red color; later it changes into a white, tendinous membrane. It *grows slowly* toward the centre of the cornea, giving rise to moderate symptoms of conjunctival *irritation*, and it may eventually cover a considerable part of the cornea; finally it becomes *stationary*. Besides more or less irritation, it causes *disfigurement*, may restrict motion of the eyeball, and spreads over the cornea, *interfering with vision*. It is generally situated to the *inner* side of the cornea, less frequently

to the outer side or in both situations. It may occur in one or both eyes.

Etiology.—Pterygium is thought by some to originate from pinguecula, the process extending to the cornea and drawing the conjunctiva after it. It occurs usually in *elderly* persons who are exposed to *wind* or *dust* (farmers, coachmen, masons, sailors). It is uncommon among the better classes.

Treatment consists in *removal* by one of a number of different *operative* methods. The pterygium may be *dissected away* and *cut off*, the conjunctival defect being closed by uniting the upper and lower borders, undermining the conjunctiva if necessary to bring the edges together. The *apex* of the pterygium must be thoroughly excised from the cornea, and its attachment in this situation scraped or *cauterized* with the electro-cautery, to prevent recurrence. Instead of cutting off the pterygium, it may be dissected from the cornea and some distance beyond and *stitched underneath* the detached conjunctiva, either above or below; or it may be divided into halves, of which one is *transplanted* above and the other below, being held in the conjunctival pocket by a suture. There is a tendency to recurrence; this is less when the membrane is transplanted than when it is simply abscised.

Pseudo-pterygium is an attachment of a fold of conjunctiva to the cornea as a result of ulceration of the latter; it occurs occasionally after gonorrhœal and diphtheritic conjunctivitis, burns, and other injuries. Separation from the cornea results in retraction of the conjunctival fold to its normal position.

INJURIES OF THE CONJUNCTIVA

These are very common, and include:

1. *Foreign bodies in the conjunctival sac,* consisting of dust, iron, coal, or ashes. They usually adhere to the inner surface of the *upper lid,* causing severe pain and irritation, and are readily removed after eversion of the lid.

2. *Wounds.*—Extensive wounds of the conjunctiva should be closed with one or more fine black silk sutures.

3. *Burns* are quite common, being due to boiling water, steam, lime, mortar, powder, molten metal, and acids. Following the accident a grayish *eschar* forms; this separates and leaves a *granulating* surface, which heals by *cicatrization;* in this way *symblepharon* often results. Burns of the conjunctiva are frequently accompanied by injury to the cornea; the results are then more serious. Treatment consists in complete *removal* of the caustic substance as soon as possible. The conjunctival sac is *washed out* with solutions which tend to *neutralize* the corrosive substance or render it insoluble; in the case of lime, mortar, or caustic alkalies, we flush out with a stream of solution of boric acid; if the corrosive agent consisted of an acid, the eye is irrigated with a weak solution of sodium bicarbonate. But since it is of the utmost importance to remove the irritating and destructive agent without any delay, it is unwise to wait for neutralizing solutions, but to irrigate with great quantities of *water* immediately, whether the foreign material is acid or alkaline. Solid particles are removed with absorbent cotton or forceps. Subsequently we use *cold* compresses, *atropine*, keep the conjunctival sac filled with a *bland ointment*, such as one-per-cent. boric acid or 1:3000 bichloride of mercury, and apply a loose gauze and cotton dressing. Unless the burn is very superficial, there will be eschars; when these loosen and come away, raw and granulating surfaces will be exposed; these have a great tendency to form *adhesions;* the latter must be separated frequently. Symblepharon is, however, very apt to occur notwithstanding the greatest care in separating these adhesions.

CHAPTER VIII

DISEASES OF THE CORNEA

Anatomy.—The cornea is the clear, transparent, anterior portion of the external coat of the eyeball; it is nearly circular, but is slightly wider in the transverse (12 mm.) than in the vertical direction; its radius of curvature is somewhat shorter than that of the sclerotic; the junction of the two is known as the *limbus*, but their tissues are in complete continuity. The cornea is composed of five layers (Fig. 133), from without inward: (1) Layer of epithelial cells; (2) Bowman's membrane; (3) the proper substance of the cornea; (4) Descemet's membrane; and (5) a layer of endothelium.



FIG. 133.—Vertical Section of the Cornea, Showing Minute Anatomy. A, Layer of epithelial cells; B, Bowman's membrane; C, Proper substance of the cornea; D, Descemet's membrane; E, layer of endothelium.

The epithelium covering the front of the cornea is of the stratified variety, formed of flattened, scaly epithelial cells superficially, of polygonal cells beneath these, and of columnar cells most deeply. Practically it is part of the bulbar conjunctiva.

Bowman's membrane is a thin, homogeneous membrane which separates the corneal epithelium from the proper substance of the cornea. Although usually described as a separate membrane, it is really a part of the corneal substance, and when highly magnified is seen to be composed of fine fibres which are intimately connected with the subjacent layer.

The proper substance of the cornea, the thickest layer, is formed of connective tissue arranged in *lamellæ*, the planes of which are parallel to the surface of the cornea; these lamellæ are connected with one another.

The ultimate fibrils of which the lamellæ are composed, as well as the different bundles of fibrils forming the lamellæ, are held together by means of a transparent *cement* substance. The corneal substance is traversed by a system of spaces or *lacunæ*, situated in the cement substance separating the laminæ, and sending off prolongations in every direction; these form small *canals* by means of which the lacunæ of the same plane and those placed above and below communicate. The spaces are filled with branching cells (*corneal corpuscles*), the branches of the cells passing into the small canals and communicating with adjoining cells. These cells are known as the *fixed corpuscles* in contradistinction to the leucocytes which move about and are called the *wandering cells of* the cornea. The proper substance of the cornea passes uninterruptedly into the sclera.

Descemet's membrane (the posterior elastic lamina) is a thin, firm, structureless, transparent, and highly *elastic* layer, placed posterior to the proper substance of the cornea; at the periphery of the cornea it passes over into radiating bundles of elastic fibres which form the *ligamentum pectinatum*.



Fig. 134.—Arcus Senilis.

Posteriorly, next to the anterior chamber, is a single layer of flattened, hexagonal cells, the *endothelium*.

The cornea is not provided with blood-vessels. The *capillary loops* from the anterior ciliary vessels form a ring around the circumference of the cornea. Its nutrition is provided for by the system of lymph canals just described. It is richly supplied with *nerves* derived from the ciliary nerves.

The line between cornea and sclera is known as the *limbus*. Near the margin of the cornea, just within the sclerocorneal junction, we frequently find an opaque, whitish ring or part of a ring; this is known as the *arcus senilis* or gerontoxon (Fig. 134); it is due to a deposit of fatty granules, and most frequently occurs in advanced age, though occasionally it is found in younger persons.

Inflammations of the Cornea (Keratitis) in general present the following:

Objective Symptoms.—(1) *Infiltration*, with dulness of surface and diminution of transparency; this may be followed by (a) *complete absorption* of the infiltration, (b) *incomplete*

absorption, leaving opacities, (c) *suppuration*, with formation of an *ulcer*, and (d) *cicatrization* (repair). (2) Limited or general *vascularization*, the blood-vessels being derived from the conjunctival loops at the limbus. (3) *Circumcorneal injection*. (4) There is often a complicating *conjunctivitis*. (5) Neighboring deep parts are frequently involved (*iris* and *ciliary body*), as a result of which there may be exudation in the anterior chamber.

Subjective Symptoms.—*Pain, photophobia, blepharospasm, lacrymation,* and *interference with vision.*

Varieties. –Keratitis may be divided into suppurative and non-suppurative.

Suppurative Keratitis.—The common forms are (1) phlyctenular keratitis, and (2) ulcers of the cornea. The uncommon forms are (3) keratitis e lagophthalmo, (4) neuroparalytic keratitis, and (5) keratomalacia.

Non-Suppurative Keratitis.—The common forms are (1) interstitial keratitis, and (2) vasculo-nebulous keratitis (pannus). The uncommon forms are (3) vesicular and bullous keratitis, (4) superficial punctate keratitis, (5) keratitis profunda, (6) sclerosing keratitis, and (7) band-shaped keratitis.

Phlyctenular Keratitis has been described under the title Phlyctenular Conjunctivitis (p. 123), and the special symptoms arising when the cornea is involved have been pointed out.

ULCER OF THE CORNEA

An *infiltration* of a certain portion of the cornea, followed by suppuration and *loss of substance* of the infiltrated spot. The affection is of common occurrence.

Subjective Symptoms.—*Pain, photophobia, lacrymation,* and *blepharospasm.* Sometimes these symptoms are slight, or even absent, and yet such a torpid ulcer may be very extensive and serious.

Objective Symptoms.—An ulcer begins with a dull, grayish, or grayish-yellow *infiltration* of a circumscribed portion

of the cornea (Figs. 135 and 136, Plate X); *suppuration* takes place in this area, the superficial layers are cast off, and thus there is *loss of substance*. The process may progress in two directions: it may either travel over the cornea so as to involve a greater *area*, or it may become *deeper:* it may extend both in area and in depth. Very often the advance takes place in one direction, across the cornea; sometimes there is at the same time a tendency to heal at the opposite side, so that the ulcer merely changes its situation (creeping or serpiginous ulcer). There is nearly always more or less grayish *infiltration* of the cornea immediately *surrounding* the loss of substance, and considerable ciliary *injection*.

If the ulcer is small and superficial, it will cleanse itself in the course of a few days. The destroyed portion of the cornea will be cast off, the infiltrated border will become clear, and repair set in; this is accompanied by the appearance of blood-vessels which spring from the limbus; the process terminates in cicatrization. When the ulcer is very superficial, the cornea may remain perfectly transparent. But when some of the proper substance of the cornea has been destroyed, new connective tissue takes its place, and such a scar is always more or less *opaque*. The seat of the ulcer may also be marked by a slight depression (*corneal facet*).

The detection of the extent of infiltration and ulceration is facilitated by the instillation of a few drops of a 2-per-cent. solution of *fluorescein*, which stains green all such ulcerated or infiltrated parts.

When the ulcer is deeper, both subjective and objective symptoms are more pronounced, and the complications and sequelæ are more serious. Neighboring structures give evidences of inflammation: *conjunctivitis*, congestion of the iris, even *iritis and cyclitis* with their symptoms, including hypopyon. The suppurative process may spread to the interior of the eye, setting up *purulent irido-cyclitis* or *panophthalmitis* with destruction of the eye, especially if the process is virulent.

FIG. 135. Simple Ulcer of the Cornea.

FIG. 136.—Infected Ulcer of the Cornea with Hypopyon.

FIG. 137.—Adherent Leucoma.

FIG. 138.—Cicatricial Stage of Trachoma, with Pannus.

FIG. 139.—Phlyctenular Keratitis.

FIG. 140.—Interstitial Keratitis.

Figs 135-140 Diseases of the Cornea.

Hypopyon is a collection of pus in the anterior chamber. The pus is not derived from the ulcer, but is an exudation from the inflamed iris and ciliary body. It collects at the bottom of the anterior chamber (Fig. 136, Plate X), or it may partially or completely fill this space. It may either remain fluid, or when mixed with fibrin it may form a semi-solid, globular mass.

Such a deep ulcer may heal with no other permanent injury except marked corneal *opacity*, or there may be added a bulging (*keratectasia*). Deep ulcers frequently have their course modified by the occurrence of *perforation* of the cornea, which, in healing, affects the usefulness and safety of the eye in various ways.

Perforation of the Cornea may or may not be preceded by a *protrusion of Descemet's membrane* through the floor of the ulcer, forming a small, transparent vesicle (*keratocele*). Perforation may be spontaneous, or it may be caused by increased pressure resulting from the blepharospasm, various straining efforts, such as crying, sneezing or coughing, or occasionally by force exerted in examining the eye. The aqueous humor escapes, often carrying the iris into the wound; the eye feels soft; the anterior chamber is obliterated, and iris and lens are in apposition with the cornea. Perforation of the cornea has a favorable effect upon the course of the affection: the subjective symptoms are relieved, and the ulcer begins to heal as a result of diminished tension.

When the opening closes by cicatrization, the iris may regain its normal position. But frequently it continues entangled in the perforation, or remains *prolapsed*, and becomes incorporated with the scar. Such a condition is called *anterior synechia;* the dense, white cicatrix to which the iris is attached is known as *adherent leucoma* (Fig. 137, Plate X). Most frequently only a portion of the iris is drawn into the scar; the pupil is then more or less pear-shaped. Occasionally the entire pupillary margin may be adherent, causing both exclusion and occlusion of the pupil. If the iris remains

fastened to a bulging cicatrix of the cornea, the condition is known as *corneal staphyloma.*

At the time of perforation, the *lens* may become dislocated, and occasionally it escapes. When it is pushed forward and lies in apposition with the margins of the opening and then recedes after the anterior chamber is re-established, it frequently presents a proliferation of the subcapsular epithelium which has become irritated by the pressure of the lens upon the cornea, forming a white spot upon its anterior surface (Fig. 227), known as anterior capsular or *anterior polar cataract.*

Occasionally the perforation fails to close and a *fistula* of the cornea results; this condition exposes the eye to subsequent serious inflammation and jeopardizes its safety. *Intraocular hemorrhage* may follow a sudden perforation of the cornea and destroy sight.

Etiology.—Ulcers of the cornea are usually found in *adult and aged* individuals; phlyctenular ulcers are the only ones which are common in children. Ulcers are much more frequent among the *lower* than among the better classes, and occur often in individuals in whom the *general health is poor.*

The process is essentially an *infection* by various microorganisms (pneumococci, streptococci, staphylococci, etc., Plate VIII), frequently introduced by the secretion of chronic *conjunctivitis,* and especially by that of *dacryocystitis,* when the protecting corneal epithelium has been lost at some spot.

According to etiology, corneal ulcers may be divided into (a) *primary,* when starting in the cornea itself, and (b) *secondary,* when they have extended from adjacent structures —most frequently the conjunctiva.

The exciting causes are: (1) *traumatism* (foreign bodies, injuries —often slight, such as the scratch of a finger-nail, misplaced cilia); this is the most frequent cause; (2) conjunctival inflammations (catarrhal, gonorrhœal, trachoma, diphtheritic); (3) phlyctenular keratitis; (4) disturbances in nutrition of cornea (paralysis of trigeminus, keratomalacia, glau-

coma); (5) infection during operations; (6) acute infectious diseases, especially variola; (7) herpes.

Clinical Forms.—Corneal ulcers occur under many different forms and these are named according to the etiology, appearance, or course. Some of these have already been considered. Others warranting special mention are:

(1) *Simple Ulcer* is small and superficial with symptoms of slight or severe irritation, no tendency to perforation, terminating in uncomplicated healing; phlyctenulæ and slight injuries often cause such ulcers.

(2) *Catarrhal Ulcer* complicates catarrhal conjunctivitis in adults. With increase in subjective symptoms, peripheral punctate infiltrations appear, coalesce into a crescent changing to a superficial ulcer, concentric with and just within the limbus. The course is usually favorable and healing prompt; if opacities remain, they do not reduce vision, being beyond the pupillary area. Rarely perforation may occur.

(3) *Deep Ulcer* is one which shows a tendency to involve the deeper layers and to perforate rather than to spread over the cornea. The symptoms are apt to be marked, the iris is usually involved, and hypopyon is often present; hence the results are usually serious.

(4) Infected Ulcer (*Serpent*, Sloughing, or Pneumococcus Ulcer), often known as *Hypopyon Keratitis*, is a very *virulent* form in which the process *spreads* over considerable of the cornea and also deeply. It is quite *common*, especially in warm weather; it occurs almost exclusively in adults, particularly in elderly, debilitated individuals; the cause is an *injury*, often a slight one, and the infecting agent is the *pneumococcus* to which sometimes other micro-organisms are added. The subjective symptoms are usually severe, occasionally slight. Accompanied by some swelling of the lids and marked conjunctival and ciliary congestion, a grayish-yellow infiltration appears at or near the centre of the cornea; this changes rapidly to an ulcer with *sloughing margins;* the advancing edge presents a yellowish crescent (Fig. 136, Plate

X); surrounding the ulcer is a cloudy area made up of fine lines; the rest of the cornea is often dull and gray. The ulcer spreads very rapidly, much of the cornea becomes destroyed, and *perforation* takes place. There is early and intense *iritis*, and *hypopyon* is almost always present. Owing to the virulence of the process and the accompanying iritis, much *damage* results to the eye: adhesion and prolapse of the iris are frequent, the pupil is often occluded, and iridocyclitis and panophthalmitis are not uncommon; even in favorable cases there will be marked opacity of the cornea and often staphyloma; there results, therefore, serious *impairment of vision*.

(5) *Rodent Ulcer* (Mooren's Ulcer) is a rare, superficial form, never perforating, which occurs in elderly, enfeebled subjects, sometimes bilateral, of lengthy duration and unknown cause. It starts at the upper edge of the cornea, being limited in the direction of the limbus by a gray, *undermined rim* which is its characteristic feature; it is accompanied by marked irritative symptoms. As soon as cicatrization begins there is apt to be a relapse and an advance on the cornea. Thus a succession of extensions and intermissions follow each other and, unless the process is arrested by cauterization, the entire cornea becomes covered and sight is permanently and seriously interfered with.

(6) *Marginal Ring Ulcer* (Annular Ulcer) is one which encircles the periphery of the cornea and, if deep, interferes with its nourishment. Examples of superficial ulcers of this sort are seen in phlyctenular kerato-conjunctivitis (p. 124) as the result of the coalescence of marginal phlyctenules; also in elderly, gouty individuals in whom a number of small ulcers form more or less of a circle but, although accompanied by much irritation and a tendency to relapse, cause little damage. A more serious type is observed occasionally in debilitated subjects in whom the ulcers are deeper, form a groove encircling the cornea, and tend to perforate; this may also happen as a complication of gonorrhœal ophthalmia.

(7) *Central Ulcer* (Indolent Ulcer) is the name given to a simple ulcer when its base is transparent or but faintly gray, this peculiarity being due to defective corneal nutrition. It is usually small, superficial, central, devoid of symptoms of irritation, shows no tendency to spread or to perforate, occurs chiefly in weak children or in trachoma, and is followed by little or no opacity, but often by a small pit (facet) which easily escapes detection, but which causes much reduction in vision on account of irregular astigmatism.

(8) *Herpetic Ulcer* (Herpetic Keratitis) results from ruptured herpetic vesicles, spreads superficially, presenting either a round, notched margin or a depressed longitudinal furrow which is anæsthetic; the course is slow and there is a tendency to relapses.

(9) *Dendriform Ulcer* (Dendritic Keratitis) is a rare and chronic form of superficial ulcer, which commences with a grayish line and spreads by sending out branches which present small knob-like extremities. Not infrequently it is due to malaria. There are irritative symptoms, the cornea may be anæsthetic, and after healing the corneal scars are represented by lines corresponding to the distribution of the ulcers.

(10) *Atheromatous Ulcer* is one which develops in old degenerated scars of the cornea.

(11) *Abscess of the Cornea* is the purulent infiltration in the substance of the cornea which represents the first stage of infected ulcer. The term *Ring Abscess of the Cornea* refers to an infection, following penetrating wounds and operations, especially cataract extraction, in which a yellow ring develops in the central portion of the cornea, soon followed by extension and destruction of this part, often succeeded by panophthalmitis.

Treatment may be divided into (1) constitutional, (2) treatment of pre-existing local conditions, (3) local treatment of the ulcerative process.

Constitutional.—Since ulcers usually occur in persons in whom the general condition is below par, it is necessary to *improve the tone of the system* by attention to diet, fresh air, hygienic surroundings, condition of the bowels, etc.

Treatment of Pre-existing Local Conditions.—Foreign bodies are to be removed and other local irritating conditions remedied. The various forms of conjunctivitis and dacryocystitis must receive careful attention and neighboring infective foci (diseased teeth, tonsils and sinuses) be eliminated.

Local Treatment includes atropine (sometimes eserine), holocain, dionine, bandage, hot compresses, antiseptic lotions, scraping, cauterization, paracentesis of the cornea, and division of the ulcer by Saemisch's method.

Atropine must be instilled in sufficient quantity to keep the pupil dilated; it has a sedative effect and acts favorably upon the ulcer by diminishing the iritis. One drop of a 1-per-cent. solution may be used three times a day or oftener. When

the ulcer is central, the iris is drawn away from the seat of perforation, and there is less danger of adhesion or prolapse. When the ulcer is *peripheral* and deep, so that a perforation is imminent, *pilocarpine* (1 or 2 per cent.) or *eserine* (one-third of 1 per cent.) may be substituted, for the same reasons.

Holocain is a valuable remedy for temporarily relieving the pain and photophobia; cocaine must never be used for any length of time since it has an injurious effect upon the cornea. *Dionine* (2 to 10 per cent.) is also useful for this purpose.

Protection is afforded by *smoked glasses* or by a *bandage*. A lightly-applied bandage (*protective*) is not only comfortable, but by keeping the lids closed and immobile it prevents irritation of the ulcer; it also supplies beneficial warmth. With much discharge, the bandage is contraindicated in superficial ulcers. But in cases in which perforation of the cornea is liable to occur, a firm (*pressure*) bandage is applied; this must be removed and replaced several times a day to permit cleansing of the eye and local applications.

Hot Compresses should be applied for half an hour at a time, several times a day; they favor healing of the ulcer.

Antiseptic Lotions, such as solutions of boric acid, sodium chloride, bichloride of mercury (1:6000), act as cleansing agents, and are especially useful when there is much discharge.

Other Measures include dusting with *iodoform* or nosophen and then bandaging, hot air, and subconjunctival injections of mercury oxycyanide (1:4000). Argyrol and protargol, though used, entail the risk of a permanent brown stain at the seat of the ulcer. *Ethyl hydrocuprein* (optochin), a derivative of quinine, used in 1-per-cent. solution or ointment several times a day, is sometimes valuable in pneumococcus ulcer.

In virulent forms of infected ulcers, autogenous vaccines, diphtheria antitoxin, and boiled milk (aolan) have been employed by subcutaneous and intramuscular injection, the foreign protein giving favorable results in some instances.

To Limit Spreading: If these remedies are insufficient and

the ulcer spreads, we must destroy the infective focus either by *scraping* the floor and margins of the ulcer with a small, sharp curette or, better, by *cauterizing* this area. Cauterization is effected by tincture of iodine, pure liquid carbolic acid, or by the actual cautery or the electro-cautery.

Tincture of Iodine offers a very efficient mode of disinfecting and cauterizing corneal ulcers. A small piece of absorbent cotton is wound firmly upon an applicator so that the end of the cotton tuft will be pointed, dipped into tincture of iodine and then exposed to the air for a few seconds so that there is no excess of liquid. It is now brushed upon the ulcer and especially its infiltrated margins, after local anæsthesia. It is usually necessary to repeat the cauterization a number of times on successive days.

Fig. 141.—Eye Electrodes.

Electro-Cautery.—After thorough anæsthesia of the eye, one of the electrodes shown in Fig. 141 is placed cold upon the part to be cauterized, the connection made so that the burner assumes a deep red color, and then the connection quickly broken. Successive points of the margins of the ulcer are cauterized in this manner, each for a very short period, so as to prevent perforation and the propagation of heat to deeper parts. In the absence of an electro-cautery apparatus a platinum probe fitted in a wooden handle or even a squint hook may be heated in the flame of an alcohol lamp, and used for this purpose. It may be advisable to render the outlines of the ulcer more distinct by the preliminary instillation of a drop of fluorescein solution (p. 136).

Paracentesis of the Cornea is another valuable measure. This puncture is frequently made with a paracentesis needle, which is provided with a thick shoulder to prevent the instrument from penetrating too far (Fig. 142); it may be made with the lance-shaped knife (Fig. 193), or with the Graefe

cataract knife (Fig. 194). After local anæsthesia and fixation of the eyeball, the instrument is passed perpendicularly to the surface through the cornea, near its lower margin, unless the situation of the ulcer requires another site. As soon as its point reaches the anterior chamber, the handle of the instrument is depressed and the knife or needle is pushed on horizontally, avoiding injury to the iris or lens, until the incision is about 3 mm. wide. Then it is withdrawn slowly with pressure upon the posterior lip of the wound, so as to evacuate the contents of the aqueous chamber gradually. It may be necessary to repeat the paracentesis or to reopen the wound with a probe daily until the ulcer cleanses itself.

FIG. 142.—Paracentesis Needle.

Saemisch's Operation of splitting the ulcer has been replaced to a great degree by the cautery and paracentesis, but is useful in some severe forms of infected ulcers. A Graefe knife is thrust through clear corneal tissue 1 or 2 mm. to the outer side of the ulcer, made to traverse the anterior chamber, and brought out 1 to 2 mm. to the inner side of the ulcer. The edge of the knife is directed forward, the ulcer is split through its centre, and the hypopyon removed. The incision must be reopened with a probe daily, until the ulcer becomes clean.

After spontaneous perforation of an ulcer, atropine is instilled (or eserine if the opening be peripheral), a pressure bandage applied, and perfect rest in the recumbent posture insisted upon. If there is a recent *prolapse* of the iris, an attempt to return this membrane to its normal position is generally unsuccessful and almost always unwise; under such circumstances, the iris is seized and *excised* close to the cornea; if there are adhesions to the margins of the opening, these should be freed; the operation has the effect of an iridectomy; sometimes the opening left after excision is covered by a flap made from the adjacent bulbar conjunctiva. Iridectomy

may also be indicated if, during the process of healing of a perforation, there is marked increase of tension or bulging of the cicatrix. But if the prolapse has existed for some days it must be allowed to remain; subsequent operative interference may then be indicated.

After the healing process has become fairly initiated, certain mildly stimulating remedies, such as the ointment of the ammoniated or the yellow oxide of mercury and solutions of dionine are used to hasten cicatrization and to clear up the cornea as much as possible.

Keratitis e Lagophthalmo (Desiccation Keratitis) is due to *exposure of the cornea* from defective closure of the lids (*lagophthalmos*). Under such circumstances the cornea becomes desiccated, the conjunctival secretion and atmospheric dust settle upon it, infiltration follows, and then ulceration of greater or lesser severity. The lower portion of the cornea is most frequently affected, because this part is left uncovered during sleep when the eyeball turns upward. The causes are paralysis of the orbicularis (*facial paralysis*), marked exophthalmos, various deformities of the lids, and long-continued exhausting illness. *Treatment* consists in curing the lagophthalmos if possible, frequent irrigation of the conjunctival sac with cleansing solutions, and closure of the lids by bandage or plaster; in slight cases it may be sufficient to apply a bandage at night. Unless the process has gone beyond certain limits it can be controlled by this plan of treatment.

Neuroparalytic Keratitis is an extensive and deep infiltration and ulceration of the cornea observed after paralysis of the *trigeminus*, disease of the Gasserian ganglion, or its removal for the cure of facial neuralgia. The changes are considered to be either trophic due to exposure and lodgment of foreign substances upon the insensitive cornea, or caused by other factors. There is no pain or lacrymation, the course is chronic, and the prognosis is unfavorable; there result always opacity and flattening of the cornea and often more serious consequences. *Treatment* consists in keeping the lids closed with bandage, shield, plaster, or sutures.

Keratomalacia (Xerotic Keratitis) is the result of lack of nutrition of the cornea. It is an uncommon disease which occurs in badly nourished infants and young children in the course of greatly debilitating diseases. The process begins in the conjunctiva of both eyes; soon the cornea corresponding to the palpebral aperture becomes cloudy and desiccated, ulcerates, and perforates. The great majority of such

patients die from the disease which is responsible for the corneal condition. *Treatment* consists in measures to increase the general strength; locally, the usual measures for corneal ulcers, especially warm, moist compresses and protective dressings.

INTERSTITIAL OR PARENCHYMATOUS KERATITIS

A *cellular infiltration* of the middle and posterior layers of the cornea, of frequent occurrence in *childhood, chronic* in its course, not leading to ulceration, but accompanied by more or less *inflammation of the uveal tract.* It is also known as *anterior uveitis.*

Objective Symptoms.—The affection begins either in the centre or at the margin of the cornea. If it starts in the centre, this part will present a *grayish infiltration,* the superficial layers at first retaining their normal lustre; this central patch soon spreads so that the whole cornea becomes implicated. If it commences at the periphery, one or more grayish spots are seen, which soon spread toward the centre and involve all the cornea. After the infiltration has become general, the cornea will become *softened,* of a dense grayish or sometimes yellowish-gray color, so that the iris can be seen only with difficulty, and vision is reduced to little more than perception of light. The surface of the cornea is now *steamy* and resembles ground glass. At this period, or even before, deep-seated blood-vessels (derived from the anterior ciliary) make their appearance and pervade more or less of the cornea (Fig. 140, Plate X), the advent of the blood-vessels giving the limbus a red and swollen appearance; they cover either the periphery, circumscribed sectors, or the whole cornea. This *vascularization* gives rise to a dirty-red or yellowish-red discoloration, which is known as the *salmon patch.* The progress thus far is accompanied by *irritative symptoms* and ciliary congestion and lasts one or two months.

The inflammation then begins to subside. The periphery of the cornea *clears up,* the blood-vessels become fewer, the irritative symptoms disappear, and *vision improves.* Several months or even a longer period is consumed in this process,

the centre of the cornea being the last portion to clear. In favorable cases, after a year or more, nothing but a very faint, central opacity and evidences of a few minute peripheral vessels can be found.

Not all cases will, however, run such a benign course. *The anterior portion of the uveal tract is regularly involved.* In mild cases, this will consist merely in congestion of the iris. But in more serious types there will be *iritis, choroiditis, cyclitis,* and changes in the *vitreous;* in such cases, after the cornea has become less opaque, we may find evidences of these inflammations, in the form of adhesions of the iris to the lens (posterior synechiæ), changes in the iris and choroid, opacities of the vitreous, and even occlusion and exclusion of the pupil. Keratectasia may also follow. So that more or less serious *impairment of sight* may ensue in unfavorable cases. Furthermore, the clearing-up process in the cornea may come to a standstill, leaving a dense *opacity.*

FIG. 143.—From a Photograph of a Patient, the Subject of Interstitial Keratitis, exhibiting the Signs of Inherited Syphilis, including Hutchinsonian Teeth.

Subjective Symptoms.—During the period of infiltration and vascularization there will be *photophobia, lacrymation, pain,* and *interference with vision,* the intensity usually depending upon the severity of the process; these

symptoms gradually subside during the progress of absorption.

Both eyes are usually involved; frequently the inflammation in the second eye commences after that in the first has existed for some weeks or months. In the exceptional cases occurring in adults, the disease is more apt to be unilateral.

Etiology.—The disease usually occurs between the *fifth and fifteenth years*, less commonly after this period, and rarely after thirty. The great majority of cases are due to *inherited syphilis;* in few instances it is tuberculous; the two conditions may be associated; it is rarely the result of acquired syphilis. In many cases there will be other

Signs of Inherited Syphilis (Fig. 143), such as characteristic physiognomy, peculiar conformation of the skull (square forehead, prominent frontal eminences, depressed bridge of nose), radiating scars at angles of mouth, scars in the mouth and pharynx, ozæna, enlarged cervical lymphatic glands, nodes on the bones, and more or less impairment of hearing. The permanent teeth are ill-developed, their angles rounded off, and there is often a crescentic notch in the free margin; these changes are especially marked in the upper central incisor teeth (*Hutchinsonian teeth,* Fig. 143).

Treatment.—*Local: Atropine, dionine* (5 to 10 per cent.), protection from light by *smoked coquilles* or by a shade, *hot compresses.* When the cornea begins to clear, we employ mild *stimulating ointments,* such as yellow oxide of mercury, often combined with gentle *massage,* or instil 10-per-cent. dionine, or dust dionine powder upon the cornea. We must be careful not to apply stimulating ointments too early.

Constitutional: Calomel, gr. $\frac{1}{10}$ four times a day, or *potassic iodide,* gr. v., combined with *corrosive sublimate,* gr. $\frac{1}{40}$, t. i. d., or inunctions of mercury, syrup of the iodide of iron or other preparation of *iodine,* cod-liver oil, iron and quinine, and attention to the general health. In the uncommon cases occurring in adults, we prescribe iodide of potassium, with or without mercury, by mouth or by injections. Many of these

patients give a positive Wassermann reaction; when this is the case, injections of salvarsan are indicated and of value.

Pannus (*Vasculo-nebulous or Vascular Keratitis*) has been described in connection with trachoma (p. 116).

UNCOMMON FORMS OF NON-SUPPURATIVE KERATITIS

Vesicular Keratitis and Bullous Keratitis are varieties which occur in blind eyes with increased tension and in damaged eyes with opaque and insensitive corneæ; the distinguishing feature is the occurrence of small, clear *vesicles* or large, transparent *blebs*, accompanied by marked symptoms of *irritation* and tendency to *recur*. Vesicles are also seen on the cornea in the course of acute febrile diseases, especially pneumonia and influenza, accompanying similar manifestations elsewhere, in *herpes* febrilis corneæ (p. 141) and in the keratitis complicating herpes *zoster* ophthalmicus (p. 42). When occurring with herpes the treatment of keratitis in general is indicated; the vesicles should be punctured, and quinine or sodium salicylate be given internally.

Superficial Punctate Keratitis complicates acute affections of the respiratory tract and begins with the symptoms of acute conjunctivitis. Numerous small gray spots appear in the superficial layers of the cornea, beneath Bowman's membrane; these are accompanied by gray radiating lines and by some general clouding. The disease resembles herpes, but it is bilateral and there are no vesicles. It occurs in young persons and lasts several months, after which there is complete absorption. Treatment comprises attention to the conjunctivitis and the bronchial affection, the use of atropine, hot compresses, and later the ointment of the yellow oxide of mercury.

Keratitis Profunda is a form of deep-seated inflammation of the cornea occurring in adults, in which a gray, central opacity of the cornea develops, accompanied by moderate irritative symptoms; it becomes entirely or almost perfectly absorbed in a few weeks, and requires treatment similar to that of interstitial keratitis.

Sclerosing Keratitis is the name given to the corneal complication of scleritis (p. 160). The portion of the cornea adjacent to the scleritic nodule participates in the process, and a triangular opacity remains. The symptoms and treatment correspond to those of scleritis.

Band-shaped Keratitis (*Transverse Calcareous Film of the Cornea*) is a whitish or grayish band, which extends across the cornea opposite the palpebral aperture, and often contains lime. It occurs usually in old persons, and in eyes which have been seriously injured or lost by a

previous intraocular affection. In eyes which retain vision, the treatment consists in gently scraping away the band and using solutions of sodium carbonate (gr. i. to ℥ i.).

A number of other forms of keratitis are described, but are of very rare occurrence.

Punctate Keratitis (*Descemetitis*) is the name given to dot-like deposits upon the posterior surface of the cornea formed of exudation in inflammations of the uveal tract (iritis, cyclitis, iridocyclitis). The name refers to a *symptom* and not to a disease. This condition is never the result of an inflammation limited to the cornea. It usually shows upon the lower portion of Descemet's membrane, the area being triangular with the base at the margin and the apex near the centre of the cornea (Fig. 162, Plate XI). These deposits are usually absorbed.

PROTRUSIONS OF THE CORNEA

These may be either (1) of *inflammatory* origin, including (a) staphyloma and (b) keratectasia; or (2) of *non-inflammatory* origin, comprising (a) keratoconus and (b) keratoglobus.

Staphyloma of the Cornea is a bulging *cicatrix* lined by *prolapsed iris*. It is one of the sequelæ of perforation of corneal ulcer (Fig. 144). It may be *total*, when it replaces the entire cornea, or *partial*, when it occupies only a portion of this area. In shape it may be globular, conical, or lobulated. Its color is *whitish* with bluish areas representing spots where pigment shows through the thin cicatrix; it may be all white or all bluish. Some blood-vessels are frequently seen on the surface. It varies in size, being small in some cases and so large in others that the lids cannot close.

Symptoms.—Besides the objective signs just mentioned, there are changes in the eyeball, in the staphyloma, and in the lids. There is almost always *increased tension*, often due to seclusion of the pupil. This condition causes *pain*, produces changes in the interior of the eye which lead to *blind-*

ness, results in an increase in the size of the bulging, and is responsible for staphyloma of the sclera. The conjunctiva becomes the seat of inflammation from mechanical irritation. The summit of the protrusion becomes dry and ulcerated, and there is frequently rupture followed by closure of the opening; this process may be repeated a number of times, until the eye is lost and a *shrunken globe* remains.

FIG. 144.—Staphyloma of the Cornea.

Even before these secondary changes have taken place, there is considerable *deformity*, and *sight* is very much *reduced*. In total staphyloma there will be merely perception of light; in the partial form the amount of sight will depend upon the condition of the cornea which is preserved, the position of the pupil, and the extent to which the curvature of the cornea has become altered.

Treatment.—In *partial staphyloma*, an *iridectomy* should be performed (p. 211) for the purpose of reducing tension, flattening the protrusion and preventing its increase, and to serve for optical purposes. We select the part of the iris corresponding to the most clear portion of the cornea. If there is no anterior chamber and the iris lies against the posterior surface of the cornea, this operation is impossible. In such cases, we may *incise*, or *excise*, a portion and unite with sutures, followed by a pressure *bandage* for a considerable period of time.

In *total staphyloma*, we resort to incision, abscission, or enucleation. *Abscission* is performed by cutting off the protrusion with knife and scissors, removing the lens, and bringing together the edges of the corneal gap with sutures drawn through corneal tissue, or better, through the conjunctiva

which has previously been freed around the limbus. *Enucleation*, or one of its substitutes, is indicated in certain cases in which the staphyloma is very large, painful, or the source of danger to the other eye.

Keratectasia is a protrusion following inflammation of the cornea without perforation; the bulging portion is opaque. It may follow thinning from an ulcer which has not perforated or it may be due to softening of the cornea after pannus and interstitial keratitis. There is always marked reduction of vision. When fully developed, treatment is of no avail.



FIG. 145.—Keratoconus.

Keratoconus or Conical Cornea.—A non-inflammatory *conical protrusion* of the centre of the cornea (Fig. 145), due to a gradual *atrophic thinning*, in consequence of which the cornea is unable to resist the normal intraocular pressure. The condition is of *infrequent* occurrence, usually bilateral, and begins to develop in young adults. It is easily seen when well marked by looking at the eye from the side; when less developed, it is recognized by the shadow-test, by distortion of the picture of the fundus with the ophthalmoscope, and by the alteration in shape of the image when Placido's disc (Fig. 6) is used. The condition tends to *progress* for many years before it comes to a standstill. It sometimes presents a slight opacity at its apex; it never ulcerates. Conical cornea causes myopia and astigmatism and seriously *interferes with sight*, even after the best possible correction with glasses. Treatment consists in providing concave *spherocylinders*, repeated paracentesis followed by the long-continued application of a pressure bandage, pilocarpine or eserine to diminish

FIG. 146.—Corneal Electrode for Keratoconus.

tension, and abscission or *cauterization* of the apex of the cone to cause flattening by subsequent cicatrization.

Cauterization is used most frequently and is moderately successful; it is generally followed by an iridectomy for the purpose of bringing the pupil opposite clear cornea. The electrode used for this operation (Fig. 146) has a spherical tip with which the apex of the cone is cauterized as deeply as Descemet's membrane, or even with perforation.

Keratoglobus is a globular protrusion and enlargement of the cornea which, although occasionally met with under other circumstances, is usually one of the manifestations of congenital glaucoma and is described under this title (p. 218).

OPACITIES OF THE CORNEA

This term refers to a lack of transparency of the cornea resulting from inflammation, ulceration, or injury. According to density, the corneal opacity is called *nebula* (Fig. 147), when faint and cloud-like, often overlooked until examined by oblique illumination; *macula* (Fig. 148), when more pronounced and appreciable as a gray spot in daylight; *leucoma* (Fig. 149), when dense and white. When the iris is attached to the scar tissue, the condition is spoken of as *adherent leucoma* (Fig. 137, Plate X).

Opacities of the cornea interfere with perfect vision when they involve or encroach upon the pupillary area, the degree



FIG. 147.—Corneal Nebula.

FIG. 148.—Corneal Macula.

FIG. 149.—Corneal Leucoma.

depending upon their density. Even slight opacities cause considerable *visual disturbance* on account of the resulting diffusion of light. Denser opacities cause *disfigurement.*

Treatment.—Various measures are used to reduce the density of corneal opacities, or, if faint, to cause their disappearance. These are of value only when the opacity is *recent* (less than one year); they act most successfully in children and when the change is superficial. Most commonly the ointment of the *yellow oxide of mercury* is placed in the conjunctival sac, after which the cornea is *massaged* for a few minutes, and then *hot compresses* are applied. *Dionine*, thiosinamin, diluted tincture of opium, and other *irritants* are used for this purpose. Galvanism has given good results. Transplantation of the cornea usually fails to give any but temporary improvement.



FIG. 150.—Tyson Tattooing-Needles.

FIG. 151.—Grooved Tattooing-Needle.

When such measures are unsuccessful, and the leucoma entirely occludes the pupillary area, iridectomy for *artificial pupil* (p. 215) may be performed, the coloboma being made opposite a clear part of the cornea.

To remove the disfigurement in cases of leucoma, *tattooing* is often resorted to. The eye is anæsthetized, and the leucoma covered with a thick paste of India ink; the pigment is then introduced obliquely into the corneal substance, either by means of an instrument consisting of a row or bundle of round needles (Fig. 150) or with a grooved needle (Fig. 151). The color fades in the course of a few years and then the operation may be repeated. When the opacity covers only a part of the pupillary area, tattooing is useful in preventing the diffusion of light which is so annoying to the patient. The operation is contraindicated when the cornea is very thin or when likely to increase intraocular disease by irritation.

INJURIES OF THE CORNEA

These comprise foreign bodies, burns, and wounds.

Foreign Bodies, consisting of iron, coal, ashes, dust, etc., frequently adhere or become embedded in the cornea, causing

much pain, lacrymation, and photophobia. When the foreign body is small, it may be difficult to detect, unless we make use of oblique illumination. The mischief which a foreign body provokes depends upon the *depth* to which it penetrates and whether or not it is *infected.* If present for a number of days, a surrounding area of *infiltration* appears, resulting in a small ulcer, and in this manner the foreign body may become dislodged; if it consists of iron or steel, this ring will become stained by rust. Foreign bodies are sometimes the cause of ulcers of the cornea.

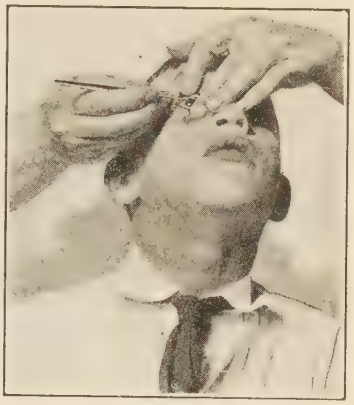

FIG. 152.—Method of Removing a Foreign Body from the Cornea (Surgeon Standing Behind the Patient).

To Remove a Foreign Body.—The eye is holocainized; the patient is seated facing a good light with the surgeon standing behind and supporting the head; the lids are separated and the eyeball is steadied by the fingers of the left hand; the index finger is applied to the margin of the upper lid and the middle finger to the lower lid, and the two fingers are separated, at the same time gently pressing backward (Fig. 152). If the patient is seated in a chair provided with a suitable head-rest, the surgeon may stand in front; under such circumstances, the index finger is applied to the lower lid and the middle finger to the upper (Fig. 153).

The *instruments* used are either the blunt spud, the gouge, or the foreign-body needle (Figs. 154–156); these should be *sterilized* before use.

When the foreign body is superficial, the *blunt spud* will answer; very often the particle can be removed with a little *absorbent cotton* wound around the end of the spud. When

it has penetrated into the corneal substance, it must be *picked* or dug out with the *gouge*, or the *needle;* in such cases, the instrument is passed *behind* the foreign body. The wound which results must be kept *clean* by frequent irrigation with solution of boric acid and the use of bichloride ointment 1:3000; frequently homatropine and a protective bandage are indicated. If a ring of *rust* is present, this must be removed. Care must be taken to inflict *as little injury as possible*, and when the foreign body is deep, *not to perforate the cornea.* If deep in the cornea, a narrow keratome (Fig. 193) may have to be passed through the cornea and behind the foreign body, so that the latter will not be pushed into the anterior chamber during efforts at removal.

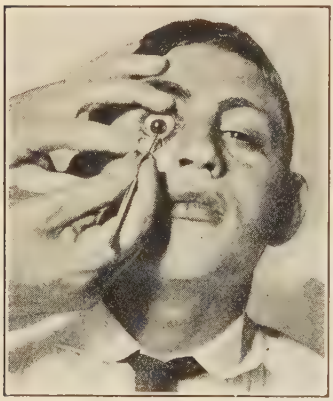

FIG. 153.—Method of Removing a Foreign Body from the Cornea (Surgeon Standing in Front of the Patient).

Burns of the cornea are treated like similar conditions of the conjunctiva (p. 132).

Wounds may be non-penetrating or penetrating. *Non-penetrating* wounds are most commonly abrasions due to scratches with the finger nail, twig of a tree, or the like. Such injuries, though very *painful*, heal readily unless infected; they should be kept clean by frequent *irrigation* with solution of boric acid; a *bandage* may be indicated, and sometimes atropine or homatropine.

FIG. 154.—Foreign-Body Spud.

FIG. 155.—Foreign-Body Gouge.

FIG. 156.—Foreign-Body Needle.

Perforating Wounds are more *serious* owing to the danger

of prolapse of the iris and injury to the deeper parts. They should be treated by thorough *cleansing*, bichloride ointment 1:3000, *atropine* or eserine according as they are central or peripheral, and a *bandage*. An attempt should be made to *replace* the iris, if prolapsed; if this is unsuccessful, as is usually the case, the prolapsed portion should be *excised*. When considerable, it is often advisable to cover the corneal wound with a *conjunctival flap*. In penetrating wounds of the cornea the question of the entrance of a *foreign body* into the globe presents itself and then an X-ray examination is indicated. In very severe wounds of the cornea involving deeper parts enucleation must be considered.

CHAPTER IX

DISEASES OF THE SCLERA

Anatomy.—The *sclerotic* coat (sclera) is the tunic which with the cornea forms the external fibrous layer of the eyeball; it is strong, opaque, and inelastic, and serves to maintain the form of the globe. Its thickness is about 1 mm., but varies at different points. Its structure resembles that of the cornea, being composed of bundles of *connective tissue* with some elastic fibres, disposed in both longitudinal and transverse layers, between which are a few flat cells; these parts are, however, much less regularly arranged than in the cornea. Anteriorly, the structure of the sclera is continuous with that of the cornea. In the child, the sclera often has a bluish-white color, owing to its being thinner and allowing the dark pigment of the choroid to show through. The sclera is pierced about 2.5 mm. internal to the posterior pole of the eye by the optic nerve; here it has blended with it the external fibrous sheath of the nerve. The part through which the nerve passes is known as the *lamina cribrosa.*

The outer surface of the sclera is white and smooth, covered by *Tenon's capsule* and the conjunctiva, to which it is joined by *loose connective tissue* (*episcleral*); in front, it presents the insertions of the extrinsic muscles of the eyeball. Its inner surface is brown and rough, being covered by delicate, pigmented connective tissue, which is united to the choroid by filaments traversing the lymph space existing between the sclera and choroid; where it is pierced by vessels and nerves, a communication between the capsule of Tenon and the suprachoroidea is established. The points of emergence of the anterior ciliary veins are often marked by small brown dots; and the anterior portion of the sclera sometimes presents slate-colored or violet spots of pigmentation, especially in negroes. Though traversed by many blood-vessels, the sclera itself has a very scant vascular supply; but the episcleral tissue contains numerous vessels

Affections of the Sclera include superficial inflammation (episcleritis), deep inflammation (scleritis), staphyloma, and injuries.

Inflammation of the Sclera (Scleritis) may be either superficial or deep. The *superficial* form, called *episcleritis,* is lim-

ited to the tissues superficial to the sclera and is relatively harmless. The *deep* form, known as *scleritis*, involves the sclera itself and extends to subjacent and contiguous parts, causing serious consequences. There is often an absence of a sharp line of division between the two forms.

EPISCLERITIS

An inflammation of the *episcleral tissue.*

Symptoms.—There are usually slight *discomfort*, lacrymation, and pain, but occasionally there are more marked symptoms of irritation. A slightly raised patch of red or purple color is seen in the ciliary region (Fig. 126, Plate IX), usually on the temporal side, presenting both conjunctival and episcleral congestion, and more or less tender on pressure. After a few weeks, the node will disappear; but others are apt to take its place; in this way the process may encircle the cornea. Owing to this tendency to *relapses*, the disease often lasts many months. Sometimes some discoloration of the sclera remains; occasionally the cornea and iris are implicated. The disease may resemble a marked case of *phlyctenular conjunctivitis;* it may merge gradually into *scleritis.*

Etiology.—It is usually observed in *adults*, especially in women; often in *rheumatic* and gouty individuals. Syphilis, tuberculosis, and menstrual disorders are predisposing factors.

Treatment should be of a *sedative* nature: *Warm* compresses and warm boric-acid solution; if the cornea or iris is implicated, atropine. The occasional instillation of 1-per-cent. solution of *holocain* in 10,000 *adrenalin* will relieve the discomfort. *Dionine* may prove useful. The ointment of the yellow oxide of mercury (1 per cent.), applied with gentle massage, and the subconjunctival injection of physiological salt solution are sometimes of value, especially when the disease shows a tendency to become obstinate. Instillations of 2-per-cent. homatropine with 1-per-cent. holocaine are of value. With or without a rheumatic or gouty history, *sodium*

salicylate and *aspirin* are useful. *Iodide* of potassium may be tried, also diaphoresis. Hypodermic injections of *tuberculin* are often effective in patients who show a local reaction to the diagnostic tuberculin test (p. 409).

Transient Periodic Episcleritis is a variety of episcleritis which appears in sudden attacks lasting several days, reappears at intervals of several weeks or months, and may recur for years. It is seen in gouty and rheumatic adults. The treatment is that recommended for episcleritis.

SCLERITIS

An inflammation of the sclera, in which the symptoms are *acute*, the course is *prolonged*, and the consequences are *serious*. In this disease the sclera itself is involved in the inflammatory process; it becomes *softened*, thinned, and *staphyloma* results. Both eyes are frequently involved. *Relapses* are very common.

Symptoms.—*Pain*, usually severe, and frequently radiating to neighboring regions, *tenderness* over ciliary region, lacrymation, and photophobia. The *tension* of the eyeball is frequently increased; secondary glaucoma often ensues.

There are well-marked dark-red or *violet patches* adjacent to the cornea, often extending to the equator, and frequently surrounding the limbus; in some cases, small, white, hard nodules develop in the inflamed area beneath the conjunctiva. After subsidence of the inflammation the seat of the affected areas is often marked by pale-violet discoloration.

Complications.—The *cornea* is frequently implicated and sclerosing keratitis (p. 149) follows. Often there are *iritis*, cyclitis, choroiditis, opacities of the vitreous, and secondary glaucoma; the combination of such complications is known as *anterior uveitis*. As a result of these changes, vision is often seriously interfered with and sometimes lost. The thinning of the sclera results in *staphyloma* of the anterior portion of the globe and causes myopia.

Etiology.—The disease is most common in *young adults*, and

especially in women. *Rheumatism* and gout, syphilis, *tuberculosis*, and disorders of menstruation are predisposing factors. Exposure to cold is sometimes the exciting cause.

Treatment comprises the measures advocated in episcleritis, energetically applied. In addition, the complicating keratitis and iritis require appropriate treatment. Tuberculin injections are effective in some cases. After the acute symptoms have subsided, an iridectomy is sometimes advisable for diminishing glaucomatous tension, preventing an increase in the staphyloma, and establishing an artificial pupil.

STAPHYLOMA OF THE SCLERA

A *thinning and bulging* of the sclerotic which, when partial, occurs either at the anterior portion, the equator, or the posterior portion of the eyeball; when total it involves the entire globe (congenital glaucoma, p. 218).

Anterior and Equatorial Staphylomata are caused by disturbed relation between the resistance of the sclera and the intraocular tension; such conditions are found after chronic glaucoma, iridocyclitis, ectasia of the cornea, scleritis, and injuries of the sclera. They present a *bluish-gray* bulging which may be limited or may extend all around the cornea (Fig. 157). This bulging shows a tendency to increase; occasionally it bursts. *Iridectomy*, if feasible, is the only treatment, and is done for the purpose of arresting the process. In some cases, when the enlarged eyeball causes much discomfort and is sightless, enucleation or evisceration is advisable.

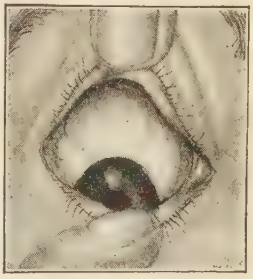

FIG. 157.—Anterior Staphylomata of the Sclera.

Posterior Staphyloma, situated at the posterior pole of the eyeball, is of common occurrence and is generally associated with myopia and choroiditis (p. 185). It is seen with the

ophthalmoscope, presenting a white crescentic or irregular patch which embraces the temporal side of the optic disc (Fig. 174, Plate XIII, and Fig. 177, Plate XIV).

INJURIES OF THE SCLERA

The important injuries include *perforating wounds* and *rupture;* these are *serious* on account of the danger of injury to the inner layers, escape of the contents of the eyeball, and infection of the interior.

Small, clean, perforating wounds often heal without reaction, if there is no infection at the time of the injury, and require merely *cleansing*, conjunctival *suture*, and a *bandage.*

Large, gaping wounds frequently allow escape of the *vitreous;* in addition there will be hemorrhage in the vitreous, diminished tension, and some of the underlying tissues (choroid, ciliary body, or iris) varying with the position, will be found in the wound. Such wounds should be *cleansed*, the *prolapsed parts returned* when not too seriously injured, the opening *closed* by sutures in the sclera (being careful to avoid the choroid) or preferably through the conjunctiva, the patient kept absolutely *quiet*, and the eye *bandaged.*

Sometimes such wounds fail to excite much inflammatory reaction and may heal readily, even though there is incarceration of the prolapsed parts in the scar. But frequently they give rise to *panophthalmitis* with ultimate phthisis bulbi, or to plastic *iridocyclitis* with loss of sight. When the wound involves the ciliary body, iridocyclitis is apt to be set up, and the injury becomes more dangerous on account of the liability of such wounds to excite sympathetic ophthalmitis.

Ruptures of the sclera are produced by blows and blunt instruments; they usually occur near the corneal margin, generally above and internally. The conjunctiva may not be broken. The prognosis is unfavorable and most of such eyes are lost, since, with force sufficient to rupture the sclera, there are usually serious lesions in the interior of the eye, such as

separation of the iris, dislocation of the lens, detachment of the retina, and hemorrhage into the vitreous.

When injuries of the sclerotic are *very extensive* and cause considerable loss of contents of the eyeball, and when we believe that useful sight cannot be hoped for, the eyeball should be *removed* at once. This becomes still more urgent when the wound involves the dangerous zone, the ciliary region.

In every case of perforating wound of the sclera we must be careful to ascertain the presence or absence of a foreign body within the globe. The presence of a *foreign body* in the eye is a serious complication. The attempt should be made to extract the particle, as described on p. 224.

CHAPTER X

DISEASES OF THE IRIS

Anatomy and Physiology.—The second or vascular coat of the eye (*uvea or uveal tract*) lies immediately beneath the sclera; it provides for the nourishment of the eyeball, and it is formed of three parts, which from before backward are known as the *iris*, the *ciliary body*, and the *choroid*. These three portions are so *intimately associated* that when one part becomes diseased, the others frequently participate.

The Iris is a colored membrane, circular in form, hanging behind the cornea immediately in front of the lens, and perforated in its centre by an aperture of variable size, the *pupil;* it serves to regulate the amount of light admitted to the interior of the eye, and cuts off the marginal rays which would interfere with the sharpness of the retinal image. Its peripheral border springs from the head of the ciliary body and the ligamentum pectinatum. Its free inner edge, the boundary of the pupil, lies upon the anterior capsule of the lens when the pupil is contracted or moderately dilated; with maximum dilatation it hangs free in the anterior chamber. The iris separates the *anterior* from the *posterior chamber* of the eyeball. Its anterior surface presents great variation in *color* in different eyes, and is marked by radially directed, wavy lines, converging toward the circle of irregular elevations and small depressions (crypts) situated near the pupil; other finer lines are seen extending from this ring to the pupil; this appearance is produced by the subjacent blood-vessels.

In *structure*, the iris consists of a delicate, spongy connective-tissue stroma, containing branched pigmented cells, muscular fibres, and an abundance of vessels and nerves. It is covered anteriorly by endothelium except at the crypts, where the stroma of the blood-vessel layer communicates directly with the anterior chamber—an arrangement which permits rapid exchange of aqueous from iris to anterior chamber and *vice versa;* posteriorly it presents the posterior limiting membrane and the retinal pigment layers.

The *color* of the iris depends partly upon the pigment in the stroma cells, which is variable, and partly on that in the cells of the retinal layers, which is constant.

The muscle tissue consists of (1) the *sphincter pupillæ*, a narrow band, about one millimeter wide, situated close to and encircling the pupil posteriorly, and supplied by the *third nerve*, and (2) the *dilatator pupillæ*, an epithelial muscle, consisting of long spindle-shaped cells arranged meridionally, which extends along the posterior surface of the blood-vessel layer from the sphincter pupillæ to the root of the iris and is supplied by the *sympathetic*.

The *posterior surface* of the iris is covered by two strata of pigmented cells, the uveal layer, which extends to the free border around which it turns a little, forming the black fringe of the pupillary margin.

The *vessels* of the iris come from the two branches of the ophthalmic known as the long posterior ciliary arteries; each artery divides into an upper and a lower branch; these anastomose with the corresponding vessels of the opposite side and with the anterior ciliary, and form a vascular ring just behind the attached margin of the iris, the greater vascular circle of the iris. This gives off branches to the ciliary body and iris; the iris branches converge toward the pupil and here form by anastomosis a smaller vascular circle, the lesser vascular circle of the iris. The veins of the iris follow the arrangement of arteries just described; in addition they communicate with the canal of Schlemm; they chiefly pass backward to the venæ vorticosæ.

The *nerves* are given off from the plexus in the ciliary body, and are derived from the third, the nasal branch of the ophthalmic, and the sympathetic.

Pupillary Membrane.—In the fœtus the pupil is closed by a thin, transparent delicate membrane—the pupillary membrane. The membrane and its vessels are gradually absorbed in the seventh or eighth month of fœtal life. A few shreds may remain at birth; occasionally a small part of the membrane persists (persistent pupillary membrane).

IRITIS

Inflammation of the iris is so frequently associated with inflammation of the ciliary body (cyclitis), that most cases which are designated *iritis* are really examples of *iridocyclitis*. It will be convenient, however, to describe the two affections separately.

Varieties: Iritis may be divided into *primary*, when developing in the iris itself, and *secondary*, when the inflammation spreads from neighboring parts, such as the cornea.

According to its course, it may be *acute* or *chronic*.

Depending upon its *etiology*, it may be classified as (1) Syphilitic, (2) Rheumatic, (3) Gouty, (4) Gonorrhœal, (5) from Septic Infection, (6) Diabetic, (7) Scrofulous, (8) Tuberculous, (9) Traumatic, (10) Sympathetic, and (11) Idiopathic.

Iritis has also been divided according to the nature of the products of inflammation into plastic, serous, spongy, purulent, nodular, etc.; but this classification is unsatisfactory because one type merges into the other.

It will be advisable to consider *Iritis in General*, and then

to mention the peculiarities of the different forms which have been named according to their etiology.

Objective Symptoms (Figs. 160, 161, 162, Plate XI).—The iris looks altered. It appears *swollen, dull,* loses its lustre, its markings become indistinct, its *color changes* and becomes greenish in blue or gray irides, and muddy in darker varieties. These changes are due to congestion of the iris and exudation of cells and fibrin into its substance; also to exudation into the anterior chamber.

FIG. 158.—Posterior Synechiæ Causing Irregular Pupil in Iritis.

The *pupil* is *contracted, grayish, sluggish* in action, and *irregular* (Fig. 158); the last peculiarity is due to adhesions between the posterior surface of the iris and the anterior capsule of the lens (*posterior synechiæ*), best seen after the instillation of atropine.

The contents of the aqueous chamber show changes; there is frequently *turbidity;* there may be more or less dust-like *deposit* on Descemet's membrane (so-called *keratitis punctata*), which often involves the lower part (Fig. 162, Plate XI) or may give a cloudy appearance to the entire cornea. In this exudation there may be *pus* which then gravitates to the bottom (*hypopyon*) or *fibrin*, which coagulates into a grayish mass (*spongy iritis*), or *blood* (*hyphæma*). The anterior chamber may be deeper than normal. The tension of the eyeball, though usually normal, may be increased or diminished.

The anterior capsule of the lens may present evidences of exudation, and also small spots of uveal pigment where posterior synechiæ have been torn away.

There is always marked circumcorneal *injection,* and with this pink zone there may be more or less conjunctival congestion.

Subjective Symptoms consist of *pain, photophobia, lacrymation, interference with vision,* and sometimes general malaise.

FIG. 159.—Normal Eye (for Comparison).

FIG. 160. Iritis.

FIG. 161.—Syphilitic Iritis.

FIG. 162. -Serous Iridocyclitis.

FIG. 163.—Panophthalmitis.

FIG. 164.—Panophthalmitis.

Figs. 159-164. Iritis. Iridocyclitis. Panophthalmitis

The *pain* is often severe, referred to the eyeball itself and radiating to the forehead and temple, and worse at night. It is sometimes accompanied by *tenderness* of the eyeball, a symptom pointing to involvement of the ciliary body.

The diminution in the acuteness of vision depends upon cloudiness of the anterior chamber, deposits in the pupil and upon Descemet's membrane, and upon transient myopia and astigmatism. When very marked, it indicates extension of the inflammation to the deeper parts.

Differential Diagnosis.—Iritis is most frequently mistaken for acute catarrhal *conjunctivitis*. Sometimes *acute glaucoma* is mistaken for iritis. The differential points are given in the following tables:

Acute Iritis.	*Acute Conjunctivitis.*	*Acute Glaucoma.*
1. Iris swollen, dull, and discolored.	1. No change in iris.	1. Iris congested, discolored, dull, periphery pushed forward.
2. Pupil small, gray, sluggish, irregular after use of atropine.	2. Pupil normal.	2. Pupil dilated, oval, immobile.
3. Anterior chamber of normal depth (deeper in serous form) and presents exudation.	3. Anterior chamber normal.	3. Anterior chamber shallow and aqueous sometimes turbid.
4. Cornea transparent (may present deposits on posterior surface) and sensitive.	4. Cornea transparent.	4. Cornea steamy and insensitive.
5. Ciliary (circumcorneal) injection; pink zone of fine vessels surrounding cornea and fading toward fornix.	5. Conjunctival injection, coarse meshes, most pronounced in fornix and fading toward the cornea.	5. Ciliary and episcleral injection (also conjunctival congestion).
6. Conjunctiva usually transparent.	6. Conjunctiva reddened and opaque.	6. Conjunctiva congested and chemotic.
7. Lacrymation but no discharge.	7. Mucous or mucopurulent discharge.	7. Lacrymation but no discharge.
8. Tension usually normal (occasionally altered).	8. Tension normal.	8. Tension increased.
9. Some ciliary tenderness.	9. No ciliary tenderness.	9. Ciliary tenderness.
10. Pain radiating to forehead and temple, worse at night.	10. Discomfort, hot gritty feeling, but no real pain.	10. Severe pain in and about eye, with headache.
11. Dimness of vision.	11. No interference with vision, except blurring caused by the discharge smeared over the surface of the cornea.	11. Marked dimness of vision.

Course.—Iritis may be *acute* and run its course in several weeks; or it may be *chronic* and last a number of months. A great many cases terminate *favorably*, especially when subjected to proper treatment early; the exudation becomes absorbed, and the iris returns to a normal condition with no

evidences or mere traces of former inflammation. On the other hand, *serious complications* and disastrous sequelæ may arise; hence the prognosis should be guarded. Chronic cases present very mild inflammatory symptoms, or the latter may be entirely absent. Certain forms of iritis have a tendency to recur (*recurrent iritis*). Iritis may involve *one* or *both eyes;* when both eyes are attacked, the second usually is affected a short time after the first.

Complications.—The neighboring parts of the eye are sometimes involved in severe forms of iritis: conjunctiva, cornea,

FIG. 165.—Section of the Anterior Portion of the Eyeball showing the Iris in its Normal Relations.

FIG. 166.—Section showing Annular Posterior Synechia (Exclusion of the Pupil.)

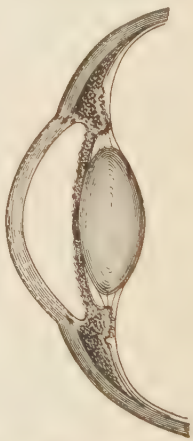

FIG. 167.—Section showing Total Posterior Synechia and Occlusion of the Pupil.

ciliary body, choroid, vitreous, optic nerve, and retina. As already mentioned, the association of inflammation of the ciliary body (*cyclitis*) with iritis (*iridocyclitis*) is so common, that some authors describe the two conditions together and regard pure iritis as rare. The following symptoms, occurring in the course of an iritis, point to the *existence of cyclitis:* Violent inflammatory symptoms, including swelling of the upper lid; marked diminution in vision when greater than can be explained from visible opacities; tenderness in the ciliary region; deposits upon the posterior surface of the

cornea and in the pupillary area and extensive synechiæ, indicating great exudation; increase or decrease of normal tension.

Sequelæ.—These are often *posterior synechiæ* and *deposits* upon the anterior lens capsule; less frequently there are exclusion of the pupil, occlusion of the pupil, atrophy of the iris, opacities of the vitreous, deposits upon the posterior capsule of the lens, and cataract. In *exclusion* (or seclusion) *of the pupil* (annular posterior synechia), the iris is bound down throughout its entire pupillary margin, the pupil remaining clear (Fig. 166); this causes a loss of communication between the anterior and the posterior chamber; the aqueous secreted by the ciliary processes is hemmed in, the iris stretched (*iris bombé*) and atrophied, *glaucoma* results, and, if unrelieved, blindness follows; if the whole posterior surface of the iris becomes adherent to the anterior capsule of the lens the condition is known as total posterior synechia. *Occlusion of the pupil* is a filling in of the pupillary space with opaque exudate (Fig. 167). Exclusion and occlusion of the pupil often occur together.

Etiology.—Primary iritis is frequently dependent upon some *constitutional disease:* very often *syphilis;* less frequently *rheumatism* and *gonorrhœa;* much less commonly the scrofulous diathesis, tuberculosis, gout, acute infectious diseases and diabetes. It is often a *local* affection and then not infrequently is due to *infection* from diseased *teeth, tonsils* or *nasal accessory sinuses;* it may be traumatic or sympathetic (from injury to the other eye). Many cases are called *idiopathic,* when we are ignorant of the cause.

Pathology.—Inflammation of the iris presents similar changes to those occurring in other connective tissue, modified by the great vascularity of this membrane and the looseness of its stroma. There are dilatation of the blood-vessels and exudation of lymph, lymphocytes, and fibrin into the stroma and anterior chamber. These products of inflammation may be completely absorbed, or may become organized into connective tissue, forming adhesions and causing degenerative changes in the iris.

Treatment.—(1) Atropine, (2) dionine, (3) leeches, (4) hot fomentations, (5) rest, (6) protection from light, (7) sweating, (8) treatment of etiological factor.

Fig. 168.—Artificial Leech.

Atropine (2%) diminishes congestion of the iris, puts this part at rest, causes mydriasis, and thus prevents adhesions and tends to break up those which have already formed. Sufficient should be instilled to keep the pupil widely dilated—every 2 hours at first, and later 3 or 4 times a day. When the inflammation is pronounced, the pupil will not dilate readily. The action of atropine is often increased by the addition of cocaine; the latter should not be used continuously. Occasionally, symptoms of *atropine poisoning* (p. 403) occur, either local or constitutional, necessitating the substitution of some other mydriatic (duboisine, hyoscyamine, scopolamine). Exceptionally atropine causes an increase in pain and must be stopped or replaced by a miotic; this action is apt to occur when there is increased tension, sometimes due to complicating cyclitis.

Dionine (5 to 10 per cent.) and *holocaine* (1 per cent.) act favorably upon the pain.

The abstraction of blood from the temple by means of 4 or more *leeches* or the artificial leech (Fig. 168) always has a favorable effect upon pain and other symptoms.

Moist, hot compresses for several hours each day diminish the pain and the inflammation. It is only in traumatic iritis that cold compresses may be of service for the first day or two.

Absolute rest in bed in the early stages, and *protection from light*, by means of smoked coquilles or a shaded room, are essential.

Other important indications are light diet, abstinence from alcoholics, a brisk *purge*, *sweating*, and avoidance of all use of the eyes for near work.

Constitutional Treatment must meet the indications in the different forms. In syphilitic iritis *mercury* is given, usually by inunction, to the point of salivation; after acute symptoms have subsided, *mixed treatment* (mercury and iodide of potassium); an injection of *salvarsan* is followed by most gratifying improvement. In certain apparently idiopathic forms, small doses of mercury have a favorable effect. In rheumatic cases we prescribe large doses of *salicylate of sodium* or *aspirin;* these remedies also have a quieting effect upon the pain in other forms.

Paracentesis is occasionally done for the relief of continued high tension, and also in certain obstinate cases; *iridectomy* is sometimes performed for the same reasons. As a rule, however, operative procedures are useful only after the inflammatory symptoms have subsided, for the purpose of remedying sequelæ.

It remains to consider briefly the distinctive features of certain varieties of iritis.

Clinical Varieties.—*Syphilitic Iritis* is the most *common* form. It occurs in the *secondary* stage of acquired syphilis, usually during the first year after infection; it is usually *acute;* both eyes are attacked, the second soon after its fellow. In some cases there are no characteristic symptoms distinguishing this from other forms of iritis, though there are always apt to be broad and thick synechiæ (plastic), and pain is often insignificant. In other cases there are *yellowish-red nodules* of the size of a pin's head or larger (Fig. 161, Plate XI), usually multiple, situated upon the pupillary or ciliary border (iritis papulosa). There is often accompanying disease of the posterior portion of the eyeball (choroid, retina, and optic nerve). If properly treated relapses are not common. Infrequently, syphilitic iritis is seen in childhood as a result of inherited syphilis, being then usually associated with interstitial keratitis; rarely, the iris is the seat of a gumma in the tertiary stage.

Rheumatic Iritis is usually *acute;* it is frequently unilateral, though sometimes it attacks both eyes; it occurs especially in adults; the exudation is usually plastic with narrow adhe-

sions; *pain* is pronounced; *relapses* are common. It is not usually found with acute rheumatism, being associated with the more chronic manifestations of this diathesis.

Gouty Iritis is uncommon and like the rheumatic form.

Gonorrhœal Iritis is much more *common* than is generally supposed; many cases called rheumatic are really gonorrhœal. It occurs after gonorrhœa, usually subsequent to an attack of arthritis, and depends upon the influence of the gonococci or their toxins in the circulation upon the iris. It resembles the rheumatic form; the exudate is plastic, pain is pronounced, and relapses common. Besides treatment applicable to all forms of iritis and the use of salicylates and aspirin, injections of gonococcic vaccine are indicated and often valuable.

Iritis from Septic Infection from the teeth (pyorrhœa and periapical abscess), tonsils, nose or nasal accessory sinuses is *common;* an examination of these parts by inspection, transillumination and satisfactory radiographs, ought never to be omitted.

Diabetic Iritis occurs sometimes in diabetes, is plastic in character, chronic in course, and may be accompanied by hemorrhage into the anterior chamber.

Scrofulus Iritis is the name given to an uncommon form which occurs in scrofulous children and young adults, resembling the iritis due to inherited syphilis; sometimes it presents a mass of lardaceous exudate.

Tuberculous Iritis is a rather rare form which occurs in children and young adults, either with or without tuberculosis of other parts. It appears under two forms: (1) the miliary, in which small grayish-yellow nodules develop near the pupillary or ciliary border, and (2) the conglomerate form in which a single yellowish-gray mass is found in the ciliary part of the iris; with these there will be more or less evidence of plastic iritis. In mild cases, the tuberculous deposits may be completely absorbed; in others the process leads to destruction of the eyeball. Treatment comprises the usual management of iritis and tuberculosis, and injections of tuberculin; in unfavorable cases in which sight is lost, enucleation is advisable to prevent extension of the tuberculous process.

Traumatic Iritis occurs as a result of accidental injury or an operation wound; the course depends upon whether infection takes place.

Sympathetic Iritis is merely part of Sympathetic Ophthalmitis (p. 188).

Tumors of the Iris may be (1) *inflammatory: a*, syphilitic, *b*, tuberculous, both of which have just been described; and (2) *new growths:* cysts, melanoma, and sarcoma, all of which are rare.

FIG. 169.—Iridodialysis.

Injuries of the Iris may be (1) non-perforating and (2) perforating.

(1) *Non-perforating injuries* (concussion, blows upon the eyeball) may cause (a) *mydriasis* (as a result of paralysis of the sphincter of the iris, iridoplegia), (b) a *tear* in the pupillary margin, in both of these cases eserine being indicated; (c) *iridodialysis*, a separation of the ciliary border of the iris (Fig. 169), for which atropine is required. When the iris is torn, either at the pupillary or the ciliary border, there will be blood in the anterior chamber (hyphæma).

(2) *Perforating injuries* are often complicated by wounds of the lens and other parts of the eye. They may lacerate the iris or merely allow it to project through a wound of the cornea or ciliary region (*prolapse*). In cases of prolapse, the wound must be irrigated with a mild cleansing lotion; if seen within a few hours, and there is no injury to iris and lens, and the wound appears to be a clean one, the iris may be returned into the anterior chamber, atropine or eserine used according to the seat of the perforation, and a bandage applied. If the iris has been injured, or the patient is not seen until some time after the injury, the prolapsed portion should be excised, the cut edges carefully separated from the wound by a spatula, atropine or eserine used according to the seat of the injury, and the eye bandaged.

A *foreign body* may pass through the cornea and lodge upon the iris; in such a case, the particle should be removed by forceps after a preliminary incision with the lance-shaped knife at the limbus; if composed of iron or steel it may be drawn out with a magnet. If these efforts are unsuccessful, the piece of iris upon which the foreign body lies should be drawn through the wound and excised.

Operations upon the Iris.—*Iridectomy* is the most important operation upon the iris. It is described with glaucoma (p. 209), which forms its most frequent indication.

Iridotomy, the formation of an *artificial pupil*, is indicated in cases in which, after loss of the lens following injury or cataract operation, the pupil has been closed by inflammation or been drawn toward the cicatrix. The iris-membrane is cut transversely with a Graefe knife or a knife-needle; or with special forceps-scissors introduced through a small corneal incision; or a V-shaped incision may be made with a knife-needle, apex superiorly, forming a flap which falls down or is pushed down behind the lower part of the iris-membrane.

THE PUPIL

The normal pupil is circular and regular in outline. It is larger in the young than in advanced life. Its size should equal that of its fellow; both should respond alike when one is subjected to a change in intensity of illumination. The movements of the pupil are contraction and dilatation.

The contracting fibres of the iris (*sphincter pupillæ*) are supplied by the *third nerve*. The dilating fibres (*dilatator pupillæ*) are supplied by the *sympathetic*. Changes in the size of the pupil also depend upon variations in the calibre of its *blood-vessels*, which are also supplied by the sympathetic.

Contraction of the pupil is effected by stimulation of the oculomotor nerve and by paralysis of the sympathetic. *Dilatation* follows paralysis of the third nerve or stimulation of the sympathetic.

The *oculomotor-nerve fibres* are conveyed through the ciliary ganglion and short ciliary nerves. The nucleus of origin of the third nerve concerned in the movements of the iris is in

the floor of the aqueduct of Sylvius, and can be divided into three portions: (1) that giving rise to the sphincter fibres of the *iris*, (2) *accommodation* (ciliary muscle), and (3) *convergence* (internal rectus). The *sympathetic or dilating fibres* are given off from the cilio-spinal centre of the lower cervical spinal cord.

The *pupil contracts* upon exposure to light, with accommodation, and with convergence. The light contraction may be direct or consensual. The *direct light reflex* is obtained by exposing one eye to increased illumination and observing the contraction of the pupil of this eye. The *consensual or indirect light reflex* is obtained by throwing light into one eye and observing the contraction of the pupil of the other eye. The direct and consensual reactions are practically equal. The *accommodation and convergence reflex* is obtained by directing the patient to look at an object held several inches in front of the face in the middle line; the pupils will be seen to contract. These three actions are *associated.*

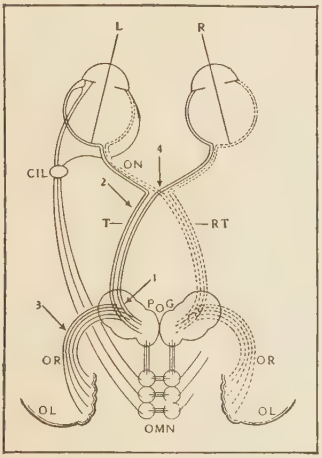

FIG. 170.—Visual and Pupillary Reflex Paths. *L*, Left eye; *R*, right eye; *ON*, optic nerve; *LT*, left optic tract; *RT*, right optic tract; *POG*, primary optic ganglia; *OMN*, oculomotor nuclei; *OR*, optic radiations; *OL*, occipital lobe; *CIL*, ciliary ganglion. Division of the fibres at 1 abolishes the reaction of the pupil to light upon illuminating the left half of either retina. At 2, the same result with right homonymous hemiopia. At 3 right homonymous hemiopia with preservation of the reaction of the pupil to light.

The *dilatation reflexes* of the pupil are seen upon shading the eye (both direct and consensual), and upon looking at a distant object. In addition there is a *sensory reflex:* when sensory nerves are stimulated, as by scratching or tickling the skin, both pupils dilate.

The consensual contraction is explained by the fact that the light stimulus in one eye is carried by the optic nerve and

passes to both optic tracts and in this way to the nucleus of the third nerve of each side (Fig. 170). Blindness in one eye abolishes the direct reflex in this eye, but its consensual reflex is preserved.

In certain pathological conditions, there may be loss of light reflex, without interference with sight; this is seen, for example, in paralysis of the iris as a result of the use of a mydriatic or in oculo-motor paralysis. The *Argyll-Robertson pupil* (reflex iridoplegia), so frequently a symptom of locomotor ataxia, contracts with accommodation and convergence, but does not respond to light; it is usually accompanied by miosis; it is explained by an interruption in the path from the optic nerve to the oculo-motor nucleus, the connections of the centres for accommodation and convergence remaining unaffected.

The characteristics of the pupils—size, equality, and reflexes, are of great value in the diagnosis of various affections of the nervous system and in the localization of cerebral lesions. Hence it is important to be familiar with the afferent and efferent routes which control the movements of the pupil (Fig. 170, and Plate XXII).

The course of the *afferent impulse* is retina, optic nerve, both optic tracts, corpus quadrigeminum, nuclei of origin of the third nerve in the floor of aqueduct of Sylvius (there being a communication between the two sides). The *efferent impulse* travels on either side from these nuclei to the third nerve, the ciliary ganglion, short ciliary nerves, to the iris.

Mydriatics and Miotics are described on pages 349 and 402.

The *hemiopic pupillary reflex* is explained on page 291.

CHAPTER XI

DISEASES OF THE CILIARY BODY

Anatomy.—The ciliary body is that part of the tunica vasculosa which extends backward from the base of the iris to the anterior part of the choroid; it consists of the *ciliary processes* and of the *ciliary muscle*. A longitudinal section is of triangular shape, with a narrow base directed forward, giving origin to the iris. The outer side of the triangle is formed by the ciliary muscle; the inner side can be divided into two parts: an anterior, which bears the ciliary processes, and a posterior portion, which is smooth.

The ciliary muscle (the muscle of *accommodation*) consists of non-striated muscular fibres arranged in bundles, anastomosing with one another frequently so as to form a sort of plexus, and running in three different directions—meridional, radiating, and annular. The proportion between circular and longitudinal fibres varies according to the refractive condition of the eye; the circular set is well developed in hyperopia (Fig. 304), but atrophied in myopia (Fig. 305). When the ciliary muscle contracts, it draws the ciliary processes and choroid forward and inward, thus relaxing the suspensory ligament and allowing the lens to become more convex.

The ciliary processes consist of about seventy folds or thickenings, arranged meridionally, so as to form a circle. They have the same structure as the rest of the choroid, but are even more vascular. They serve to *secrete the nutrient fluids* in the interior of the eye which nourish neighboring parts, especially the cornea, lens, and part of the vitreous. The inner surface of the ciliary body is covered by three layers: externally, a homogeneous membrane continuous with the posterior limiting membrance of the iris; next, pigment epithelium; internally, next to the vitreous, a layer of cylindrical non-pigmented cells.

The ciliary body is supplied by branches from the greater circle of the iris and by the anterior ciliary *arteries*. The *veins*, constituting the greater part of the ciliary processes, pass backward to the venæ vorticosæ of the choroid. A part of the veins from the ciliary muscle pass backward, pierce the sclera, and run beneath the conjunctiva with the anterior ciliary arteries. These constitute the violet subconjunctival vessels seen running backward in ciliary injection and in deeper congestion (glaucoma). They anastomose with the conjunctival veins, and communicate with Schlemm's canal. The ciliary body is richly supplied with *nerves*, especially the ciliary muscle in which there is a nerve plexus with ganglion cells.

CYCLITIS AND UVEITIS

As already pointed out, iritis is frequently associated with cyclitis (*iridocyclitis*). While unmixed cases of cyclitis do occur, they are uncommon; usually with inflammation of the ciliary body, adjacent portions of the uveal tract participate, and the disease becomes *an inflammation of the iris, ciliary body and choroid,* known as *uveitis.*

Practically, the term *iridocyclitis* is reserved for those cases in which, with the symptoms of iritis, there are decided evidences of participation of the ciliary body.

Varieties:—Cyclitis (Iridocyclitis) may be divided into (1) Acute; (2) Chronic or Uveitis—(a) Mild Type and (b) Severe Type; (3) Purulent; and (4) Sympathetic.

1. **Acute Iridocyclitis** presents the picture of acute iritis with the addition of the following *symptoms pointing to involvement of the ciliary body:*

Marked circumcorneal injection, tenderness in ciliary region, swelling of upper lid, turbidity of the aqueous (occasionally hypopyon or hyphæma), increased depth of anterior chamber, deposits upon Descemet's membrane, abnormal tension (increase or decrease), and greatly reduced vision (due to vitreous opacities and deposits in the pupillary space).

Symptoms:—Those of iritis plus the ones just given.

Prognosis *varies* but is always serious. Although the disease may run a comparatively mild course and the eye recover with little injury, marked ciliary participation adds to the severity of symptoms and seriousness of prognosis; the outcome may be more or less *reduced vision;* the disease may cause blindness with atrophy of the globe.

Treatment is that of *iritis* (p. 170).

Chronic Iridocyclitis or Uveitis is an inflammation of the *entire uveal tract* (iris, ciliary body and choroid), occurs in young *adults,* is *chronic* in course, has a tendency to *relapse,* may involve one eye but often *both.* The severity of the inflammation varies and in this sense the disease is divided into *two types,* (a) *mild* and (b) *severe.*

Etiology:—Certain *constitutional* diseases: syphilis, gon-

orrhoea, tuberculosis, influenza, acute infective diseases, chronic rheumatism, gout, arthritis deformans and diabetes; *auto-intoxication* from the intestinal tract; not infrequently the toxins of bacterial origin (*focal infections*) from the gums and teeth (pyorrhœa, periapical abscess), tonsils, nose, nasal accessory sinuses, genito-urinary tract; or the *infective* agent may arise from *perforating wounds* of the eyeball, including operations such as cataract extraction.

Symptoms:—a. *The Mild Type* begins insiduously with few, if any, symptoms of irritation. The patient complains chiefly of *diminution of vision;* there may be some ciliary congestion, slight pain, ocular fatigue and limited photophobia. There occurs an *exudate of serum and cells* with slight admixture of fibrin, sometimes slightly pigmented, *precipitated in dots* upon the posterior surface of the cornea, forming a *triangular area* over the lower part, apex above (Fig. 162, Plate XI). This sign has given rise to the term "*keratitis punctata*" and "*descemetitis*" as synonyms, though objectionable ones, for this disease; these terms indicate merely this particular symptom. Sometimes a number of spots coalesce and form small masses, called "*mutton-fat*" deposits on account of their appearance. The anterior chamber is deeper than normal and the aqueous may be slightly turbid. The pupil is somewhat dilated. *Tension* is apt to be increased at first and lowered later, or there may be alternations of increase and decrease. *Secondary glaucoma* is an important complication. There are often numerous minute opacities in the *vitreous* and the latter may become fluid; there may be involvement of the choroid.

b. *The Severe Type:*—The subjective symptoms resemble those of the mild form. But the *objective signs are more pronounced:* The exudate is considerable and consists largely of *plastic material.* On account of the nature of the exudate, this type is known as *plastic iridocyclitis,* in contradistinction to the mild type in which the exudate is chiefly serous, which is called *serous iridocyclitis.* The plastic exudate forms in

the anterior chamber, pupillary space, behind the iris and in the vitreous, forming dense *membranes;* its subsequent contraction causes detachment of the retina; the iris atrophies; the lens suffers and secondary cataract results; choroid and retina atrophy. Finally *blindness* ensues and the degenerated eyeball shrinks; this condition is known as *atrophy of the eyeball.* The eye may now remain quiet or there may be periodic attacks of pain and tenderness. The *complications* are secondary glaucoma, which is quite common, and scleritis.

Prognosis *varies* with the type of disease. The liability to secondary *glaucoma* always makes the prognosis uncertain. In many instances of the *mild form,* the disease subsides after a lengthy course, with or without relapses, and the eye returns to a *normal* condition with no interference with vision; or there may be *limited damage* from iritic adhesions or vitreous opacities which have not been completely absorbed; such favorable outcome is possible, because the exudate is largely *serous* with little or no plastic addition and is capable of *absorption.*

In the *severe form* the prognosis is always *grave;* though capable of cure when vigorously attacked in the early stages and of escape with more or less useful vision, the majority of such eyes are *lost,* owing to damage through the deposit, organization and contraction of the plastic exudate.

The two forms of uveitis may pass from one to the other, seeming to belong to the mild type at first and changing to the severe form; there is often no sharp line of demarcation.

Treatment is that of *iritis,* but the indications are for more *vigorous interference.* It is especially important to *remove every source of infection* as soon as possible. Thus the removal of an infected tooth, tonsil, or accessory sinus disease, the injection of salvarsan in a syphilitic, of tuberculin in a tuberculous subject, and colonic irrigations in intestinal auto-intoxication, will often prevent the mild from changing into the severe variety.

Locally, *atropine, dionine, hot moist compresses* and subconjunctival injections of normal saline solution are used. If tension is increased, we may have to omit mydriatics or substitute miotics; this symptom may call for *paracentesis* of the anterior chamber, and this may have to be repeated.

Diaphoresis is very useful. *Mercury* by inunction or by mouth, even in the non-specific cases, is sometimes of value; also *iodides*, thyroid, and large doses of *salicylates*.

Where a source of focal infection has been discovered, such as a tooth or the tonsil, a culture is made from the infective material and then a *vaccine;* the latter is injected hypodermically in increasing dosage.

After the eye has become quiet, unless hopelessly lost, an *iridectomy* may be indicated for optical purposes, or to restore communication between the anterior and the posterior chambers and thus prevent subsequent glaucoma.

3. **Purulent Iridocyclitis** (*Purulent Uveitis* is described under Purulent Choroiditis on p. 186 and Panophthalmitis on p. 192.

4. **Sympathetic Iridocyclitis** (*Sympathetic Uveitis*) is described under Sympathetic Ophthalmitis on p. 188.

Injuries of the Ciliary Body.—The *ciliary region*, represented by a pericorneal ring about 6 mm. wide, is known as the "*dangerous zone*," because penetrating wounds in this situation are apt to set up *plastic uveitis*, which may be followed by *sympathetic ophthalmitis*. After thorough cleansing, extensive ciliary wounds are *closed* by one or more sutures passed through the superficial layers of the sclera or through the conjunctiva; such wounds are often covered by a conjunctival flap. Prolapse of the iris should be excised but a prolapsed ciliary body should not be removed. The presence of a foreign body in the globe must be excluded. A bandage is then applied. If the wound is very extensive and sight is lost, *enucleation* is indicated. Additional details of treatment are given in the paragraphs on Injuries of the Sclera (p. 162) and on Sympathetic Ophthalmitis (p. 188).

CHAPTER XII

DISEASES OF THE CHOROID

Anatomy and Physiology.—The choroid is a *dark brown membrane* placed between the sclera and the retina, extending from the ora serrata to the opening for the optic nerve. It consists mainly of *blood-vessels*, united by delicate connective tissue containing numerous *pigmented cells;* these vessels are arranged according to their calibre into three superimposed layers.

This vascular structure is bounded on either side by a non-vascular membrane; accordingly, the choroid can be divided into *five layers:* (1) Externally, the *suprachoroid*, connected with the sclera by loose connective tissue. (2) The layer of *large vessels*, chiefly anastomosing veins, the spaces between which are filled with connective tissue and pigment cells; the arteries are the short ciliary; the veins are arranged in curves (*vasa vorticosa*) converging to four or five principal trunks which pierce the sclera near the equator of the eyeball. (3) The layer of *medium-sized vessels*. (4) The layer of *capillaries* (chorio-capillaris). (5) The *lamina vitrea*, a homogeneous membrane which is placed next to the pigmentary layer of the retina.

The *function* of the choroid is chiefly to serve as a *nutrient organ* for the retina, vitreous, and lens. It forms the *dark* coating of the interior of the eyeball.

Inflammations of the Choroid (choroiditis) may be (1) *exudative or non-suppurative*, and (2) *suppurative*.

EXUDATIVE OR NON-SUPPURATIVE CHOROIDITIS

Varieties.—Exudative choroiditis (Plates XII, XIII, XIV) is classified, according to the location of the foci of inflammation, into the following principal forms: (1) Diffuse, (2) Disseminated, (3) Circumscribed, (4) Anterior, (5) Central, (6) Syphilitic, and (7) Myopic. It is of *frequent* occurrence and is observed at *all ages;* it is usually *chronic* in its course, though occasionally with acute onset. In many instances the disease involves the retina as well as the choroid, and is then properly spoken of as *choroidoretinitis* or retinochoroiditis. It will be of advantage to describe *Exudative Choroi-*

ditis in General, before giving the distinctive features of the several varieties.

Subjective Symptoms.—There are *disturbances of sight:* Diminution of vision due to opacities in the vitreous; also *distortion* of objects (metamorphopsia),—either micropsia, when objects appear too small, or macropsia, when they appear too large—as a result of displacement of the retinal elements over the inflamed focus; and a reduction or loss of vision in that part of the field which corresponds to the seat of exudation. There are often *flashes* of light, sparks, or bright circles (photopsiæ) before the eyes. In the later stages there may be *defects in the field* of vision, both scotoma (Fig. 171) and peripheral contraction. There is no pain unless the iris or ciliary body is involved.



FIG. 171.—Peripheral Scotomata in Exudative Choroiditis.

Objective Symptoms.—There are no external signs, but the ophthalmoscope reveals a well-marked picture. There are patches of *exudation* varying in size, shape, and position. At first these areas are *yellowish* (sometimes greenish-gray) in color, with *ill-defined margins;* the retinal blood-vessels are seen to be lifted and to pass over them. Later, after several weeks or months, the exudation becomes absorbed, leaving patches of *choroidal atrophy;* the latter appear as *whitish* areas (the sclera showing through) often presenting distinctly visible choroidal vessels, and marked with more or less pigment, especially at their margins. Usually the *vitreous* is involved, and then there are *opacities* of this medium. Very often the *retina* becomes atrophied opposite the patches just described. The *optic disc* may participate and be hyperæmic at first and later present a dirty yellowish-red color with blurred margins, a condition often spoken of as " choroiditic atrophy."

Complications.—From this description it will be seen that *neighboring structures* are frequently implicated: Iris, retina, optic nerve, vitreous, and sclera; choroiditis may also cause posterior polar cataract.

Etiology.—Frequently some *constitutional* disease, especially acquired and hereditary syphilis, but also anæmia, scrofula, and tuberculosis; many examples are found in *myopia;* it may depend on *septic* infection from the teeth, oral and nasal cavities, or upon *intestinal* auto-intoxication; many cases with obscure origin are spoken of as idiopathic.

Prognosis depends upon the *position of the patches* of exudation with subsequent atrophy. A single patch involving the macular region will seriously impair vision. On the other hand, the process may extend over a considerable part of the fundus and yet vision remain good, if the macula escapes.

Treatment.—Removal of the etiological factor; *iodides* and *mercury* in syphilitic cases; inunctions of mercury are often used with success even in non-syphilitic cases; *tuberculin* in suitable patients; attention to the general health; *diaphoresis* is often valuable. Rest of the eyes, avoidance of bright light by the use of smoked glasses; subconjunctival injections of normal salt solution are often useful.

Distinctive features in the different varieties of exudative choroiditis will be briefly considered:

1. **Diffuse Choroiditis** (Fig. 172, Plate XII).—In this form the patches of exudation are of considerable size, gradually shading into the surrounding portions of the choroid; later, when atrophy occurs, the coalescence of these spots forms large areas of white or yellowish-white color, more or less pigmented, representing the exposed sclera.

2. **Disseminated Choroiditis** (Fig. 173, Plate XII) presents numerous round or irregular *spots* with pigmented margins, *scattered* over the fundus, beginning in the periphery, and gradually encroaching upon the centre. The entire fundus may be studded, and yet vision remain good if the macular region escapes. This form of choroiditis runs a very *chronic* course. After a time, it may be accompanied by opacities of the vitreous and choroiditic atrophy of the optic nerve.

3. **Circumscribed Choroiditis** is a variety occurring not infrequently in young individuals in whom a single patch of yellowish-white or bluish-green color with fading edges is seen near the disc or macula or more peripherally, accom-

PLATE XII

FIG. 172.—Diffuse Exudative Choroiditis.

FIG. 173.—Disseminated Choroiditis.

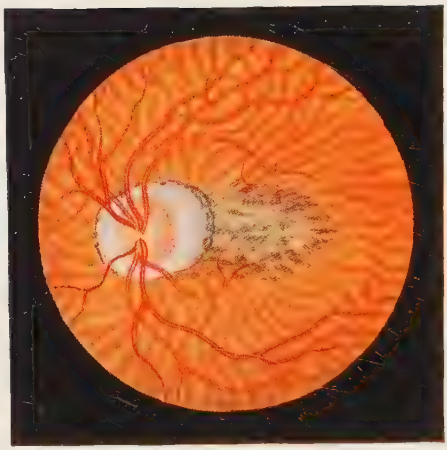

FIG. 174.—Choroiditis of Myopia.



FIG. 175.—Central Choroiditis.

panied often by deposits on Descemet's membrane and by vitreous opacities, but causing little damage to vision unless the macular region is invaded; relapses are common.

4. **Anterior Choroiditis,** presenting foci of exudation eventually appearing as black spots in the extreme periphery of the fundus, is seen in high myopia and in hereditary syphilis.

5. **Central Choroiditis** (Fig. 175, Plate XIII) is a form in which the changes are limited to the region of the *macula;* it occurs most frequently in *high myopia,* but also in syphilis and after contusions of the eyeball. It results in *serious* interference with vision and causes *central scotoma.* It also occurs as a result of senile changes (*central senile choroiditis*).

6. **Syphilitic Choroidoretinitis** (Fig. 176, Plate XIV) is the name given to inflammation of the choroid, associated with *retinitis* and changes in the *vitreous,* which occurs in syphilis. At first there are diffuse *cloudiness* of the retina, numerous *exudations* in the choroid, especially in the region of the macula, and fine, *dust-like* opacities of the *vitreous.* Later, the cloudiness of the retina is replaced by *atrophy,* there are atrophic patches of the choroid, numerous spots of *pigment* in the periphery of the fundus, and *opacities* of the vitreous.

7. **Myopic Choroiditis; Posterior Staphyloma, or Sclerochoroiditis Posterior.**—The fundus of nearsighted eyes, especially if the myopia be of high degree, very often presents characteristic changes (Fig. 174, Plate XIII, and Fig. 177, Plate XIV). Owing to the elongation of the eyeball, there is a *bulging of the sclerotic* at the posterior pole and *atrophy of the choroid* in this situation. This shows itself in a white crescent (*myopic crescent*) situated usually to the outer side of the disc, varying in size, and sometimes encircling the papilla. It is known as posterior staphyloma or sclerochoroiditis posterior; it is sometimes called "conus."

When this crescentic or annular patch is separated from healthy choroid by a sharply defined margin, often pigmented, it is a sign that the process has come to a standstill. But when the border is ill-defined, it indicates that the changes are advancing (*progressive myopia*); such knowledge is of great importance in emphasizing the necessity for attention

to ocular and general hygiene. The size of the staphyloma is usually, but not always, proportionate to the degree of myopia. More or less *superficial atrophy* of the choroid is often observed in myopia of high degree, allowing the larger choroidal vessels to become plainly visible. Besides choroiditis in the macular region, there may be patches of choroidal atrophy in *other parts* of the fundus; these often coalesce with the posterior staphyloma, so that an extensive white area is seen, spotted or bordered with more or less pigment. The early changes in the macular region may be represented by fine lines or fissures. *Hemorrhages*, especially in the macular region, and *opacities of the vitreous* also occur in myopia of high degree.

SUPPURATIVE IRIDOCHOROIDITIS

This disease, also known as *purulent uveitis* and as *endophthalmitis*, usually involves all of the uveal tract.

Symptoms.—1. Infrequently, the process is limited to the choroid (*suppurative choroiditis*), the purulent exudate fills the vitreous (*abscess of the vitreous*), with no external evidences of inflammation, but always with loss of vision. A *yellowish* or greyish-yellow *reflex* is obtained from the interior of the eye; the purulent mass degenerates and later forms a membrane lining the vitreous, known as *pseudo-glioma*, on account of its resemblance in color to glioma of the retina.

2. More commonly, the purulent exudate fills the *whole interior* and involves the *entire uveal tract*. Then the symptoms are those of acute iridocyclitis and are severe: Much pain, conjunctival congestion, chemosis, swelling of lids, cloudy cornea, pus in the aqueous as well as in the vitreous, constitutional disturbance and loss of sight; finally, a blind, degenerated, shrunken globe remains (*atrophy of the eyeball*).

3. In still other cases, the process involves *all structures* of the eyeball and constitutes *panophthalmitis* (p. 192).

Etiology.—Infection of the interior of the eye by pyogenic microbes, either from without or from within the body. *Ectog-*

PLATE XIV

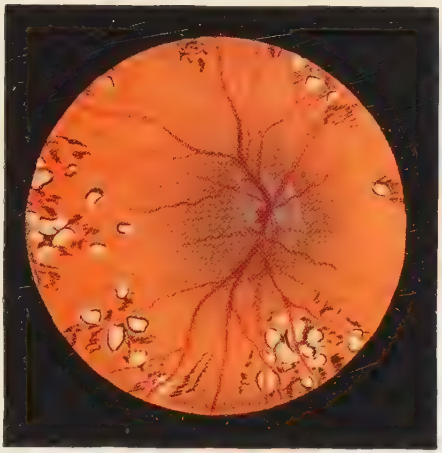

Fig. 176.—Syphilitic Choroidoretinitis.

Fig. 177.—Posterior Staphyloma.

enous infection occurs most frequently from *penetrating wounds*, including operations, perforating ulcers, thin corneal scars, and prolapse of iris. *Endogenous* infection results from *septic* embolism (metastatic ophthalmia) and is seen most frequently in puerperal pyæmia, also surgical pyæmia; extension from orbital cellulitis; also in meningitis and cerebrospinal *meningitis*, especially in children, in infectious diseases, and in suppuration of the umbilical cord.

Treatment.—It is impossible to save sight. Pain should be relieved by morphine and by the local applications of hot, moist compresses. If the process has involved all the ocular structures, the treatment of panophthalmitis is indicated (p. 192).

Coloboma of the Choroid is a *congenital* defect of the choroid and retina, showing itself in a *large white patch*, representing the exposed sclera; it is usually situated below the disc. The retinal vessels are seen passing across this patch. There is a *scotoma* corresponding to the defect. This condition is sometimes associated with coloboma of the iris and other congenital defects of the eye.

Rupture of the Choroid sometimes results from *contusions* of the eyeball. The immediate effect of such an injury is an extravasation of blood into the vitreous. After this is absorbed a long, *yellowish-white streak* with pigmented edges, curved with its concavity toward the disc, is seen, usually in the neighborhood of the disc and to its outer side.

Tubercle of the Choroid occurs in acute miliary tuberculosis and in tuberculous meningitis. The tubercles appear as small, yellowish-white spots with soft, fading edges, vary in number, are 1 or 2 mm. in diameter, and are found near the disc, in the macular region, or scattered over the fundus. They resemble the spots seen in recent cases of disseminated choroiditis but are smaller. Tuberculosis rarely assumes the form of a solitary irregular mass which may be mistaken for glioma of the retina or sarcoma of the choroid.

Sarcoma of the Choroid (see Chapter XIV).

CHAPTER XIII

SYMPATHETIC OPHTHALMITIS
PANOPHTHALMITIS

Inflammation of the whole uveal tract has been described on p. 179 under Chronic Iridocyclitis or Uveitis, comprising two varieties: mild (*Serous Iridocyclitis*) and severe (*Plastic Iridocyclitis*). A second variety, the purulent, is described under *Suppurative Iridochoroiditis*, p. 186.

There are two additional and special varieties: 1., *Sympathetic* Uveitis, generally known as *Sympathetic Ophthalmitis*, and 2., the form or outcome of *Purulent* Uveitis known as *Panophthalmitis*.

SYMPATHETIC OPHTHALMITIS

Sympathetic Ophthalmitis (Sympathetic Ophthalmia, Sympathetic Uveitis) is a *serous or plastic inflammation of the uveal tract* in one eye due to the effects of a similar inflammation in the other.

Etiology and Occurrence.—This inflammation is almost always due to a *traumatic iridocyclitis* of the first eye as a result of a *perforating injury;* the most common example of such injury is an accidental or operative wound involving the ciliary region, especially if the iris or ciliary body be entangled in the wound. *Foreign bodies* retained in the eyeball are also apt to excite this disease. Sometimes it results from the iridocyclitis following perforating wounds or ulcers of the cornea complicated by incarceration of the iris, or occurring with intraocular tumors. Rarely it occurs without any perforating lesion. Suppurative inflammations of the eyeball are not usually exposed to the risk of sympathetic ophthalmitis.

It is, fortunately, not of very frequent occurrence, for it is a most *serious* disease, on account of its tendency to cause blindness. It occurs most frequently in the young, especially in *children*, but may be met with at any age. It was formerly

more common than it is at present on account of modern antiseptic methods. It usually begins between four and eight weeks after the injury in the exciting eye, rarely before three weeks; it may, however, occur many months or even years after the injury.

The eye which has been originally affected is known as the *exciting eye;* the one secondarily involved, as the *sympathizing eye.*

Symptoms.—In most cases, but not invariably, the disease presents a stage known as *sympathetic irritation;* it is very important to recognize this stage, since removal of the exciting eye at this period will prevent the progression of the affection from irritation to actual inflammation.

The Symptoms of Sympathetic Irritation.—The *sympathizing eye* is "*irritable*"; there are marked *photophobia* and *lacrymation;* neuralgic *pain* in the eye and neighboring parts; *dimness* of vision occurs when the eyes are used for near work; there may be bright and colored sensations.

The *exciting eye* usually presents an *iridocyclitis* or uveitis, which may be slight or severe; when the sympathizing eye becomes affected, there may be symptoms of irritation and marked tenderness over the ciliary region in the exciting eye.

These symptoms of irritation in the sympathizing eye may be *intermittent;* each attack may last a number of days or weeks, then subside, and recur a number of times. They may finally disappear entirely. But, as a rule, if the exciting eye is not excised, *sympathetic inflammation results.*

The Symptoms of Sympathetic Inflammation.—These may follow directly upon those of irritation, or may occur after the sympathizing eye has been quiet for a time. They may begin *acutely* or *insidiously.* When once established the inflammation is *chronic,* and its duration is months or even one or two years. In the majority of cases *blindness* results, though occasionally, if the inflammation be mild, useful vision may be preserved.

The symptoms are *photophobia, lacrymation, dimness* of vision, and *tenderness* in the ciliary region. There will be circumcorneal *injection,* punctate *deposits* upon Descemet's

membrane, *increased depth* of the anterior chamber, *contracted pupil*, and *increased tension*.

In mild cases (serous type) the symptoms may not pass beyond those of serous cyclitis or iridocyclitis; but usually they develop into a *plastic uveitis* including iris, ciliary body, and choroid, and giving the following signs: The *iris* is thickened, its color changed, and its markings obliterated; it is firmly bound down by numerous and extensive posterior *synechiæ*. The plastic *exudation* fills up the pupil and more or less of the anterior chamber, which becomes shallow. *Tension* is diminished. The choroid and retina participate in the plastic inflammation, the *vitreous* presents numerous *opacities*, and the *lens* becomes opaque. Finally, there is *detachment* of the *retina*, the eyeball *shrinks* and passes into the condition of *atrophy*.

Occasionally sympathetic disease occurs in the form of a neuroretinitis without extension to the uveal tract, or as a choroiditis.

Theories of Transmission.—The mode of transmission is not definitely known. The theories which have been propounded are: (1) *Infection* spreading through the sheath of the optic nerve of one side to the chiasm and sheath of the optic nerve of the other eye; (2) irritation through the ciliary *nerves;* (3) the action of a toxin generated by bacteria which have entered the exciting eye, reaching the second eye by lymph channels; (4) *metastasis* through the blood current, of some form of bacteria which are pathogenic for the eye only; since such bacteria have not been isolated, it is thought that the noxious agent is a *toxin* of these bacteria. At present, the last is regarded as the most probable explanation.

Treatment. *Prophylactic treatment* is of the greatest importance, and refers to the care of the injured eye on the lines explained in dealing with iridocyclitis, including full doses of *mercury* up to the point of salivation and large amounts of *sodium salicylate*. We should *enucleate the injured eye* if it be sightless, or its condition such (especially when the ciliary region is involved) that we cannot hope to preserve useful vision; this is particularly imperative if it is

irritable, has ciliary tenderness, presents persistent signs of iridocyclitis, or contains a foreign body which cannot be extracted.

When, however, there is useful vision in the injured eye, or a good chance of obtaining fair sight, the question of enucleation is often a difficult one to decide, since symptoms of sympathetic irritation may appear and then subside, and yet sympathetic inflammation never develop. In such cases we are often justified in waiting, if the injured eye remain quiet and free from inflammation, providing we can keep such a patient under constant observation, so that we are able to enucleate when warned by repeated or persistent symptoms of sympathetic irritation.

Although enucleation of the injured eye usually has a favorable influence upon the sympathetic process during the stage of irritation, it has no effect upon the progress of the disease after sympathetic inflammation has made its appearance; the exciting eye may ultimately possess better vision than its sympathizing fellow. Hence, under such circumstances, the exciting eye should not be removed if it possesses vision; if blind and exhibiting signs of inflammation, it should be enucleated, even with the knowledge that this step will not cure the sympathetic ophthalmia, since its presence may aggravate the condition in the sympathizing eye.

The treatment of the sympathetic ophthalmia itself consists in the use of *atropine* (unless this seems to aggravate the symptoms), *dionine, hot compresses,* reasonable confinement to a shaded room, and smoked coquilles; *diaphoresis;* leeches to the temple are sometimes of advantage. *Mercurialization* is frequently resorted to up to the point of salivation. Large doses of *sodium salicylate* are sometimes effective. *Salvarsan* has given very gratifying results. Since the disease is of lengthy duration, the general health of the patient must be looked after.

Though the *prognosis is unfavorable* and most cases end in blindness, the treatment must be carried out rigidly and patiently; in some cases at least, especially if the inflammation be of the *serous* type, *fair vision* may ultimately be obtained.

PANOPHTHALMITIS

An intense *suppurative inflammation of the entire uveal tract,* which fills the eyeball with *pus,* extends to all the structures of the eye, and ends in *complete destruction* of this organ. It is due to *infection.* It differs from suppurative iridochoroiditis in spreading beyond the uveal tract and involving all the structures of the eye.

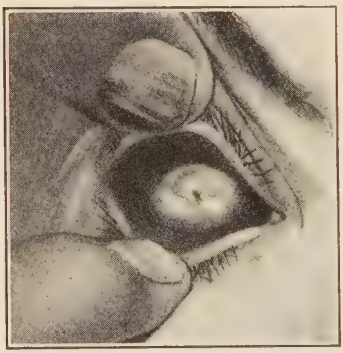

Fig. 178.—Phthisis Bulbi.

Etiology.—Identical with that of suppurative iridochoroiditis (p. 186).

Symptoms (already described in connection with suppurative iridochoroiditis, p. 186) are apt to be *acute* and *severe.* The disease is usually ushered in by a rise of temperature, *general febrile symptoms,* headache, and sometimes vomiting. There are severe *pain* in the eyeball, rapid *loss of sight,* intense ciliary and conjunctival *congestion,* marked *chemosis,* and *swelling* and redness of the *lids* (Fig. 163, Plate XI). The iris soon becomes involved, the anterior chamber and vitreous become filled with *pus,* the cornea is *clouded* and yellow (Fig. 164, Plate XI), and tension increased. There is infiltration of Tenon's capsule, followed by *exophthalmos* and limitation of the movements of the eyeball.

Pus usually *breaks* through the anterior portion of the sclera, after which the pain and other symptoms *subside;* in the course of several weeks the process has run its course, leaving a shrunken, *sightless eyeball* (phthisis bulbi, Fig. 178).

Prognosis is always *unfavorable:* sight is invariably lost. The condition does not cause sympathetic ophthalmia, except in rare instances.

Treatment.—The indications are to *alleviate pain* by the use of morphine and hot, moist compresses, and to *incise* the

sclera so as to allow the escape of pus. If the case is seen early, thorough and repeated cauterization of the focus of infection with the electro-cautery, the introduction of small rods of iodoform into the anterior chamber, paracentesis and frequent irrigation of the anterior chamber, and mercurialization may, in rare instances, be of service. It is not considered advisable to enucleate in the inflammatory stage, on account of the danger of setting up meningitis

CHAPTER XIV

INTRAOCULAR TUMORS

Intraocular tumors are *rare*. Their recognition is, however, important, since early enucleation of the eyeball may save life. There are two principal varieties: (1) Sarcoma of the Choroid, and (2) Glioma of the Retina.

SARCOMA OF THE CHOROID

This malignant growth occurs in *adults*, usually between the ages of forty and sixty. It is always *primary, single*, and involves *one eye* only. It is composed of round or spindle cells, or both, usually pigmented (*melanosarcoma*), but sometimes non-pigmented (leucosarcoma). It forms a *rounded mass* which springs from the outer layers of the choroid, most commonly near the posterior pole, and grows inward, pushing the retina before it (Fig. 179).

Fig. 179. –Sarcoma of the Choroid, with Detachment of the Retina.

Symptoms.—There are four stages:

In the first or *quiet stage*, there will be a *defect in the field* and *diminution in sight* depending upon the exact seat of the tumor. With the ophthalmoscope a *yellowish, brown, or black mass* may be seen, covered by circumscribed detached retina. Sometimes the retina is more diffusely detached and thus obscures this picture. The anterior ciliary veins may be found dilated near the seat of the growth. This stage usually lasts about a year.

In the second or *glaucomatous stage*, the tumor *enlarges* in size and gives rise to *pain*, increased tension, and other symptoms of inflammatory *glaucoma*. Increase in the retinal detachment and other changes now prevent a view of the interior of the eye.

In the third or *extraocular stage*, the tumor *bursts* through the globe and then *increases* very rapidly in size, and *ulcerates* with accompanying hemorrhages. In most cases it perforates anteriorly, and a dark mass is seen. If it perforates posteriorly, exophthalmos results. It soon implicates *neighboring structures*, including the brain.

The fourth stage is distinguished by the occurrence of *metastases*, most frequently in the liver.

Differential Diagnosis.—Sarcoma of the choroid may be mistaken for *detachment of the retina*, *glaucoma*, or possibly *glioma* of the retina; the last, however, occurs only during the first years of life. Ordinary detachment of the retina usually occurs suddenly in a myopic eye, or after a blow, and tension is diminished. From primary glaucoma sarcoma of the choroid is distinguished by the fact that sight is involved before the inflammatory symptoms appear, there are no prodromal symptoms such as usually precede glaucoma, nor remissions in symptoms, one eye only is involved, and the characteristic field of glaucoma (nasal limitation) is not present. Transillumination is often valuable for diagnosis, the pupil remaining dark when the instrument is placed upon the lids corresponding to the seat of the tumor; when situated near the posterior pole this test is of no value.

Prognosis.—When the eye is enucleated early, cure results in from 20 to 30 per cent. of cases. But even after early removal of the eye, death results in many cases from metastasis in internal organs, occurring within a few years; much less frequently from local recurrence in the orbit.

Treatment.—*Enucleation* as soon as the diagnosis is established, cutting the optic nerve far back. It will be necessary to remove the entire contents of the orbit if the growth has broken through the globe. After enucleation or exenteration, a few prophylactic exposures to radium or X-rays are indicated.

GLIOMA OF THE RETINA

A *malignant* growth (Fig. 180), consisting of small cells with soft basement substance and blood-vessels, developing

from the granular layers of the retina; it occurs in *children* under five, usually in *one eye*, at times in both, and occasionally in successive children of the same family.

Symptoms.—We distinguish three stages:

In the first or *quiet stage* there are no inflammatory symptoms. The ophthalmoscope shows small *whitish or yellowish masses* with *metallic lustre*, growing into the vitreous, the surface presenting *newly formed blood-vessels*. The attention of the parents is attracted by the striking *yellow reflex*, easily seen through the pupil, which is usually dilated; this symptom has given rise to the synonym "*amaurotic cat's eye*."

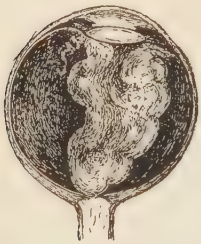

FIG. 180.—Glioma of the Retina.

In the second or *inflammatory stage* there are *pain*, increase of *tension*, and other symptoms of inflammatory *glaucoma*. The tumor *increases* in size and extends into the vitreous. Very soon the growth can no longer be seen on account of turbidity of the media.

In the third or *extraocular stage* there is bulging of the eyeball, both *staphyloma* and *exophthalmos*, and then *perforation* takes place. The growth passes backward along the optic nerve to the *brain* (in this way it becomes fatal), and forward through the cornea and sclera, *increasing* in size rapidly, involving all neighboring tissues, and forming a large vascular and ulcerating mass. Metastases are rather rare.

Differential Diagnosis.—We must distinguish glioma from *pseudo-glioma* (p. 186), the degenerated eyeball which is the outcome of purulent iridochoroiditis following meningitis or cerebro-spinal meningitis in children. In the latter affection there is the history of a previous acute febrile disease with inflammation of the eyeball, tension is diminished, the pupil is not dilated and it may be irregular, the anterior chamber is deepened at its periphery, there may be other signs of previous iritis, and the yellowish mass is flatter and is not covered by newly-formed vessels. When in doubt, such eyes being always sightless, we should enucleate.

Treatment.—*Enucleation* as soon as possible, cutting the

optic nerve far back. If the growth has perforated, the entire orbit must be cleaned out; even then there is danger of recurrence. When excision is practised early there is a fair chance of cure. Unless this is done death occurs within a few years. After enucleation or exenteration a few prophylactic exposures to radium or the X-rays are indicated.

CHAPTER XV

GLAUCOMA

Anatomy.—The *aqueous chamber* is bounded in front by the cornea, behind by the lens and its suspensory ligament, and laterally by the ligamentum pectinatum and anterior portion of the ciliary body (Fig. 181). Its depth varies; it is comparatively deep in the young, in myopic eyes, and when the eye is focussed for distant objects. The iris divides the aqueous cavity into an *anterior* and a *posterior chamber* (Fig. 182). The former lies in front of the iris. The latter is the annular space between the iris and the lens; since the iris is in contact with the lens only at its pupillary margin, this space increases in depth from the pupil to the peripheral border of the iris, and is triangular in cross-section. The posterior communicates with the anterior chamber by means of the pupil.

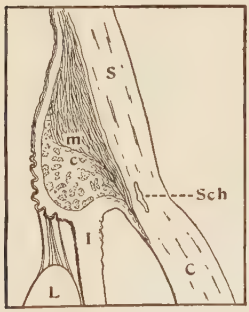

FIG. 181.—Section of the Eyeball at the Sclero-corneal Junction, Showing Angle of Anterior Chamber. *S*, Sclera; *C*, cornea; *I*, iris; *L*, lens; *cm*, ciliary muscle; *Sch*, canal of Schlemm.

The portion of the anterior chamber where the sclerocorneal margin, iris, and ligamentum pectinatum meet is known as the *angle* or *sinus of the anterior chamber* (often called the *iris angle*). This region is of great importance; upon its integrity depends the proper circulation of the lymph which nourishes the anterior portion of the eyeball.

The *ligamentum pectinatum* is formed by the breaking up of Descemet's membrane at the margin of the cornea, into bundles which connect the sclera with the root of the iris. These elastic laminæ are covered by endothelium continued from Descemet's membrane. In this way spaces are formed which are continuous with the cavity of the aqueous, are lined with endothelium, and are known as the *spaces of Fontana*. To their outer side, at the sclerocorneal junction, is *Schlemm's canal*, a plexus of veins.

With the exception of the conjunctiva, no portion of the eyeball contains lymphatic vessels; in place of such vessels and serving the same function, there are *lymph channels* and *lymph spaces*. These may be divided into those of the anterior and those of the posterior portion of the eyeball.

The *anterior lymph spaces and cavities* consist of the aqueous chamber and the parts immediately around the iris angle. The anterior and posterior chambers represent two large lymph spaces which collect the lymph of the anterior portion of the eye. This lymph is known as the *aqueous humor*, and consists of a clear, watery fluid, containing very little albumin, secreted by the ciliary processes. It first passes into the posterior chamber, then through the pupil into the anterior chamber, and leaves the eye through the spaces of the ligamentum pectinatum (Fontana's spaces) and Schlemm's canal, passing into the anterior ciliary veins; a portion passes into the lymph spaces of the iris, and thence to the suprachoroidal lymph space.

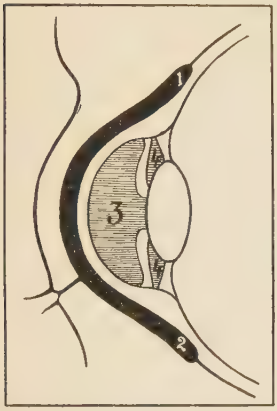

FIG. 182.—Diagrammatic Section of the Anterior Portion of the Eyeball showing: (1) Upper Conjunctival Sac, (2) Lower Conjunctival Sac, (3) Anterior Chamber, (4) Posterior Chamber

The *posterior lymph passages* consist of the hyaloid canal of the vitreous, and of the suprachoroidal space (between choroid and sclera), communicating with Tenon's space along the venæ vorticosæ; both have for an outlet the supravaginal and infravaginal spaces of the optic nerve.

GLAUCOMA

Glaucoma is an important and *common* disease of the eye, which has for its characteristic sign an *increase of intraocular tension.*

Varieties.—It is (1) *primary*, when occurring without antecedent ocular disease, and (2) *secondary*, when it follows as a result of some pre-existing disease of the eye.

Primary Glaucoma occurs under two forms: 1, *Congestive* (Inflammatory), and 2, *Non-congestive* (Non-inflammatory), usually spoken of as *Simple.*

The *congestive* variety is again divided into 1, *acute*, and 2, *chronic;* intermediate cases are sometimes called *subacute.*

These variations in clinical types of primary glaucoma are explained by the rapidity with which the increase of intraocular pressure shows itself and the height to which it rises. When the increase of tension is rapid, the *congestive* type results; when gradual, the eyeball accommodates itself to the

altered conditions, and symptoms of congestion or inflammation are absent; the disease is then known as *simple* glaucoma (non-congestive or non-inflammatory glaucoma); this type is always chronic in its course.

Congestive glaucoma presents a clinical picture which is quite different from that of the non-congestive or simple form. But there are numerous *transition types* in which a sharp line of distinction cannot be drawn. Furthermore, simple glaucoma may change to acute or chronic congestive glaucoma.

ACUTE CONGESTIVE GLAUCOMA

Symptoms.—The affection can be divided into *three stages:* 1, the *prodromal* stage, 2, the stage of *active glaucoma*, and 3, the stage of *absolute glaucoma*. To these we may add a fourth stage, the stage of *degeneration*.

The Prodromal Stage.—This stage is present in most instances; it may, however, be absent. There will be some diminution in the acuteness of *vision*—the sight appears to be obscured by *fog*. A ring of *rainbow tints* will be seen around lights; the *cornea*, especially at its centre, will, upon careful inspection, be found slightly *clouded;* this condition (œdema) is the cause of the preceding symptoms. There will be a feeling of dulness or *slight pain* in the eye and head. The *anterior chamber* is rather *shallow*, the *pupil* somewhat *dilated*, often oval, and *sluggish* in reaction. The *tension* of the globe is *increased*. There is often slight circumcorneal injection.

These symptoms last for a number of hours and then disappear entirely; the eye returns to a normal condition, except that there is a *diminution* in the power of *accommodation*, so that the patient requires stronger glasses than are natural at his age. Hence a rapid increase of presbyopia should always excite suspicion of glaucoma. Such prodromal attacks are often excited by insomnia, worry, emotional excitement, or some condition which causes venous congestion, and sometimes by overeating, indigestion, or the local use of atropine. They are in many cases relieved by sleep. At first the attacks are separated by *intervals* of weeks or months, but they soon become more frequent.

PLATE XV

Fig. 183.—Acute Inflammatory Glaucoma.

Fig. 184.—The Fundus in Chronic Glaucoma.

This stage lasts a number of weeks or months, sometimes several years; then the disease suddenly passes into the second stage.

The Stage of Active Glaucoma ("Glaucomatous Attack"). —The *sudden onset* which characterizes this stage may be due to one of the exciting causes which bring on the prodromal attacks. There are *rapid failure of sight*, contraction of the visual field, especially on the nasal side (Fig. 188), and severe *pain in the eye*, radiating along the branches of the fifth nerve and causing violent *headache;* this pain is sometimes so severe that it occasions nausea, vomiting, general depression, and febrile disturbances, such attacks having been mistaken for "bilious attacks."

Objective examination reveals marked *increase in tension*. The lids are swollen and œdematous. The ocular conjunctiva is markedly congested and chemotic. The *cornea* is clouded or *steamy* (due to œdema), often presents punctate opacities, and is insensitive (from pressure upon nerve filaments); there is pronounced circumcorneal *injection* of a dark red color; the episcleral veins are prominent (Fig. 183, Plate XV). The *anterior chamber is shallow*, the aqueous sometimes turbid. The *pupil* is *dilated*, oval, immobile, and often presents a greenish reflex. The iris is congested, discolored, and dull. The lens and the periphery of the iris are pushed forward. No details of the fundus can be seen with the ophthalmoscope, on account of the *clouding of the media*.

In many cases in the course of a few days or weeks a *decided improvement* takes place. The pain subsides, congestion and œdema of lids and conjunctiva disappear, the cornea clears up, and sight improves. But the eye does not return to a perfectly normal condition; it is left in a condition known as the

Glaucomatous State.—Vision is not so acute as it was before the attack, and the visual field is somewhat contracted, especially on the nasal side. The pupil remains dilated, oval, and sluggish, the iris discolored, the anterior chamber shallow, tension increased, and there is more or less circumcorneal injection; the power of accommodation is diminished.

After a period of quiescence of variable length, *another*

attack occurs similar to the first, and this is succeeded by others; each attack causes greater reduction in sight.

After a while, the increased tension causes *excavation of the optic-nerve disc* (Fig. 187) recognizable with the ophthalmoscope in the intervals between attacks, when the media are clear. The lamina cribrosa, the portion of the sclera which is perforated by the optic-nerve fibres, is most yielding and

FIG. 185. FIG. 186. FIG. 187.

FIGS. 185, 186, 187.—Ophthalmoscopic Appearances and Longitudinal Section of the Optic-Nerve Disc. Fig. 185, Normal Disc; Fig. 186, Disc in Optic-Nerve Atrophy; Fig. 187, Glaucomatous Excavation.

hence bulges backward with the fibres of the nerve as a result of increased intraocular pressure. With the ophthalmoscope a *deep depression* with very steep or *overhanging margins* is seen; this is known as the *glaucomatous cup or excavation* (Fig. 184, Plate XV). The *blood-vessels bend* sharply over the margins of this excavation and often appear *interrupted* in this situation, being again seen, more or less faintly, at the bottom of the depression. They are pushed over toward the nasal side. The veins are distended and the arteries contracted. There is *pulsation* in the veins and in the *arteries* at the disc. Pulsation in the veins is often seen in health, but arterial pulsation is always pathological, and is an important symptom of glaucoma (it is also seen in certain forms of heart disease); if not spontaneous, it can be produced by slight pressure upon the eyeball. The *optic nerve* becomes *atrophied* and the disc appears *pale*, or in late stages *greenish* or bluish. The disc is often surrounded by a whitish-yellow ring (*glau-*

comatous halo or *ring*), due to atrophy of the choroid in this situation.

The Stage of Absolute Glaucoma.—With each succeeding attack the diminution in vision becomes greater, until finally *blindness* ensues; the condition is then known as absolute glaucoma. There are now no inflammatory or congestive symptoms, except a dark-red zone of circumcorneal *injection* and *dilated episcleral veins*. The cornea remains clear or slightly clouded, and often more or less insensitive. The *pupil* is widely *dilated*, immobile, and often presents a *greenish* reflex. The iris is atrophied, narrow, gray, with a border of dark pigment. The anterior chamber is shallow. *Tension* is markedly *increased*. The fundus presents a *deep excavation* of the disc, the glaucomatous ring, and atrophy of the optic nerve. Pain may disappear entirely, but frequently continues, and the patient suffers from severe attacks at intervals.

The Stage of Degeneration.—After absolute glaucoma has lasted a variable length of time, the eyeball is apt to degenerate. The cornea becomes more or less opaque, and frequently covered by deposits or vesicles. The sclera bulges and bluish-black staphylomata appear between the cornea and the equator. Detachment of the retina often takes place. The lens is apt to become cataractous. The patient may experience subjective sensations of light. The final result is that the *eyeball* either softens, shrinks, and *atrophies*, or else there are ulceration and perforation of the cornea, followed by iridocyclitis, with subsequent atrophy of the eyeball, or panophthalmitis and phthisis bulbi.

Glaucoma Fulminans is the name given to a form, of rare occurrence, in which very violent symptoms of inflammation develop suddenly, and in which blindness may ensue in a few hours, unless proper treatment be instituted.

CHRONIC CONGESTIVE GLAUCOMA

This form of glaucoma is much *more common* than the acute variety just described. *Its symptoms resemble those of the acute variety, but are less intense and more gradual in their onset.* Very often the prodromal stage passes uninterruptedly

into the stage of inflammation, and there is no succession of attacks. The ocular conjunctiva is congested and dusky, the episcleral veins being very prominent; there is circumcorneal injection of a dark-red color; the cornea is steamy and more or less insensitive; the anterior chamber is shallow, and the lens and iris are pushed forward; the pupil is dilated, oval, and rigid, surrounded by the discolored, narrow, and atrophic iris, and presents a greenish reflex. There is pain, but this is not so intense as in the acute form. There are gradual loss of sight and progressive limitation of the field, especially on the nasal side. After having lasted a sufficient length of time, the ophthalmoscope reveals the same changes in the fundus which are found in acute cases.

The chronic form has the same termination as the acute: absolute glaucoma and finally degeneration of the eyeball. In many cases, no sharp line of differentiation can be drawn between the acute and the chronic forms of congestive glaucoma.

SIMPLE GLAUCOMA

In simple glaucoma (Chronic Non-congestive Glaucoma), there is an *absence of any marked external symptoms;* there are *no inflammatory attacks and no pain.*

The diagnosis is made by noting the *increase of tension*, and by the picture presented when the *ophthalmoscope* is used.

This form develops very *gradually*, and may have lasted some time before the patient becomes aware of the existence of any abnormal condition. The eye may appear perfectly normal externally, or there may be slight circumcorneal *injection* and moderate dilatation of the episcleral veins. The *pupil* is slightly or moderately dilated and is *sluggish*. The *tension is elevated*, often moderately; sometimes the increase is not constant; with the tonometer a slight rise in tension can almost always be discovered. After the disease has lasted a certain length of time, the ophthalmoscope shows *glaucomatous excavation* (Fig. 187, and Fig. 184, Plate XV), atrophy of the optic nerve, and the circumpapillary ring of choroidal atrophy, the degree of change depending upon the duration of the process.

There may be periods when the patient complains of symptoms like those in the prodromal stage: *Foggy vision, colored halos* around artificial lights, and *diminished accommodation.* There are gradual *loss of sight, premature presbyopia,* and progressive *contraction* of the visual *field,* especially on the nasal side (Fig. 188), the reduction in the extent of the color-fields corresponding to that of the form-field. *Scotomata* are common; they may be central, paracentral, or peripheral; a very characteristic defect is often found directly continuous with the normal blind spot and therefore causing an enlargement of this area. Central vision is the last portion to be lost. On this account the patient may be able to read, and yet the field of vision be quite limited.

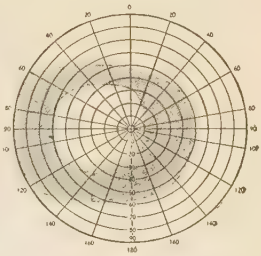

FIG. 188.—The Field of Vision in Glaucoma. Peripheral Contraction, especially on the Nasal Side.

The course of simple glaucoma is very *insidious* and its duration is *years;* if unchecked, it terminates in *blindness.* Sometimes this form gradually changes into the chronic congestive type, and then goes through the stages of the latter disease.

Occurrence and Etiology.—Glaucoma is a disease of *advanced life,* occurring generally between forty and seventy, infrequently before this period. The congestive form attacks women more often than men, the simple type occurs equally in both sexes. It usually involves *both eyes,* the second eye generally becoming affected months or years after the first. The exact cause of glaucoma is unknown. There are a number of *predisposing conditions:* It occurs much more frequently in Jews than among Christians. There is not uncommonly a history of *heredity. Arteriosclerosis* and cardiac disease, chronic constipation, and the gouty and rheumatic diatheses are predisposing factors. A disposition toward congestive glaucoma exists in *hyperopic eyes* (myopic eyes are particularly exempt) as well as in small eyeballs with large

lenses, and in those in which the cornea is of small size. The *exciting causes* may be the following: *Emotions* especially of a depressing character, *insomnia, worry,* injudicious use of atropine, *overuse* of ametropic eyes, insufficient food, overeating, indigestion, dissipation, various fevers especially influenza, and any condition which produces *venous congestion.*

Mode of Origin and Pathology.—All the symptoms of glaucoma can be explained by *increase in intraocular pressure* and *venous congestion.* But the cause of this increase in tension has not yet been determined; none of the *many theories* has been adequate to explain the occurrence of this disease in every case. The increased tension must depend upon a *disturbed relationship between intraocular secretion and excretion.* The older theories assumed the existence of hypersecretion produced in various ways; these views have been discarded. It is at the present time considered more probable that the disease is due to some interference with excretion (*retention*). The obstruction to the escape of the intraocular liquids is thought to be situated at the *angle* of the anterior chamber (iris angle). It is believed that this angle (Figs. 181, 189, 190) is *obliterated by pressure* of the peripheral portion of the iris against the sclerocorneal junction (ligamentum pectinatum) by the congested and swollen ciliary processes; later there is an *adhesive inflammation* between these opposed surfaces through proliferation of the endothelium of Descemet's membrane and of the iris. As already explained, this iris angle forms the principal exit for intraocular fluids, and when it is blocked, retention takes place. An additional causative factor is supposed to be the *narrowing of the circumlental space* (between the margin of

FIG. 189.—Angle of the Anterior Chamber in the Normal Eye.

FIG. 190.—Angle of the Anterior Chamber in Recent Congestive Glaucoma.

the lens and the ciliary body) in eyes predisposed to glaucoma. This area serves for the passage of the lymph which is secreted by the choroid and part of that produced by the ciliary body; it is encroached upon by the increased size of the lens with advancing age and by the comparatively large size of the ciliary body and the smaller size of the eyeball in general, in *hyperopes*. This embarrassment in the communication between vitreous and aqueous chambers would cause venous congestion, subsequent swelling of the ciliary body, overdistention of the vitreous, with the result of pushing the periphery of the iris against the sclerocorneal junction, thus blocking up the iris angle. But no explanation of the production of glaucoma satisfactorily fits all types of the disease; probably they are not all developed in the same manner.

Differential Diagnosis.—The *congestive form* of glaucoma has been mistaken for *iritis* and *conjunctivitis;* the use of atropine in such cases has caused great mischief. The dilated pupil, increase in tension, shallow anterior chamber, steamy cornea, as well as the subjective symptoms ought to be sufficient to differentiate (see tables on p. 167). The peculiar greenish pupillary reflex has been diagnosed as *cataract*, and thus valuable time has been lost in awaiting the ripening of this supposed lens change. In acute cases, the violent headache and general constitutional symptoms have misled the medical practitioner, and been responsible for the diagnosis of some *general febrile disease*, at a time when active ocular treatment was urgent.

Simple glaucoma is sometimes mistaken for *simple optic-nerve atrophy*. In the latter case, there will be absence of increased tension; the excavation of the disc is shallow and gradual (Figs. 186, 187, and Plates XV and XXI); there is apt to be greater diminution in central vision; the form fields present more uniform contraction; the color fields show greater peripheric loss, while in simple glaucoma they correspond in extent to the form field; and there is an absence of scotoma directly continuous with the blind spot. There are, however, instances in which the differential diagnosis between these two affections is not easy, particularly when

the increase of tension is very slight or happens to be temporarily absent.

Prognosis is bad in every case, if proper treatment is not instituted; vision becomes worse, more or less rapidly, but progressively, until complete blindness results. With correct treatment the prognosis is more favorable; it depends upon the type of disease, being most favorable in acute cases detected and treated *early;* in chronic forms the chances are influenced by the amount of degenerative change which exists when the patient first applies for treatment.

Treatment.—(1) Operative, (2) non-operative, and (3) general.

Operative Treatment consists of *iridectomy* (the excision of a portion of the iris), *sclerotomy* (an incision through the sclera), and various procedures having for their object the production of a cystoid scar or *filtering cicatrix.*

Operative intervention is, in general terms, the most satisfactory treatment for glaucoma, certainly the congestive type, and probably also for the simple form, especially when increased tension is at all prominent. Until recently, iridectomy was the operation of choice and the one resorted to almost exclusively. Since a few years, however, various procedures having for their object the production of a filtering cicatrix in the sclera, just beyond the limbus, have been used extensively. The most prominent of these are *Lagrange's operation* (sclerectomy combined with iridectomy), *Herbert's operation* (subconjunctival sclerotomy combined with iridectomy) and *Elliot's operation* (*trephining* the sclera combined with iridectomy), described on p. 216; of these the last has been most favored. These operations have been resorted to frequently for all forms of glaucoma excepting the acute congestive type in which most operators still prefer iridectomy. But, notwithstanding the conceded usefulness of these procedures, iridectomy still remains the most popular operation for glaucoma, especially since cataract and late infections of the eyeball have occurred in a sufficient proportion of cases to constitute a handicap which has to be considered; these late infections are made possible by the thin

barrier between the conjunctival sac and the interior of the eyeball existing at the seat of the scleral defect.

Non-Operative Treatment consists chiefly in the local use of the *miotics—eserine salicylate* ($\frac{1}{4}$ to $\frac{1}{2}$ per cent.), and *pilocarpine muriate* (1 to 2 per cent.). The former has the stronger action, but produces more irritation, especially when used for a long time. These solutions are instilled two or three times a day or oftener; they act by drawing the iris away from the angle of the anterior chamber; hence, they are of no value after the iris has become atrophic and is incapable of contracting, a condition observed in old cases of glaucoma. They are often merely palliative measures of temporary advantage. They may be used in the *prodromal stage* to cut short the attack, or at other times, if for any reason iridectomy is inadvisable, cannot be performed, or the patient refuses an operation. They are also useful in *acute inflammatory attacks* to alleviate pain, reduce tension, diminish cloudiness of the media and increase the depth of the anterior chamber, thus rendering iridectomy easier of execution. There are many ophthalmologists who rely upon miotics, in preference to operation, in simple glaucoma in which there is but little increase of tension.

During an *acute glaucomatous attack*, in addition to frequent instillations of *eserine* and pilocarpine, warm, moist *compresses* are applied, and several *leeches* to the temple are of value; the patient is quieted and pain relieved by *morphine* and large doses of *sodium salicylate*. Dionine also acts well.

Massage of the eyeball, applied gently to the closed lids, may be used with advantage in simple and in chronic forms.

General Treatment comprises rest, sweating, proper and sufficient food, salicylate of sodium, relief of constipation, correction of ametropia, avoidance of excess in eating, drinking, and late hours, the induction of sleep, and the relief of any of the other conditions which have been mentioned as predisposing to glaucoma. Nitroglycerine is useful if there exists high blood-pressure.

Iridectomy.—*The Instruments Required* include an eye speculum (Fig. 191), a fixation forceps (Fig. 192), a bent and

a straight lance-shaped knife (Fig. 193) or a Graefe cataract knife (Fig. 194), a curved iris forceps (Fig. 195), curved iris

Fig. 191.—Eye Speculum.

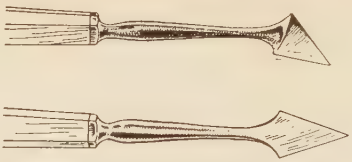

Fig. 193.—Bent and Straight Keratomes.

Fig. 194.—Graefe Knife.

Fig. 198.—Iris Repositor.

Fig. 199.—Iris Hook.

Fig. 192.—Fixation Forceps.

Fig. 195. –Curved Iris Forceps.

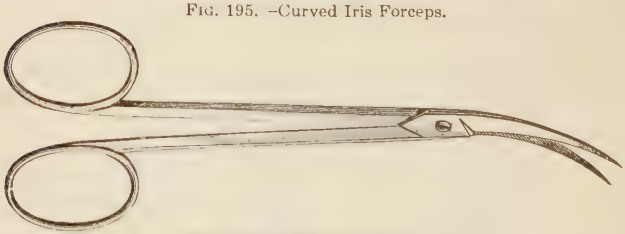

Fig. 196.—Curved Iris Scissors.

Fig. 197.—De Wecker's Iris Scissors.

Figs. 191–199.—Instruments Required for Iridectomy.

scissors (Fig. 196) or De Wecker's iris scissors (Fig. 197), an iris repositor (Fig. 198), and a blunt iris hook (Fig. 199).

The operation will be described as performed for glaucoma. *Cocaine* or *holocain* may be employed in simple glaucoma and in some cases of inflammatory glaucoma; but in nervous and unruly individuals, as well as in many instances of the congestive forms of glaucoma, *general anæsthesia* is necessary, since the tense and congested tissues do not readily absorb local anæsthetics, and the seizing and cutting of the iris are painful. A few drops of a 4 per cent. solution of cocaine injected subconjunctivally, below and above the cornea, increase the local anæsthesia.

Operation.—Iridectomy for glaucoma is usually done *upward*, so that the defect is covered by the upper lid, thus limiting troublesome optical effects of the coloboma. The

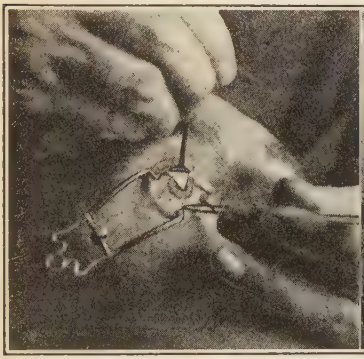

FIG. 200.—Section of the Sclera in Iridectomy.

FIG. 201.—Division of the Iris in Iridectomy.

operator, standing behind the patient's head, introduces the speculum, obtains a firm grasp of the conjunctiva just below the lower margin of the cornea, directs the patient to look down, and thrusts the lance-shaped knife into the sclera above the cornea, entering 1½ mm. behind the limbus (Figs. 200 and 202); the knife is directed perpendicularly until its point is seen in the anterior chamber, and then pushed forward in a direction parallel to the plane of the iris until the scleral wound is of sufficient size (6 to 8 mm.); care is taken not to pass between the layers of the cornea, nor to wound the iris or lens capsule. The knife should be *withdrawn slowly* so that the reduction in tension is not too sudden, which might cause

intraocular hemorrhage and other injury; its point is directed toward the cornea without scraping its posterior surface. When there are considerable increase in tension and a very

FIG. 202. — Iridectomy; Scleral Section.

FIG. 203. — Iridectomy; Grasping the Iris.

FIG. 204. — Iridectomy; Excision of the Piece of Iris.

shallow anterior chamber, the Graefe knife is often preferred for the scleral incision; it is made to enter 1 mm. behind the limbus, at about the junction of the lower five-sixths with the upper sixth, passes across the anterior chamber (great care being exercised not to wound the iris or lens capsule), and emerges at a corresponding point 1 mm. behind the limbus on the opposite side, the incision being completed by to-and-fro movements.

An assistant now takes the fixation forceps. The operator passes the closed iris forceps through the scleral incision to the pupillary margin (Fig. 203), opens the instrument, seizes the pupillary border of the iris between its branches, draws the iris out of the wound, and cuts it off close to the cornea, the blades of the iris scissors being parallel to the wound (Figs. 201 and 204). The piece of iris removed (Fig. 205) should comprise the entire width including the ciliary attachment.

In iridectomy performed on an aphakial eye (after cataract operations), it is difficult to grasp the iris with forceps; in such cases the iris is drawn out with the blunt hook (Fig. 199).

The resulting *coloboma* must be large, cleanly cut, and the pupillary margin of the iris must return to its natural position

producing a *keyhole-shaped pupil* (Fig. 205). No iris tissue must be left in the wound, since this causes subsequent irritation and complications. Proper replacement of the iris is accomplished by stroking the wound with the iris repositor (Fig. 198), and by passing the latter into the incision and freeing the angles.

Fig. 205. Fig. 206. Fig. 207.

Fig. 205.—Iridectomy in Glaucoma. Fig. 206, Iridectomy Preceding Cataract Extraction. Fig. 207, Iridectomy for Artificial Pupil.

Hemorrhage into the anterior chamber is common; the blood is usually absorbed in a few days; it is not wise to make too great efforts to dislodge the blood, since undue pressure may cause the lens to become cataractous. Sometimes retinal hemorrhages occur and are subsequently absorbed, doing no damage unless they involve the macular region.

Both eyes are bandaged, and the patient is kept quiet in bed. After a day, the unoperated eye may be left uncovered. Recovery is smooth in most instances; in some cases the anterior chamber is not re-formed for several days. Cystoid cicatrix sometimes results—a condition which is not objectionable and is thought to facilitate filtration.

Results of Iridectomy in Glaucoma.—The manner in which iridectomy relieves glaucoma is not definitely known. The *earlier* the operation is performed, the more sight is preserved. Hence it is advisable to do the operation *as soon as possible*. The best time is during the prodromal stage, in the interval between attacks. In congestive cases, during the stage of acute glaucoma, the operation is very difficult on account of the severe congestion and the shallowness of the anterior chamber; under such circumstances, it is usually advisable to instil eserine or pilocarpine at frequent intervals and to treat the patient in the manner already described for a day or two, so as to reduce tension and increase the depth of the anterior chamber, and then to operate; but if these miotics do not act, the operation must be performed without further delay.

The most favorable results of iridectomy are seen in cases of *acute congestive glaucoma;* in such instances pain and inflammatory symptoms subside rapidly and sight returns up to the degree possessed before the onset of the attack. Furthermore, the results are generally *lasting.* Exceptionally the effects of an iridectomy are disappointing or temporary, and the operation must be repeated opposite to or at the side of the first, or sclerectomy performed. In rare cases operation has no effect upon the course of acute inflammatory glaucoma, and the disease progresses until blindness ensues.

In chronic congestive glaucoma, the results of iridectomy are favorable, but not so brilliant as in acute cases. The operation relieves the pain and inflammatory symptoms, and the media again become clear; but since the disease has already caused permanent changes in the disc and optic nerve, the restoration of sight is limited. But the *progress of the disease is generally checked,* though sometimes a second operation must be performed. In a certain number of cases, however, there is progressive diminution in sight notwithstanding the operative intervention.

In simple glaucoma iridectomy is also indicated, but its results are *less marked and less permanent* than in the congestive variety. The most that we can expect from the operation is that the acuteness of vision prevailing at that time will be preserved or slightly increased, and that the progress of the disease will be arrested. This happens in about one-half of the cases. In the other half the results are not so favorable. In some of these, the effects of the operation are only temporary and the iridectomy has to be repeated; in others, the disease progresses after a shorter or longer interval of arrest, and blindness finally ensues. In a very small proportion, the operation has an unfavorable effect upon the disease; violent inflammatory symptoms appear immediately or soon after the operation and the eye rapidly becomes blind; such cases are known as *malignant glaucoma.*

In *absolute glaucoma,* enucleation is often indicated for the relief of severe pain.

Indications for Iridectomy.—Besides (1) glaucoma, the

operation is indicated in (2) some cases of chronic and recurrent iritis and iridocyclitis; (3) complete circular synechia; (4) partial corneal staphyloma; (5) tumors and foreign bodies in the iris; (6) recent prolapse of the iris; (7) as a part of the operation of extraction of cataract—here the coloboma should be smaller than in glaucoma (Fig. 206); (8) as a means of improving sight (artificial pupil, optical iridectomy) in central opacities of the cornea and lens, occlusion of the pupil, and keratoconus.

Optical Iridectomy: A small incision (3 to 4 mm.) is made in the cornea, 2 mm. from the limbus, the iris drawn out with the iris forceps (Fig. 195) or the blunt hook (Fig. 199), and its pupillary portion excised, making as *small* a coloboma as answers the purpose (Fig. 207). The best position for the artificial pupil is *downward and inward;* but when there is a corneal opacity, the site must correspond to the most transparent portion of the cornea. The effects of optical iridectomy are often disappointing; hence, before operating, it is well to dilate the pupil and, by applying a stenopæic slit held in different positions, to ascertain whether there is an improvement in sight under these circumstances.

Sclerotomy (*Incision Through the Sclera*) is sometimes performed for the cure of glaucoma, but it is considered inferior to iridectomy. It may, however, be a useful procedure in cases in which iridectomy cannot be satisfactorily performed, or in which a relapse occurs after iridectomy has been done once or twice. The incision in the sclera is made in two situations: in front of the iris (anterior sclerotomy), and behind the ciliary body (posterior sclerotomy).

Anterior Sclerotomy: Puncture and counterpuncture are made with a Graefe knife, 1 mm. behind the limbus, similar to those made in cataract extraction except that the corneal flap is but 2 mm. high; the middle third is, however, left uncut and forms a bridge connecting sclera and cornea.

Posterior Sclerotomy (Scleral Puncture): An incision (5 mm. deep) is made through the sclera into the vitreous with a Graefe knife, between the external and inferior recti muscles, 10 mm. from the corneal margin, the point being directed

toward the centre of the globe; care should be taken to select a spot free from larger blood-vessels; before withdrawing the knife it is turned slightly on its axis so as to widen the puncture. This operation is employed in hemorrhagic glaucoma, in detachment of the retina (in which case the puncture is made over the separation), and as a preliminary step in the removal of foreign bodies from the vitreous. An additional indication is for the purpose of lowering the tension and increasing the depth of the anterior chamber in very hard glaucomatous eyes, thus facilitating subsequent iridectomy.

Filtering Cicatrix Operations.—Disappointment with iridectomy in chronic congestive and simple glaucoma has prompted operations having for their object the formation of a permanent, filtering cicatrix. Most promising and popular of these are Elliot's (trephining) and Lagrange's (sclerectomy with iridectomy). These operations are used considerably, particularly in chronic cases, and often when a previous iridectomy has not succeeded in keeping down the tension.

Elliot's Operation (Sclerocorneal Trephining).—A large triangular conjunctival flap is dissected from above the cornea concentric with the limbus, the connective tissue at the angles of the flap being left intact. The central portion of the flap is dissected from the sclera down to the limbus, keeping the episcleral tissue adherent to the flap as the limbus is approached. Next, the flap is drawn gently downward over the cornea and the latter split for a distance of 1 mm. with closed scissors-points, by means of a number of short lateral strokes, along the line of attachment of the conjunctival flap (Fig. 208). As the dissection proceeds, the deeper layers of the split cornea can be seen as a dark crescentic area. Having prepared sufficient space, the trephine (Fig. 209), 1.5 to 2 mm. in diameter, is applied at the limbus, cutting through cornea first, and a button of sclero-corneal tissue removed. As soon as the tre-



FIG. 208.—Elliot's Operation for Glaucoma.

phine has cut its way through, the disc, hinged on its scleral side, will be pushed upward and backward by a bead of iris prolapsing through the corneal side of the opening. Grasping both disc and bead of iris in one grip of the forceps, these are excised together with a single snip of the scissors. The iris must be replaced and no tags of uvea left in the wound; to insure this we use a small irrigator and direct a stream of saline solution into the anterior chamber. The conjunctival flap is replaced, no sutures being used unless it shows a tendency to become displaced. Both eyes are bandaged. On the third day, if the tension is down, 1 per cent. atropine is instilled, unless the pupil is widely dilated and active.

FIG. 209.—Scleral Trephine.

Lagrange's Operation (Sclerectomy combined with Iridectomy).—In addition to the instruments used for iridectomy, small sharp scissors with a marked curve on the flat are needed. With a Graefe knife the sclera is punctured 1 mm. from the limbus and counterpunctured at a corresponding point 7 mm. removed. The incision is made in the iris angle, and at its termination the edge of the knife is directed backward so as to bevel the sclera, then continuing so as to make a 5 mm. conjunctival flap. The latter is drawn forward, thus tilting the edge of the scleral flap upward, and a piece of the latter exsected with the curved scissors. Iridectomy is performed, and finally the scleral defect is covered by the conjunctival flap.

Cyclodialysis (Heine's Operation) consists of an incision in the sclera 8 mm. behind limbus, separating ciliary body from overlying sclera and breaking through the pectinate ligament, thus detaching a portion of the periphery of the iris. The artificial communication between anterior chamber and suprachoroidal space thus made forms a new channel for the escape of aqueous. This procedure may be done in advanced glaucoma or when other operations have failed, but cannot ordinarily be regarded as a substitute for iridectomy or other operations for glaucoma.

Other operations which have been advocated and performed at times for the cure of glaucoma, include Holth's Sclerectomy with punch forceps, and Iridotasis, in which the iris is withdrawn through a scleral opening and allowed to remain permanently under a previously made conjunctival flap.

Secondary Glaucoma is the name given to cases of increased tension and other symptoms of glaucoma developing as a result of some other ocular disease or injury. The clinical picture varies with the disease which it complicates. The course is either acute or chronic and the consequences are the same as in primary glaucoma.

The ocular affections which are most frequently followed by secondary glaucoma are: Ulcers or wounds of the cornea with prolapse of iris, corneal cicatrices and staphylomata with incarceration of the iris, iridocyclitis, uveitis and choroiditis, total posterior (ring) synechia, dislocation of the lens, traumatic cataract (swelling of the lens), the operations of extraction, needling of the lens and discission of secondary cataract, intraocular tumors, and foreign bodies in the eye. In old persons with arteriosclerosis, a form of secondary glaucoma with retinal hemorrhages is seen, and is known as *hemorrhagic glaucoma.*

Treatment is similar, in general, to that required for primary glaucoma, modified by the nature of the cause and its removal. Hemorrhagic glaucoma does not respond favorably to treatment; iridectomy is liable to be followed by an aggravation of symptoms; posterior sclerotomy may be of service; the other agents used in glaucoma may be tried, but are often of no benefit.

Congenital Glaucoma (Hydrophthalmos, Buphthalmos, Keratoglobus) is a disease of *early childhood*, either congenital or developing in infancy and usually involving both eyes. There is an *increase of intraocular tension* which, on account of the yielding character of the sclera at this period of life, causes marked *enlargement of the eyeball.* The cornea is enlarged and bulging, and either remains clear or becomes clouded; the anterior chamber is very deep; the pupil is dilated, and the iris atrophied and tremulous; the sclera is

thinned and bluish, owing to the uveal pigment showing through; the disc is deeply excavated. The disease *progresses slowly*. Though in some cases it comes to a spontaneous stop with the preservation of moderately good vision, it generally leads to *blindness*. The prognosis in general is *unfavorable* and treatment is often disappointing; since, however, some cases are benefited by iridectomy or sclero-corneal trephining together with the use of miotics, these measures should be tried.

CHAPTER XVI

DISEASES OF THE VITREOUS

Anatomy.—The vitreous is a *transparent*, colorless mass, of soft *gelatinous* consistence, which fills the posterior cavity of the eyeball behind the lens. Its outer surface presents a thin, structureless covering, the *hyaloid membrane*. The vitreous is traversed from the optic disc to the posterior capsule of the lens by a canal, the *hyaloid canal*, serving as a lymph channel in the developed eye, and containing the hyaloid artery during fœtal life. In structure the vitreous consists of a *transparent network*, in the meshes of which are *clear liquid* and round and branching *cells*, probably emigrated white blood-corpuscles. The vitreous has no blood-vessels, but receives its nourishment from the surrounding tissues: the choroid, ciliary body, and retina.

Persistent Hyaloid Artery.—The hyaloid artery usually disappears entirely during the later months of gestation. Occasionally a greater or lesser remnant persists during life. This can be seen with the ophthalmoscope, as a *grayish cord or thread*, which arises from the optic disc and stretches into the vitreous, with a free extremity or occasionally attached to the posterior pole of the lens; sometimes there is an accompanying opacity of the posterior portion of the lens. Rarely, the hyaloid canal is abnormally dense and is visible as a grayish, tubular cord extending from disc to lens.

The principal affections of the vitreous are fluidity, opacities, muscæ volitantes, hemorrhages, abscess, and foreign bodies. Since this structure is devoid of blood-vessels, primary inflammation does not occur; hence the term *hyalitis*, sometimes used, is incorrect.

Fluidity of the Vitreous (*Synchysis*) is a liquid alteration in consistency which, when limited in degree, may be merely a senile change; but when pronounced, it is due to degeneration of this structure dependent upon disease of neighboring parts: choroid, ciliary body and retina, and found often in myopia of high degree. When opacities are present, these are observed to move freely in such fluid vitreous; there is often diminished tension of the eyeball, tremulousness of the iris, and sometimes a predisposition to detachment of the

retina. Occasionally small glistening opacities are found in degenerated eyeballs and in some which are normal in other respects, especially in old persons; they fall in a silvery shower when the eyeball is moved; they are usually crystals of cholesterin in a fluid vitreous; the appearance is known as *Synchysis Scintillans.*

Opacities of the Vitreous are quite common. They may occur as a consequence of changes in the vitreous itself, but usually they are the result of disease or of hemorrhages from the *neighboring structures*—ciliary body, choroid, and retina. They may be fixed or mobile and vary in number, shape, and size: (1) A diffuse *cloud* or a *dust-like* haziness often accompanies cyclitis, choroiditis, iridochoroiditis, and retinitis; when dust-like it is suggestive of syphilitic origin. (2) The opacities may occur in the form of dots, flakes, threads, or membranous masses, the result of exudations or hemorrhages. (3) Sometimes extensive *membranes* are met with, which are attached to the retina and provided with blood-vessels; these are supposed to result from chronic retinal disease, called *Retinitis Proliferans.*

Etiology.—Opacities of the vitreous are very common in *myopia* of high degree associated with changes in the choroid; they are often seen accompanying *diseases of the uvea* and retina; they occur after injuries which have caused *hemorrhage* from the choroid or ciliary body; they may result from certain systemic diseases; and they may exist in patients in whom we can find no cause and no evidence of ocular disease, especially in the aged.

Symptoms.—There is more or less *disturbance of vision,* depending upon the situation, size, and density of the opacities. The latter are most frequently movable, indicating a fluid vitreous (*synchysis*), the result of disease of surrounding parts; on this account, the visual disturbance may vary at different times according to whether the opacity happens to have gravitated into the line of vision, and the patient may be able to move the eyeball in a certain way so as to throw the opacity out of the line of sight.

Diagnosis is made with the *ophthalmoscope* at a distance.

The vitreous opacities appear as *dark spots* upon a red ground, moving with greater or lesser rapidity, depending upon the consistence of the vitreous, when the eye is turned in various directions. When faint, the opacities are best seen with diminished illumination and with the plane mirror. They may also be examined by the direct method of ophthalmoscopy, by interposing stronger and stronger convex lenses in the sight-hole of the ophthalmoscope, and thus focussing more and more anterior portions of the vitreous cavity.

Prognosis *varies* with the size, density, and nature of the opacity. Syphilitic opacities and small hemorrhages frequently clear up when treated early. Others become smaller and less dense after a time. A great many are permanent.

Treatment.—*Anti-syphilitic* treatment is indicated in specific cases. In others, small doses of potassium *iodide* and *mercury* may be of service; also other forms of *iodine* medication. Diaphoretics and cathartics are often employed. *Subconjunctival injections* of physiological salt solution (0.6 per cent.) may be useful.

Muscae Volitantes is the term employed for the appearance of *spots* (motes) before the eyes, *without appreciable structural change* in the vitreous or other media. They are caused by the shadows cast upon the retina by the cells normally found in the vitreous, and are present in all eyes under certain circumstances, such as exposure to a uniform bright surface, or in looking through a microscope. They are found more frequently in *errors of refraction* (especially *myopia*), and the symptom may be aggravated temporarily during digestive derangements. They occur as grayish shadows, which move with changes in the position of the eyes, having the shape of dots or globules frequently collected into strings; they may have any shape. They are *annoying* and sometimes alarm the patient, but are of *no importance*, and do not affect the acuteness of vision. The treatment consists in correcting errors of refraction, or in relieving the disturbance of digestion. They often persist until the patient ceases to look for them and thus forgets their existence.

Hemorrhages into the Vitreous come from the cho-

roidal, retinal, and ciliary body vessels and produce *interference with vision*, the degree depending upon their size. When small, they have a red color as seen with the ophthalmoscope; when larger they appear as dark-red masses; and when very extensive they fill the vitreous cavity and no red reflex can be obtained with the ophthalmoscope, the pupil appearing black. Smaller hemorrhages are often absorbed; larger ones are apt to result in permanent membranous masses.

Hemorrhages into the vitreous occur after *injuries*, complicating *choroiditis* and retinitis, in high myopia and in glaucoma, as an example of vicarious menstruation, in arteriosclerosis and other *systemic disorders*, such as anæmia, nephritis and diabetes, and finally spontaneously from unknown cause. The exciting cause may be a strain of some kind, such as a cough.

One form occurs in *young adults*, usually males, with unknown etiology except that tuberculosis is thought to be a factor, presents frequent recurrences, and is apt to lead to serious results, since the blood is imperfectly absorbed; large masses of connective tissue form, and these may cause subsequent detachment of the retina.

Treatment consists of rest, attention to the predisposing systemic affection, reduction of *blood-pressure* if elevated, and *calcium* chloride to prevent recurrences. Later, in order to favor absorption, iodides and *iodine* preparations, mercury, diaphoresis, cathartics, and *subconjunctival injections* of normal saline solution.

Abscess of the Vitreous is a term used to designate those cases of suppurative iridochoroiditis in which the *purulent exudate* remains *confined* to the vitreous and choroid, and does not spread to all the structures of the eye causing panophthalmitis. This condition is described on p. 186.

Foreign Bodies in the Vitreous.—The entrance and lodgment of a foreign body (metal, glass, wood) within the globe usually causes *severe inflammation* and *destruction* of the eyeball as a result of iridocyclitis or panophthalmitis unless the substance be promptly extracted; the gravity of the accident depends upon the nature of the foreign body and the

presence or absence of *infection*. Occasionally these substances, when small and free from infection, remain quiescent and become encysted; but even in such cases there is danger of subsequent inflammation.

The presence of a particle of iron for any length of time is apt to cause a rusty-brown or greenish discoloration of the iris and lens, known as *siderosis*.

Diagnosis.—The foreign body may have dropped to the *bottom* of the vitreous cavity, become embedded in the *walls*, or passed through the eyeball and be located in the *orbit*. If the patient comes under observation soon after the injury, before the media have become hazy, we may be able to see the particle with the *ophthalmoscope;* and a careful examination of the field of vision, disclosing a *scotoma*, may also locate it; this information will be corroborated by a study of the site of the wound of *entrance* and the probable *direction* which the foreign body took. In most instances, a *radiograph* will reveal its presence and position. If it be of iron or steel, the giant *magnet* (Fig. 210) will frequently indicate its presence by the production of pain when the point is brought near the eyeball, or by the bulging of the iris or the forward movement of the lens when the particle is within these structures. The use of the *sideroscope*, a magnetic needle suspended upon a silk thread, will also aid in the diagnosis and localization, the deflection of the needle increasing as it approaches the foreign body.

Treatment.—If the substance is a piece of *iron or steel*, an attempt to extract it with a *magnet* should be made at once. We should also try to remove *other foreign bodies* (glass, wood, copper, lead) as soon as possible after they have been located, by means of delicate *forceps;* these are introduced through the original wound or through an opening into the vitreous cavity made at the point at which the foreign body has been located. But if this is not accomplished promptly, and very often it is unsuccessful, we should allow the foreign body to remain rather than stir up the vitreous, especially if there be no symptoms of infection or irritation, and the patient can be kept under constant observation; in such

cases, however, the question of enucleation may come up for consideration at any time (p. 88).

Magnet Extraction.—Instruments used for the extraction of particles of iron or steel are of two kinds: (1) Medium-sized, or *portable* electro-magnets (Hirshberg's, Johnson's, Sweet's), and (2) large, or *stationary* electro-magnets (Haab's, Volkman's). In using the former (Fig. 211), the point of the

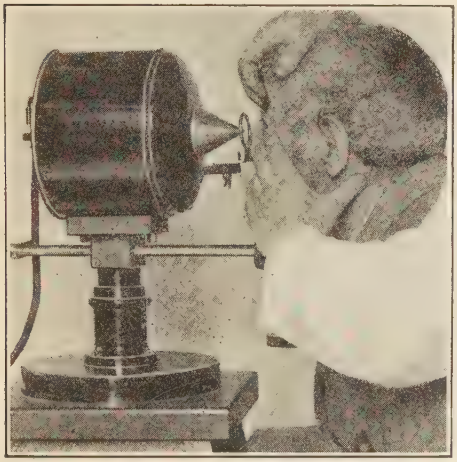

FIG. 210.—Haab's Giant Electro-Magnet.

FIG. 211.—Medium-Sized, Portable Electro-Magnet.

magnet is held at the entrance wound, or the opening made at the location of the foreign body, preferably without penetrating into the vitreous cavity, and then the current is turned on. If the giant magnet be employed, the patient approaches the magnet, the eye is brought toward the point of the instrument (Fig. 210), and the current gradually turned on; the particle of iron or steel may be drawn out through the original wound, or an attempt made to draw it from the vitreous, around the lens, into the anterior chamber, from which it is then removed through a corneal incision.

Even after successful extraction, the *prognosis* is always *serious;* about one-third of the patients recover useful vision; in quite a number the form of the eyeball is preserved; in

many cases destructive inflammation supervenes. If the attempt at extraction fails, enucleation is usually necessary.

If the eye presents evidence of *infection* when first seen or after the foreign body has been extracted, we cannot hope to save the organ. Attempts have been made to check the process by the introduction of rods of iodoform into the aqueous and vitreous cavities, or through galvanocauterization of lips of the wound and adjacent parts, or by repeated irrigation of the aqueous and even the vitreous cavities; but, as a rule, such procedures are futile and the eye must be removed.

CHAPTER XVII

DISEASES OF THE LENS

Anatomy and Physiology.—The *crystalline lens* is a *transparent*, colorless body, *biconvex* in shape, measuring 5 mm. in thickness and 9 mm. in diameter in the adult, suspended in the anterior portion of the eyeball between the aqueous and the vitreous chambers. It presents an anterior and a posterior surface, the latter being the more curved, an anterior pole, a posterior pole, and a rounded circumference, the equator. It is devoid of blood-vessels except in fœtal life, its nourishment being derived from the ciliary body. It is enclosed in a transparent *capsule*, and held in position by its *suspensory ligament*. The adult lens consists of a peripheral portion, the *cortex*, and a central part, the *nucleus*. The cortex is semi-solid, softer than the nucleus, and colorless; the nucleus is harder and has a yellowish tint; there is, however, no sharp limitation, the transition being gradual. The nucleus increases in size with advancing years, and the cortex diminishes in proportion; in old age the entire lens is of the consistence of the nucleus and is hard and unyielding; this change is known as *sclerosis*.

In *structure* the lens consists of concentric *laminæ* formed of long, *hexagonal fibres*, the edges of which are connected by a cement substance, leaving fine lymph channels. The fibres either start or end along *Y-shaped or stellate figures*, the lines of which radiate from the anterior and posterior pole to the equator, each fibre encircling the latter; the septa corresponding to the branches of the stellate figure divide the lens into *sectors*. These stellate and Y-shaped figures can often be recognized in the adult lens by oblique illumination.

The capsule of the lens is a thin, homogeneous, elastic membrane which covers the lens, being known as the *anterior capsule* in front, and as the *posterior capsule* behind. The anterior capsule is the thicker, and its posterior surface is lined by a layer of cuboidal epithelium from which the lens fibres are formed.

The suspensory ligament of the lens is a delicate membrane, extending from the ciliary body to the lens capsule. It covers the inner surface of the ciliary body from the ora serrata to the apices of the ciliary processes, and then passes to the lens, dividing into three layers attached respectively to the anterior capsule, the equator, and the posterior capsule. Between these layers and the equator of the lens is an annular space, triangular on section, known as the canal of Petit; it communicates with the posterior chamber by means of slit-like apertures between the fibres of the anterior portion of the suspensory ligament.

The *function* of the lens is to *focus rays* so that they form a perfect image on the retina. To accomplish this, the refractive power of the lens must change with the distance of the object, according to whether the rays are parallel or divergent. This alteration in the refractive power of the lens is known as *accommodation*, and is produced by a change of shape mainly affecting its anterior curvature.

The lens presents variations in physical characteristics at different periods of life. *In the fœtus*, it is nearly spherical, slightly reddish, and softer than at a later period. *In the adult*, its anterior surface is less convex than the posterior, and its substance is firmer. *Sclerosis*, which consists of a process of toughening, due chiefly to loss of water, begins in the centre of the lens in childhood and advances slowly until adult life, after which its progress is more rapid, increasing the size of the nucleus at the expense of the cortex. *In old age*, the lens increases in size, is flattened, and assumes a *yellow* tinge, becoming tougher and less transparent; this process of sclerosis accounts for the *gray reflex* seen in the pupil of the aged, which may be mistaken for cataract (*senile reflex*); it also explains the inability on the part of the lens of advanced years to change its shape for the purposes of accommodation (*presbyopia*).

CATARACT

A cataract is any *opacity of the lens* or of its capsule or of both.

Varieties.—Cataracts may be divided into: (1) *Primary*, and (2) *secondary* to some other disease of the eye.

Cataracts are divided *anatomically* into: (1) *Lenticular*, situated in the substance of the lens; (2) *capsular*, affecting the capsule; (3) *capsulo-lenticular*, involving both lens and capsule.

According to *consistence*, they may be (1) *hard*, (2) *soft*, and (3) *fluid*.

They are also known as (1) *partial*, limited to some part of the lens; (2) *complete*, involving the whole lens; (3) *stationary*, when they remain incomplete; and (4) *progressive*, when they spread and tend to affect the whole lens.

Stationary cataracts include: (1) *Anterior polar*, (2) *posterior polar*, (3) *lamellar*, and (4) *various uncommon forms*.

Progressive cataracts may be : (1) Senile, a. cortical, b. nuclear; (2) congenital and juvenile, and (3) traumatic.

A convenient *clinical classification* of cataracts is the following:

1. Senile.
2. Congenital.
3. Juvenile.
4. Anterior Polar.
5. Posterior Polar.
6. Lamellar.
7. Various uncommon forms: a. central.
   b. fusiform.
   c. punctate.
8. Complicated.
9. After-cataract.

In patients *under thirty-five* all cataracts are of soft consistence throughout and white in color; such cataracts have no hard nucleus and are known as *soft cataracts*. After this period the nucleus becomes hard and of a yellowish tint, and the lenticular opacity is known as *hard cataract*.

Etiology.—According to etiology, cataract may be:

1. *Congenital,* due to faulty development or intra-uterine inflammation of the eye. To this class belong anterior and posterior polar, lamellar, and congenital complete cataracts.

2. *Senile;* this is the most common form. It usually appears after the age of fifty. Cataract is not considered a physiological but a pathological process; age is but a predisposing factor.

3. *Heredity* has some influence in the occurrence of cataract.

4. *General Diseases;* diabetes is the most common example; much less frequently, nephritis.

5. *Occupation;* cataract occurs frequently in glass-blowers and others exposed to great heat.

6. *Traumatic,* by the production of an opening in the capsule, thus allowing the lens to absorb aqueous; occasionally by mere *concussion,* lightning stroke, or severe electric shock.

7. *Ocular Diseases,* causing complicated or secondary cataract; the most common examples are infected corneal ulcers, iridocyclitis, choroiditis, myopia of high degree, glaucoma, and detachment of the retina.

8. *Errors of Refraction* seem to predispose, since most cataract patients have hyperopia and hyperopic astigmatism.

Symptoms.—There is (1) *diminished acuteness of vision,* depending upon the situation and extent of the cataract. It is greatest when the opacity is central and diffuse, and least when the cataract is peripheral. When central, the patient sees best in dim light—with dilatation of the pupil. The interference with vision increases with the progress of the cataract, until finally there is mere perception of light. (2) In the incipient stage, the patient may complain of seeing *spots* which occupy a fixed position in the field. (3) Occasionally there is annoying diplopia or polyopia, due to irregular refraction of the lens. (4) Myopia often develops during the early stages, due to increased refractive power of the lens; for this reason the patient may be able to discard his reading-glasses for the time; this condition is popularly known as *"second sight";* at the same time his vision for distance may be improved with concave lenses, and there may be added astigmatism.

Physical Signs.—There are no inflammatory symptoms. During the incipient stage, examination by *oblique illumination* will show a *grayish* or *whitish opacity* on a black ground, and with the *ophthalmoscope* at a distance a *black opacity upon a red field* (Plate II). The pupil should be *dilated*, especially in the incipient stage. Later the entire pupil will appear grayish and there will be an absence of fundus reflex. During the stage of swelling the anterior chamber is reduced in depth.

SENILE CATARACT

Senile or Simple Cataract is the most *frequent* form of cataract. It is quite common after the fiftieth year; occasionally it is seen as early as forty. Almost always *both eyes* are involved, but generally one in advance of the other. The opacity may begin either in the cortex (*cortical*, Figs. 212, and 28-29, Plate II), or in the nucleus (*nuclear*, Figs. 213, and 30-31, Plate II). As a rule, senile cataracts begin in the *cortex* and the nucleus remains transparent throughout. The time required for full *development varies* greatly; it may ripen completely in a few months or may require many years; it may become stationary at any stage of its progress.

The Stages of senile cataract are four in number:

1. *Incipient Stage.*—The opacity most frequently begins as *streaks* which extend *from the periphery* of the cortex, where they are wider, to the centre of the lens, where they narrow like the spokes of a wheel (Fig. 212); the periphery is affected first. These streaks appear *grayish* by oblique illumination, and *black* when seen with the ophthalmoscope. Between these sectors the lens is transparent. Less frequently, senile cataract begins with dot-like or cloud-like opacities situated in any portion of the lens; sometimes the portion immediately surrounding the cortex becomes opaque (and, exceptionally, the nucleus itself), constituting so-called *nuclear cataract* (Fig. 213); the last form causes relatively great visual disturbance. Cataracts sometimes remain *stationary* in the incipient stage, with little impairment of vision. Hence it is often wise not to alarm the patient by acquainting him with his condition, at the same time communicating the knowledge to a relative, for our own protection.

A *B* *C*

FIG. 212. —Senile Cortical Cataract. *A*, Seen with Oblique Illumination; *B*, Section of the Lens; *C*, Seen with the Ophthalmoscope.

A *B* *C*

FIG. 213.—Senile Nuclear Cataract. *A*, Seen with Oblique Illumination; *B*, Section of the Lens; *C*, Seen with the Ophthalmoscope.

2. *The Stage of Swelling* (*Immature Stage*).—The lens absorbs fluid, swells, pushes the iris forward, and *reduces* the depth of the *anterior chamber*. It appears *bluish-white*, shining, and presents distinctly the markings of the stellate figure. During this stage, the *iris casts a shadow upon the lens* when the eye is illuminated from the side, since the superficial portion of the lens is still transparent, and hence the opaque layer is some distance behind the iris.

3. *Mature Stage.*—The lens loses most of its fluid, shrinks somewhat, and becomes perfectly *opaque* and of a dull *gray or amber* color, the stellate markings still being recognizable. The *anterior chamber* regains its *normal* depth, and there is *no shadow* thrown by the iris on the lens with focal illumination.

Occasionally, the entire lens is changed into a hard, dark-brown mass (*black cataract*). In this stage, the cataract can easily be separated from the capsule of the lens; it is then said to be "*ripe*" for operation, since it can be extracted without leaving much if any of the cortex behind, thus diminishing the chances of subsequent opacity (after-cataract).

4. *Hypermature Stage.*—The cataract may continue in the mature stage for a long time. If changes continue, the surface of the lens loses its radial markings and becomes *homogeneous*, or presents irregular spots. The cataract may continue to lose water, and thus a shrunken, dry, flattened mass results (*shrunken cataract*), with some deepening of the anterior chamber. Or, the cortex may become soft, liquid, and milky, and the nucleus sink to the bottom of this fluid (*Morgagnian cataract*), the cataract appearing white with a brownish coloring below. Very old hypermature cataracts often present the deposit of *cholesterin* or of *lime* salts; the latter change (*chalky cataract*) is found chiefly in complicated cataracts. The anterior capsule may become thickened and opaque (capsulo-lenticular cataract). The lens (and iris) may become *tremulous* through stretching of the suspensory ligament. For these reasons, operation upon overripe cataract is less favorable and more difficult than when mature.

Pathology.—The following changes take place in the process of formation of senile cataract: At first there is *separation* of the lens fibres with the formation of drops of *fluid* in the spaces thus created; then the fibres *swell*, become *cloudy*, present an uneven calibre, and *disintegrate*. Finally the lens tissue is changed into a soft *mass* consisting of fat, drops of fluid, remains of lens fibres, and albuminous liquid; this mass becomes separated from the capsule by watery liquid. The *nucleus* usually suffers no change except sclerosis.

Treatment.—*Extraction* of the lens by operation is the *only means* for relieving a patient of senile cataract. No medicinal treatment, whether local or constitutional, is of curative value. There have been instances of the spontaneous clearing of cataracts during the incipient and even in the mature

stage; but such occurrences are so rare that they are considered curiosities.

In the incipient and maturing stages the eyes should be *rested* as much as possible, *correcting lenses* be worn if an error of refraction exists, deranged conditions of the system looked after, and *neighboring ocular disease* be treated. The patient should present himself for examination from time to time. In cases in which the opacity is central, sight may be improved temporarily by a weak solution of *atropine* ($\frac{1}{2}$ gr. to $\frac{7}{3}$ i.) or other mydriatic, the dilatation of the pupil permitting increased vision through the peripheral, transparent portion of the lens. The wearing of *smoked glasses* also accomplishes this to a lesser extent and is generally a source of comfort.

The most *favorable time for extraction* of senile cataract is when the lens is completely opaque and there is no shadow thrown by the iris—*i.e.*, when the cataract is *ripe*. If operated upon before this time, the lens is not always removed cleanly and some transparent cortex is apt to adhere to the capsule and be left behind; this becomes opaque subsequently, and is absorbed slowly, or an after-cataract develops necessitating another operation—discission; besides, the remains of cortex after extraction tend to produce irritation and interfere with smooth healing. However, with the modern practice of removing cortical remnants by irrigation of the anterior chamber, the disadvantages of operating upon immature cataracts have been lessened.

As a general rule, we operate when the cataract of one eye is *mature*, and the other has progressed far enough to cause considerable *interference with vision*. But there are a number of exceptions to this rule: For instance, when the occupation and circumstances of the patient are such that being unable to work, he cannot wait for the cataract of the first eye to become ripe; or when the cataract shows signs of hypermaturity before the second eye is very much affected. Removal of both cataracts should never be performed at one sitting. When both eyes are affected, useful vision may be abolished before either cataract is ripe.

Artificial Ripening is occasionally resorted to by pre-

liminary operations consisting of gentle massage applied to the lens directly, or through the cornea after an incision, with or without iridectomy; the lens becomes opaque after a few weeks. In *Preliminary capsulotomy* (Homer Smith) the capsule is opened by a knife-needle 6 hours before extraction, allowing the aqueous to penetrate and the cataract to swell and become separated from the capsule, so that it escapes in one mass when extracted. Ripening operations are not always reliable nor free from danger; it is generally considered better to remove the immature cataract than to resort to artificial ripening.

Simple Extraction and Combined Extraction.—Extraction may be performed *with* (*Combined* Extraction) or *without* (*Simple* Extraction) *an iridectomy;* the question as to which is preferable was formerly much discussed. *Combined extraction* is the operation of choice in the great majority of cases; it is always indicated when the iris interferes with the easy delivery of the lens or protrudes during the operation and does not stay reduced; when the lens is very large; when we suspect that the patient may not behave well after the operation; or when any ocular complications exist. *Simple extraction* is reserved for selected cases; it has the advantage of leaving a round pupil with slight improvement in vision and appearance; its disadvantage is the danger of *prolapse of the iris*, discovered at the first dressing and then requiring immediate abscission.

A *preliminary iridectomy* and extraction several weeks later is often resorted to as a means of *lessening the risks* of extraction when complications are feared and in operating upon immature cataract.

Monocular cataract is not generally removed, since, owing to the difference in refraction, the eyes will not work together. Extraction may, however, be performed in such cases for cosmetic effect, to prevent hypermaturity, and to extend the field of vision on the affected side.

Aphakia.—After extraction of cataract, the patient is compelled to wear *strong convex glasses*, since the loss of the lens (*aphakia*) causes a high degree of *hyperopia*, amounting to

about 10D, and with it there is usually considerable *astigmatism* (1 to 3D), generally "against the rule." In an average case, a convex spherical lens of about 10D, combined with a convex cylinder of 1 to 3D, must be worn for distant vision; to this, an additional convex sphere of 3 or 4D must be added for reading. Any previous error of refraction will, of course, modify this correcting lens. Glasses are not prescribed until all signs of irritation have disappeared—about a month; changes in refraction may continue for several months. *The aphakial eye* presents, besides hyperopia and loss of accommodation, a *deep anterior chamber* and usually a *tremulous iris;* the images normally seen on the anterior and posterior surfaces of the lens are absent.

Prognosis.—A *favorable result* and *useful vision* follow cataract extraction in almost all uncomplicated cases (98 per cent.); there is generally good vision and not infrequently this is perfect. The prognosis depends not only upon *skilful operation*, but upon *exclusion* of those complicated cases which cannot be improved by an operation, no matter how successful, and also those in which there is a neighboring source of *infection.* Hence conjunctiva, lid margins, and lacrymal sac must be carefully inspected, and if disease is found, this must be cured before operation. Cautious operators examine the conjunctival discharge bacteriologically in every case. We must exclude disease of the deeper structures of the eye and especially of the *retina.* The condition of the optic nerve and retina is tested with the candle or lighted electric bulb for *light perception* and *light projection.* There should be good perception of light, even with feeble illumination, and also a good field and projection.

Projection is tested by reflecting light from the mirror of the ophthalmoscope upon the upper, lower, inner, and outer portions of the pupil; there is good projection, if, without moving the eye, the patient is able to state correctly the direction from which the light comes; this test may also be applied with the *lighted candle* or electric bulb made to approach the eye from various directions, at a distance of one meter and also at four meters. Although the cataract

be fully matured, the patient should be able to tell the position of the candle in various parts of the field, with the eye fixed directly in front of him.

CATARACT EXTRACTION

The operation of extraction is indicated for the removal of all *senile cataracts* which are considered fit for operation; soft cataracts after the age of fifteen (sometimes before this period); soft cataracts which have been needled, or traumatic cataracts when glaucoma intervenes or to expedite cure; and sometimes complicated cataracts.

The following description applies to the method of performing *combined extraction* (with iridectomy):

Instruments Required:—(1) An eye speculum (Fig. 214); (2) a lid elevator (Fig. 10); (3) a fixation forceps (Fig. 215); (4) a narrow Graefe knife (Fig. 216); (5) a capsule forceps (Fig. 220A); (6) a cystotome (Fig. 217); (7) a lens spoon (Fig. 218); (8) an iris repositor (Fig. 220); (9) a wire loop (Fig. 219); (10) curved iris forceps (Fig. 195); and (11) curved iris scissors (Fig. 196).

Operation.—*The Corneal Section.* After thorough *cleansing* of the surrounding area including the lashes and painting lid margins and lashes with 3-per-cent. iodine, the conjunctival sac is *flushed* with a large quantity of warm saline or boric solution. Local anæsthesia by *cocaine* or *holocain* is ordinarily used, rarely a general anæsthetic; subconjunctival injection of a few drops of 4-per-cent. cocaine, below and above, at some distance from the limbus, will render the operation absolutely *painless*. A drop of adrenalin solution is instilled. Sometimes a few drops of 2-per-cent. novocaine are injected into the palpebro-temporal region to prevent the patient from squeezing. The operator stands behind the patient, inserts the eye speculum, applies the fixation forceps just below the cornea, and, the patient looking down, makes the corneal section. The latter comprises about *two-fifths* of the circumference of the cornea and is in the plane of its transparent margin. The Graefe knife is thrust into the corneal margin above the horizontal meridian, traverses the

anterior chamber, and emerges at a point opposite the puncture (Figs. 221 and 223). Pushing the knife forward and cutting upward by a to-and-fro movement, the section is completed in the same plane, terminating at the upper

FIG. 216.—Graefe Knife.

FIG. 217.—Cystotome.

FIG. 218.—Lens Spoon.

FIG. 219.—Wire Loop.

FIG. 220.—Iris Repositor.

FIG. 214.—Eye Speculum.



FIG. 215.—Fixation Forceps.

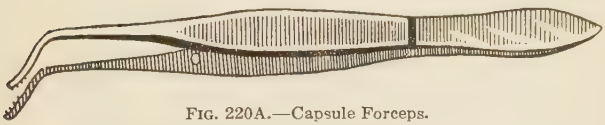

FIG. 220A.—Capsule Forceps.

FIGS. 214-220.—Instruments Required for Cataract Extraction. (Those used in Iridectomy are Illustrated on Page 210).

margin of the cornea, where a small conjunctival flap is usually made (Fig. 224). If the operator is not ambidextrous he must stand at the patient's side and in front when operating on the left eye, so as to hold the knife in the right hand. Throughout the operation, the speculum should be steadied and held away from the eyeball, so that no injury results should the patient squeeze the lids together. Some operators

prefer to use a lid-elevator, held by an assistant, in place of the speculum.

2. *Iridectomy.* The fixation-forceps may now be left on or removed, the conjunctival flap is reflected upon the

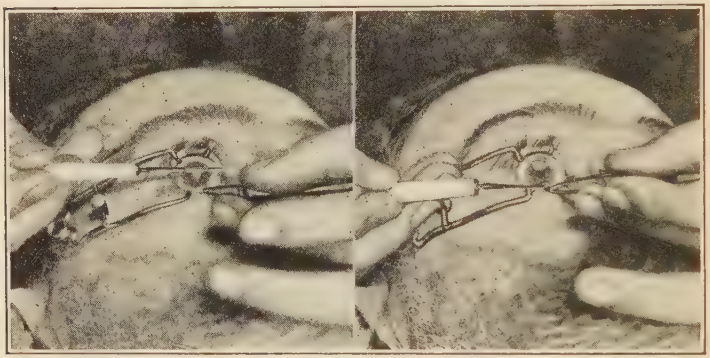

FIG. 221.—Corneal Section in Cataract Extraction.

FIG. 222.—Delivery of the Lens in Cataract Extraction.

cornea, and iridectomy performed, making as narrow a coloboma as possible (p. 212).

3. *Opening the Capsule* (*Capsulotomy*). The capsule-forceps is introduced and applied to the center of the capsule closed, then opened, and as large a piece of the membrane removed as possible. Many operators prefer division of the capsule to its removal with the forceps; this is accomplished with the cystotome which is introduced flatwise, its point turned, and the capsule cut gently and without pressure; there are many different methods of opening the capsule: the incision may be T-shaped, A-shaped, +-shaped, or peripheral and concentric with the corneal margin.

4. *Delivery of the Cataract.* Fixation forceps are removed and the lens is expelled by pressing gently upon the lower part of the cornea toward the centre of the globe, with the back of a Daviel spoon; through the gaping of the corneal wound, the lens presents (Figs. 222 and 225), passes out and is received upon the wire loop. If the corneal wound

seems too small for easy exit of the lens, it is enlarged with Steven's scissors.

5. *Cleansing ("Toilet") of the Wound.*—A few drops



FIG. 223.—Cataract Extraction; Corneal Section.

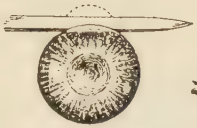

FIG. 224.—Cataract Extraction; Conjunctival Flap.



FIG. 225.—Cataract Extraction; Delivery of the Lens.

of antiseptic solution are instilled, the lids closed for a few minutes, after which the eye is inspected. Any lens debris or blood clots are removed by gently rubbing the edge of the lower lid upward over the cornea and by stroking with the spatula; the lips of the wound must also be freed from lens particles. If remnants of cortex persist, the anterior chamber is irrigated with a rubber bulb provided with a delicate glass tip, using warm sterilized saline solution (0.4 per cent.). The iris is smoothed out with repositor and freed from any entanglement in the wound. The conjunctival flap is next adjusted, the eye washed out with antiseptic solution, a drop of 1-per-cent. atropine solution instilled, and a small quantity of 1:3000 bichloride ointment placed between the lids.

6. *Dressing.*—The dressing varies. Most operators cover the lids of both eyes with a round piece of gauze soaked in antiseptic solution, over this dry absorbent cotton, then a round piece of lint; the dressing is fastened with strips of adhesive plaster passing from below the orbit to above the brow and confined by a binocular bandage. (Fig. 374). Protective covers (aluminum, wire, stiff cloth, Fig. 226) are used to prevent injury to the operated eye.

After-treatment.—The patient must lie quietly upon his back; an anodyne is often advisable; after 24 hours he may change to the unoperated side. His food should be fluid

for the first few days. The bowels need not be emptied for four days; if a movement occurs before this, there must be no straining. The wound is inspected after 24 hours (some operators prefer to wait 48 hours). Atropine is instilled at each dressing. After three or four days the unoperated eye may be left free, and the patient may sit up in bed for an hour or two; after a week a light dressing (Fig. 372) is applied and the patient may sit in an easy-chair; after 10 days smoked glasses need be the only protection.

Fig. 226.—Ring's Ocular Mask.

Simple Extraction is performed like combined extraction except that iridectomy is omitted (p. 234).

Linear Extraction.—In this modification, suitable for *soft* and traumatic cataracts and cataract masses produced by needling, *a small corneal section* (about 5 mm.) is made 1 mm. within the margin of the cornea with the keratome, the pupil having been dilated; the capsule is freely torn with the cystotome or opened with the keratome directly after it penetrates the cornea; then the lens masses are evacuated by depressing the posterior lip of the wound with the wire loop and pressing upon the cornea. A small iridectomy is sometimes made.

Extraction of Cataract in its Capsule is the method used in India, notably by Smith, but by few oculists elsewhere. The steps of this operation are similar to those of combined extraction with omission of capsulotomy; the lens is dislocated and then expressed within its capsule by strong pressure upon the cornea with a squint hook. Though after-cataract is avoided, escape of vitreous occurs often; hence this operation is more hazardous than when capsulotomy is resorted to. A modification of this method (A.

Knapp) consists of rupture of the lower portion of the suspensory ligament and subluxation of the lens by means of traction upon its capsule with the Kalt capsule forceps, after the usual corneal section and iridectomy; backward pressure is then applied to the lower part of the cornea until the lens turns over and presents in the corneal wound. Recently, the intracapsular extraction of senile cataract by *suction* has been advocated by Barraquer, who applies the cup-shaped tip of a special apparatus to the capsule, dislocates the lens, and withdraws it through a corneal section. Occasionally soft cataracts are removed by suction.

The Complications of Cataract Extraction include loss of vitreous, dislocation of the lens, insufficient opening in the cornea or capsule, wounding the iris, prolapse of the iris, incomplete evacuation of the cataract, and intraocular hemorrhage.

The Complications in the Healing-Process include prolapse of the iris, striated keratitis, glaucoma, iritis, iridocyclitis, cyclitis, suppuration of the wound, panophthalmitis, and intraocular hemorrhage.

Congenital Complete and Juvenile Complete Cataracts are rather infrequent. The lens is uniformly *white*, bluish-white or pearly, and always *soft*, sometimes fluid and milky. These cataracts may occur in otherwise perfectly healthy eyes, or they may be complicated cataracts, with changes in the retina, choroid, or optic nerve. One or both eyes are affected. The *congenital* complete cataract is due to a disturbance of development or intrauterine ocular inflammation. The complete cataract of young people (*juvenile*) may be hereditary, or arise without known cause; in some cases there is a history of convulsions.

Treatment consists in *discission* (needling) soon after the second year, so that disuse of sight may not cause amblyopia. The needle operation must usually be repeated a number of times; sometimes there are remains of the lens which do not become absorbed and must subsequently be removed by linear extraction. Semifluid cataracts are removed by linear extraction.

Anterior Polar Cataract (*Pyramidal Cataract*).—This partial and stationary lenticular opacity occurs in the form of a *small*, round, white opacity, often pyramidal in shape, situated at the *anterior pole* of the lens, beneath the capsule (Fig. 227). It may be *congenital* or *acquired*. The acquired form

FIG. 227.—Anterior Polar Cataract. *A*, Seen with Oblique Illumination; *B*, Section of Lens; *C*, Seen with the Ophthalmoscope.

FIG. 228.—Acquired Form of Posterior Polar Cataract. *A*, Seen with Oblique Illumination; *B*, Section of the Lens; *C*, Seen with the Ophthalmoscope.

originates from an *ulcer of the cornea* in early childhood; such an ulcer perforates and allows contact and pressure between lens and cornea, setting up an irritation in the anterior capsule which results in a proliferation of the subcapsular epithelium; afterward the anterior chamber is restored; sometimes there is an accompanying corneal opacity. As a rule this form of cataract causes little if any reduction in vision.

Posterior Polar Cataract.—This form may be *congenital* (*capsular*) or *acquired* (*cortical*).

The *congenital* form is a capsular opacity consisting of a *small*, round, white deposit, situated at the posterior pole; with the ophthalmoscope it appears as a black dot upon the red fundus-reflex. It represents the remains of the *hyaloid artery* at the point of attachment to the posterior capsule of the lens. It causes but trifling interference with vision and requires no treatment.

The *acquired* form is a grayish, stellate opacity of *larger* size, situated in the *cortical* layer of the lens, at its posterior pole (Fig. 228). It is a form of *secondary* cataract which develops in connection with high myopia, choroiditis, and retinitis pigmentosa. It remains *stationary* for many years, but is apt finally to become *complete*. In this affection there is considerable *impairment of vision*, caused not only by the cataract, but also by the accompanying disease of the deep structures. Sometimes a similar condition is found near the

anterior pole of the lens. Such secondary cataracts do not admit of operation on account of the accompanying ocular disease. Occasionally a posterior polar (cortical) opacity exists without evident affection in other parts of the eye.

Lamellar or Zonular Cataract.—This variety of *partial*, stationary cataract is either *congenital* or forms in *infancy*, and usually affects *both eyes*. It is the most common form of cataract seen in children. It is sometimes hereditary, and often associated with a history of convulsions and with the changes of rickets, especially in the teeth, cranial and other bones. It consists of a gray, disc-like opacity of the *layer surrounding the transparent nucleus*, with clear cortex on the outside (Fig. 229). When the pupil is dilated, examination by oblique illumination shows a *grayish disc surrounded by clear lens substance;* from the margin of the opacity short striæ are often seen projecting into the surrounding transparent cortex. The cataract is most dense at the margin of the disc; this distinguishes it from nuclear cataract. With the ophthalmoscope at a distance, we see a dark disc surrounded by a zone of red fundus-reflex; the disc is somewhat lighter in the centre than at the periphery.

A *B* *C*

FIG. 229.—Zonular Cataract. *A*, Seen with Oblique Illumination; *B*, Section of the Lens; *C*, Seen with the Ophthalmoscope.

Lamellar cataract usually remains *stationary*, but occasionally becomes complete. It causes *interference with vision;* the amount may be slight or decided, depending upon the density of the opacity.

Treatment.—When sight is considerably interfered with we can improve vision by *iridectomy*, by *discission* in the young, or by *extraction* in older persons. *Iridectomy* (small coloboma downward and inward) is indicated when the vision is very materially improved after the use of a mydriatic; its advantages are that the patient does not require strong convex lenses and often retains binocular vision; its disadvantages are the elongated pupil, and some dazzling due to this. Removal of the lens by *discission* or *extraction* is indicated in

those cases in which there is little or no improvement in sight after dilatation of the pupil, and when there are indications of progress of the cataract.

Various Uncommon Varieties of Stationary, Partial Cataract are met with. These include (1) *central* cataract, a small, white opacity in the centre of the lens, (2) *fusiform* cataract, a spindle-shaped opacity running from the anterior to the posterior pole, and (3) *punctate* cataract, consisting of a number of very small, white dots variously distributed through the lens. These opacities are usually *congenital*, cause *little interference with vision*, but are often associated with other ocular defects.

Complicated or Secondary Cataracts accompany or follow *other diseases of the eye*. The most frequent ocular affections which lead to cataract are iridocyclitis, choroiditis, high myopia, severe forms of corneal ulcers, glaucoma, retinitis pigmentosa, and detachment of the retina. Such cataracts frequently begin in the *posterior* part of the lens, often have distinctive features, and tend to *degenerate*. It is important to establish the fact that a cataract is complicated when the question of operation presents itself. The *treatment* of complicated cataracts is usually very *unsatisfactory* and the prognosis is always much less favorable than in uncomplicated cases. This is because the operation is rendered difficult and the effect on sight disappointing by the complicating ocular disease; many cases cannot be operated upon.

Traumatic Cataract is the result of a perforating *wound of the lens capsule*, occasionally of contusions of the eyeball without visible perforation (*concussion cataract*), rarely from lightning-stroke or electric shock. Soon the injured portion of the lens becomes *cloudy* from absorption of aqueous, *swells*, protrudes through the capsule wound and often falls into the anterior chamber; swelling and clouding continue until the entire lens has become opaque. Then the lens substance becomes *absorbed;* in favorable cases in young persons spontaneous cure with a clear, black pupil results. More frequently, however, part of the lens remains opaque in the capsule and requires subsequent operation. Occasionally the

opacity of the lens remains limited to the injured portion, and in rare cases such a stationary cataract becomes absorbed. The course described may be less favorable: iritis, iridocyclitis, or secondary *glaucoma* from swelling of the lens may occur. Contusions of the eye may be followed not only by concussion cataract, but by a brownish ring-shaped opacity (Vossius' ring) on the anterior capsule, corresponding to the margin of the iris and supposed to represent adhesion of iris pigment.

Treatment.—Immediately after the injury, absolute *rest* and *atropine* are to be employed. If the rapid swelling of the lens causes inflammation and much increase of *tension*, the cataract should be removed by extraction. But if such complications do not arise, it is wiser to allow absorption to proceed, and to defer operative intervention until there is no irritation or inflammation, and spontaneous improvement has come to a standstill.

After-Cataract (often called *Secondary Cataract*) is an opacity of the lens capsule seen in many instances *after cataract operation;* it consists of remnants of lens cortex, of proliferation of remaining subcapsular epithelium, or of products of inflammation (new connective tissue). The *membrane* thus formed may be thin and delicate or thick and tough, and the degree of subsequent diminution in the improvement in sight following the cataract operation will vary accordingly. When due to inflammatory products, the membrane is apt to be thick and the iris adherent.

Treatment consists in *dividing* the membrane (*discission*), after all signs of irritation or inflammation have subsided, usually two or three months subsequent to the cataract extraction.

DISCISSION OR NEEDLING

This operation is indicated in zonular, congenital complete, and juvenile complete cataracts (*soft cataracts*), previous to the fifteenth year, as a preliminary step in extraction in cases of high degree of *myopia* and for the division of *after-cataract.* The operation differs according to whether the lens is present or whether we are dealing with an after-cataract.

Discission when the lens is present.—In very young children a general anæsthetic is required; in others, local anæsthesia is sufficient. The *pupil* must be *dilated.* The speculum is introduced and the eyeball steadied with the fixation forceps. A knife-needle (Fig. 230) is thrust through the outer margin of the cornea and then through the capsule of the lens, making two cross cuts, each about 4 mm. in length (Fig. 231). These cuts must be superficial, especially if this is the first operation, so that there will not be too rapid swelling of the lens. The lens substance may be broken up a little by rotating the needle. After some of the swollen lens matter has been absorbed (several weeks), the operation must be repeated; at the second operation the discission may be deeper and bolder. At the last of the several operations, the incision must include the posterior capsule.

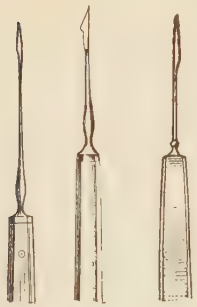

Fig. 230.—Knife-needles.

After-treatment.—There is usually very little reaction. The pupil must be kept dilated with atropine. The lens substance swells, protrudes through the opening in the capsule, and pieces fall into the anterior chamber and become absorbed. Usually three operations are required. The entire duration of treatment is several months.

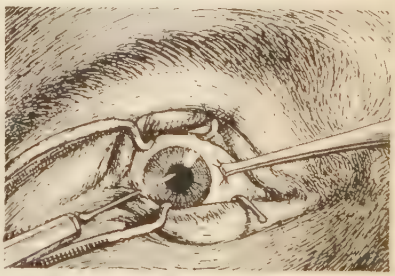

Fig. 231.—Discission of the Lens.

Complications.—Rapid and extensive swelling of the lens may cause *secondary glaucoma* requiring removal of the lens by linear extraction, with or without iridectomy. A bold discission is sometimes done, with a view of extracting the lens a few days afterward, as soon as there is marked swelling; this is the usual procedure when the lens is removed in high de-

grees of myopia. *Iritis* may occur after discission, occasionally iridocyclitis, and very rarely loss of the eye.

The Suction Method is occasionally used after discission of soft cataracts, and in fluid or semifluid cataracts: A small corneal wound is made and the capsule lacerated; by means of a tube the lens matter is sucked out, either by mouth or suction-syringe. This method is not in general use.

Discission for After-Cataract.—If the opacity is *thin and delicate* it is divided by means of a *knife-needle* (Fig. 230) introduced through the conjunctiva 1 mm. external to the limbus, the pupil having previously been dilated; a T-shaped or +-shaped incision is made, care being taken that the instrument is sharp, and that there is no dragging on the iris or ciliary body, for fear of subsequent inflammation. Such membranes are occasionally cut by introducing the knife-needle from behind, through the sclera. If the membrane is *thick and tough,* it may be divided by *two knife-needles,* one entering at each side of the periphery of the cornea, meeting in the centre of the pupil and then separating. When the iris is adherent it will be necessary to perform iridotomy or a similar operation (p. 174). Discission of after-cataract is sometimes followed by glaucoma, and occasionally by iridocyclitis and suppuration.

DISLOCATION OF THE LENS

Dislocation of the lens may be *partial* or *complete.*

Symptoms are disturbance of *vision,* interference with *accommodation,* a change in *refraction,* monocular *diplopia,* and *tremulous iris.* They differ according to whether the displacement is partial or complete. In addition there may be complications and sequelæ.

Partial Dislocation (*Subluxation*) may consist of a *tilting* of one edge of the lens, or of a *lateral* displacement—upward, downward, inward, or outward. In such cases the *anterior chamber* will be of unequal depth, being *increased* where the lens is absent. The *convex edge* of the lens can usually be seen (Fig. 232) in some part of the pupil, the portion of the latter which is free from lens being particularly black. With the

indirect method of ophthalmoscopy, the optic *disc appears double*, one image being seen through the lens and the other through the free pupil. Movements of the eyeball disclose a tremulous condition of the lens and iris (*iridodonesis*). There is considerable *myopia* in the area corresponding to the lens, the convexity of the latter being increased through relaxation of the suspensory ligament; also marked astigmatism. *Monocular diplopia* is complained of, two images being formed on the retina. The subluxated lens may become opaque, and this adds to the visual disturbance.

FIG. 232.—Dislocation of the Lens Upward and Outward.

Complete Dislocation (*Luxation*) occurs when the lens is displaced *anteriorly* into the aqueous, or *posteriorly* into the vitreous cavity. In traumatic cases in which there is rupture of the sclera, the lens may lie *beneath the conjunctiva*.

When dislocated *anteriorly*, the lens is easily recognized. If transparent, it looks like a large drop of oil with a curved, golden margin when seen by oblique illumination. The anterior chamber is increased in depth.

When displaced into the *vitreous*, the lens sinks into the lowest part, and either becomes attached to the fundus by exudation or moves about; when opaque, it can be seen with the ophthalmoscope and sometimes with the unaided eye. The anterior chamber is deep, the iris tremulous, and the pupil very black. The eye is, as in aphakia, in a condition of extreme hyperopia and has lost its power of accommodation.

Complications and Sequelae.—A partial dislocation often changes to a complete one. When subluxated, the lens may remain clear a long time, but completely dislocated lenses soon become *opaque*. Choroiditis and iridocyclitis, secondary glaucoma, and even sympathetic ophthalmia sometimes follow. Displacement into the vitreous is tolerated better than anterior luxation.

Etiology.—Dislocation of the lens may be either *congenital* or *acquired.* In order that the lens can become dislocated there must be some *defect in the suspensory ligament* such as rupture, stretching, or imperfect development.

The *congenital form* is partial, usually upward, often becomes complete in after-years, is generally bilateral and symmetrical, and sometimes hereditary.

The *acquired forms* are either *traumatic* or *spontaneous.* Traumatic dislocation is generally the result of contusions. The predisposing cause of spontaneous dislocations is degeneration of the suspensory ligament seen in fluid vitreous, choroiditis, and myopia of high degree, detachment of the retina, and hypermature cataract; the exciting cause may be insignificant, such as various straining efforts.

Treatment.—In *partial* dislocation, if no symptoms of irritation are produced, treatment consists in prescribing suitable glasses, usually *strong convex lenses,* to correct the refraction of the aphakial portion. When the lens is dislocated into the *anterior chamber* it should be *removed* through a corneal incision, after having pierced the lens with a needle to prevent its dislocation into the vitreous. If dislocated into the *vitreous,* extraction is indicated but difficult; if symptoms of irritation arise, the lens may be removed with the wire loop through a corneal incision; strong convex glasses are prescribed for the aphakia. If inflammatory symptoms occur in a case in which the dislocated lens cannot be removed, an iridectomy may be tried; if, in such cases, the eye is sightless, enucleation is indicated.

CHAPTER XVIII

DISEASES OF THE RETINA

Anatomy.—The retina is a thin, delicate membrane which consists, among other parts, of an *expansion of the optic nerve.* It is placed between the hyaloid membrane of the vitreous internally, and the choroid externally. It extends forward to the ciliary body where its termination is called the *ora serrata;* devoid of nerve fibres, simpler and thinner, it is continued over the inner surface of the ciliary body and the posterior surface of the iris. In the living eye, it is *transparent* and of a *purple red color;* under the influence of light, it is quickly *bleached;* after death, it soon becomes opaque and white. The retina is connected with the subjacent choroid at the entrance of the optic nerve and at the ora serrata; elsewhere it simply lies upon this tunic but is not attached to it. When we detach the retina, the pigment cells which form its outermost layer adhere to the choroid, and on this account were formerly described as part of the latter.

The *inner surface* of the retina presents in the axis of the eyeball the yellow spot or *macula lutea,* about 1 to 2 mm. in diameter, and in its centre a small depression, the *fovea centralis;* this is the region of most distinct vision, and the part of the retina which is made to receive the image when we wish to get an exact impression of an object. About 3 mm. to the inner side of the posterior pole of the eye is a pale, round area, the *head of the optic nerve* (*papilla* or *disc*), corresponding to the point where the optic nerve pierces the retina (Fig. 43). The circumference of the disc is slightly elevated above the surface of the retina, but the centre presents a depression, the *physiological cup* or *excavation;* here the blood-vessels of the retina enter the eye. The ophthalmoscopic appearances of the background of the eye and the distribution of the retinal vessels are given in Chapter III.

The central artery of the retina, accompanied by the corresponding vein, pierces the optic nerve about 2 cm. from the globe, and passes between the bundles of fibres to the inner surface of the retina at or near the middle of the disc. Excepting at the papilla, where minute communications are sometimes found between retinal and ciliary vessels, the retinal arteries have no anastomoses; they are *terminal* branches; hence in obstruction of the central artery there is no compensatory collateral circulation, and blindness results. The retinal vessels lie in the inner layers; the external layers are destitute of blood-vessels and are nourished by the adjacent choriocapillaris. The fovea has no blood-vessels; in this situation, the choriocapillaris is thickened. The blood-vessels are surrounded by sheaths forming the *lymphatics* of the retina.

The *minute anatomy* of the retina is very complicated. We distinguish two kinds of tissue: (1) *nervous elements*, of which there are eight layers, and (2) *supporting tissue* (Mueller's fibres). The supporting tissue comprises the internal and external limiting membranes and numerous fibres serving to keep the delicate nerve tissue in proper position and to insulate the nervous elements.

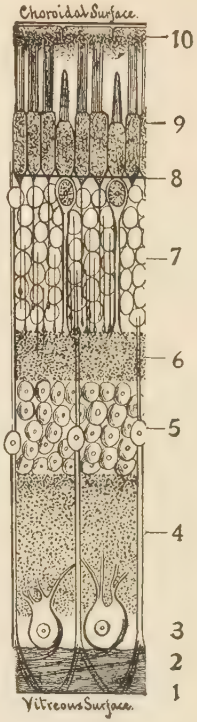

FIG. 233. — Vertical Section of the Retina (Modified from Schultze). The Numbers refer to the Text.

Microscopic examination shows the following layers of the retina, from within outward (Fig. 233): 1. The *internal limiting* membrane. 2. The layer of *nerve fibres*, consisting of the expansion of the fibres of the optic nerve destitute of medullary layer after piercing the eyeball. 3. The layer of *ganglion cells*, a stratum of large, branching nerve cells. 4. The *inner plexiform* layer. 5. The *inner nuclear* layer. 6. The *outer plexiform* layer. 7. The *outer nuclear* layer. 8. The *external limiting* membrane. 9. The layer of *rods and cones*, the light-perceiving layer. 10. The layer of *pigment cells* which bounds the retina externally and consists of a single stratum of hexagonal pigmented cells.

The *rods* are much more numerous than the *cones*, excepting at the macula where the cones preponderate. *At the fovea* there are no rods, and the cones, longer and narrower than elsewhere, are found exclusively. In this spot also, all the layers of the retina are much *thinner*, there is no nerve-fibre layer, and Mueller's fibres are arranged obliquely. The *disc* consists of optic-nerve fibres exclusively; it has no other retinal nerve elements and has no power of sight; hence it is called the blind spot.

Physiology.—*The action of light changes the visual purple* contained in the outer segments of the rods into a colorless substance. When the eye is in the dark, most of the pigment is stored in the posterior portion of the cells of the pigment epithelium and is withdrawn from between the rods. After exposure to light, the pigment granules push their way inward into the processes extending between the rods and cones, and the latter become contracted and shortened. The function of the pigment cells is the renewal of the visual purple of the outer segments of the rods after the bleaching produced by exposure to light.

The *rods and cones*, the terminal organs of the optic nerve, receive waves of light which fall upon the retina and convert these vibrations

into nervous impulses which are carried by the optic nerves (the fibres of which represent the axis cylinders of the ganglion cells) and the optic tracts to the *brain;* here they produce the *sensation of light.* When the image of an object falls upon the macula, there is distinct vision; when it falls upon any other part of the retina, there is indistinct vision. Two points give rise to *separate visual impressions* when their images are at least 0.002 mm. apart, since this represents the diameter of the cones at the fovea; images which are closer than this would only stimulate one cone and consequently create but one visual impression. In other words, to be seen distinctly, two objects must subtend a visual angle of one minute or more.

Images of an object give rise to a *single* visual impression when they fall upon *corresponding retinal areas;* otherwise there are double images. In binocular vision certain portions of the retina are *associated;* thus the upper halves of the retinæ correspond, as do also the lower halves; but the nasal side of one retina corresponds to the temporal half of the other, and *vice versa.*

Rays of light impinging upon the retina come from the *opposite side of the field;* thus the upper part of the retina is used for seeing objects in the lower part of the field, the temporal portion of the retina for the nasal part of the field, etc. The *image* on the retina is always *inverted.*

Affections of the Retina may be divided into:

a. *Inflammation,* the various forms of *retinitis:* (1) simple, (2) deep, (3) albuminuric, (4) diabetic, (5) leukæmic, (6) syphilitic, (7) hemorrhagic, (8) septic, (9) uncommon forms of retinal changes.

b. *Circulatory Disturbances:* (1) hyperæmia, (2) anæmia, (3) hemorrhages, (4) arteriosclerosis, (5) embolism, (6) thrombosis.

c. *Pigmentary Degeneration.*

d. *Detachment.*

e. *Tumor:* glioma (see chapter on Intraocular Tumors).

RETINITIS

Inflammation of the retina presents *various clinical types.* There are, however, certain signs and symptoms which are more or less common to all varieties. Retinitis may be *primary,* or *secondary,* when it is an extension of inflammation of neighboring ocular structures. It usually *extends* to both the papilla and the choroid. When the involvement of the en-

trance of the optic nerve is marked, we speak of the affection as *neuroretinitis;* when the choroid is prominently implicated, we call the condition *choroidoretinitis.* The disease may be confined to one eye; but since it is generally dependent upon a constitutional factor, it is almost always *bilateral.* It may be acute in course, but as a rule it lasts many *weeks* or even several months.

Objective Symptoms.—There are no external signs; the objective symptoms are all ophthalmoscopic: Diffuse *clouding* of retinal details, especially in the region of the papilla; *congestion* of the disc with *indistinctness* of its edges; circumscribed *exudations* appearing as soft, white, or slightly yellow spots or patches, discrete or confluent, varying in size, and found principally along the retinal vessels and at the macula; *tortuosity and distention of the vessels,* seen principally in the veins which are darker than normal; the vessels may be obscured in parts by swelling and exudation; *hemorrhages* of various shapes and sizes, rounded when occurring in the deeper layers, and feathery or flame-shaped when superficial; opacities of the vitreous.

Subjective Symptoms.—Diminution in acuteness of *vision* varying with the severity and extent of the retinitis and the situation of the exudates, but generally considerable; changes in the *field* of vision: there may be concentric or irregular contraction, or scotomata; *alterations* in the *shape* of objects: micropsia, objects appearing smaller than they really are; macropsia, objects appearing larger than normal; metamorphopsia, a distortion of the shape of objects, straight lines appearing wavy and bulging; diminution of the light sense; feeling of *discomfort* in the eyes; photophobia may be present, but pain is rare.

Course.—The inflammation may *subside* completely and useful vision return; or certain *changes* may occur in the retina as a result of atrophy, causing considerable impairment or absolute loss of vision. These changes are: *Atrophy* of the retina allowing the choroidal vessels to become visible; bright, white *patches* and *dots* replacing hemorrhages or exudation and frequently *pigmented;* contraction of the vessels,

which are bordered by *white lines;* atrophy of the disc, which presents an indistinct outline and a pale, dirty color (*retinitic atrophy*). The *prognosis* depends upon the severity of the inflammation, the parts of the retina most involved (unfavorable when the macula has suffered), and the clinical form of the retinitis.

Pathology.—The changes consist of congestion, œdema, exudation of leucocytes and fibrin, changes in the vessel walls, fatty degeneration, pigmentation, and extravasation of blood. The white spots are due to exudation of leucocytes and fibrin, swelling of nerve fibres and cells, and fatty degeneration of the retinal elements and of exudation. The walls of the blood-vessels become thickened and the calibre is sometimes obliterated. Later, the retina becomes atrophied and then consists largely of connective tissue presenting considerable pigment, the nerve elements disappear, and the blood-vessels present thickened walls, sometimes replaced by solid cords.

Etiology.—Retinitis occurs occasionally as a local lesion. But generally it is merely a manifestation of a *constitutional disease,* such as nephritis, diabetes, syphilis, etc., a list of which is given on p. 252; or it may be due to abnormal conditions of the blood and blood-vessels, metastasis, and autointoxication; or it may be an extension from an iritis, cyclitis, or choroiditis.

Treatment.—The *local* treatment consists in absolute *rest* for the eyes, *protection from light* by smoked glasses, and often the use of *atropine.* Internally, we prescribe small doses of *mercury* combined with *iodide* of potassium. *Diaphoresis* is useful, and sometimes cathartics. In addition, it is of the greatest importance to treat the *constitutional* condition which is the cause of the retinal lesion.

Types. Retinitis was formerly described under the terms *serous* and *parenchymatous,* referring to a pathological division. Though this classification is no longer used, a description of the two types (even at the expense of repetition) will be a useful preface to the study of the special forms next to be considered, explaining the variations in the intensity of the process and the corresponding differences in visual damage.

The Simple or Serous Type (also known as Œdema of the Retina) involves only the *superficial* layers and is *slight* in degree, the evidences of inflammation being limited to swelling, vascular distention, and occasionally hemorrhages. Some authorities regard it, not as a distinct disease, but as the first stage of the more common forms of retinitis.

There is limited impairment of vision (often merely a blurred sensation), some distortion of images, and moderate peripheral contraction of the field. The ophthalmoscope reveals a hazy fundus especially around the disc, the margins of which are indistinct, veins somewhat dilated, tortuous, and hidden in places by the œdema, and at times hemorrhages.

This form of retinitis may be due to excessive use of the eyes, especially with uncorrected errors of refraction and by poor illumination, the effect of intense light and heat, exposure to cold, or there may be no assignable cause. It may be merely the first stage of other forms of retinitis.

The prognosis is *good* when the affection remains of this type and does not change to the deep form. Treatment consists in the removal of the cause and the observance of the directions given above.

The Deep or Parenchymatous Type is a more *intense* inflammation involving the *deeper* layers of the retina; the pathological changes are more extensive, including, besides those occurring in the serous form, exudation, changes in the vessel walls, and hemorrhages, and consequently capable of causing greater destruction with atrophy and permanent visual damage.

There are often marked ocular discomfort, much disturbance of vision and distortion of objects, peripheral contraction of the field, and scotomata. The ophthalmoscope discloses, in addition to the picture presented by the serous type, scattered yellowish patches of exudate, especially in the macular region, changes in the walls of the blood-vessels, and hemorrhages.

This variety depends upon constitutional causes or represents an extension of or association with neighboring ocular diseases. The prognosis is always *serious;* though some cases recover with fair or even good vision, many are left with marked impairment of this function. Treatment has been

given under retinitis in general, and is discussed again in the clinical forms of retinitis in the following pages.

ALBUMINURIC RETINITIS

Retinitis of Bright's Disease (*Renal Retinitis*) presents ophthalmoscopic signs which are often pathognomonic. It is usually *bilateral*, rarely unilateral.

Symptoms.—The subjective symptoms are those of retinitis in general (p. 253). The degree of *disturbance of vision* depends upon the severity of the inflammation and especially upon the position of the exudations and hemorrhages. Minute changes in the macular region will cause considerable reduction in acuteness of vision, while extensive involvement of the rest of the fundus may affect the sight comparatively little.

Ophthalmoscopic Signs (Plate XVI) are those of retinitis in general: *swelling and haziness* of the retina and of the papilla, distention and *tortuosity* of the retinal vessels, especially veins, and *hemorrhages* either in the form of flame-shaped or round spots, or larger extravasations. To these are added the distinctive feature: *white spots* found chiefly at the macula and surrounding the disc, less frequently elsewhere. *At the macula*, there may be at first merely a few dots, but later there are more pronounced spots and these are usually arranged in radiating lines which form a *star-shaped figure* with the fovea for a centre; or when less complete, the sticks of an open fan; they are *brilliant*, due to fatty degeneration of retinal elements and of exudation. *Near the disc*, often more or less surrounding it, are *larger* white spots; these may coalesce and form a ring around the disc. Occasionally retinal detachment occurs.

Though this is the most frequent picture of albuminuric retinitis, there are *other and less characteristic signs* in nephritis; there may be simply retinal hemorrhages, simple retinitis, hemorrhagic retinitis, neuritis, or even a picture of choked disc such as we are in the habit of associating with cerebral tumor. On the other hand a brain tumor may present ophthalmoscopic appearances identical with those of a typical case of albuminuric retinitis.

PLATE XVI

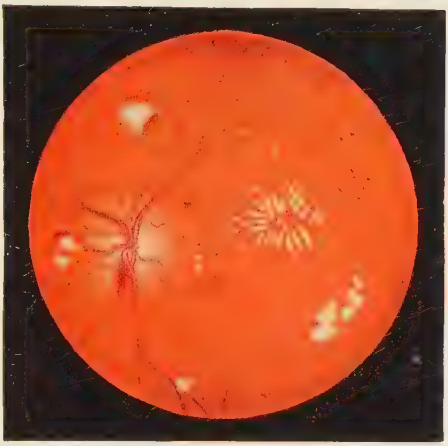

FIG. 234.—Albuminuric Retinitis.



FIG. 235.—Albuminuric Retinitis with More Pronounced Changes.

Albuminuric retinitis occurs under *two forms:* 1, the *inflammatory,* when swelling, congestion, and hemorrhages are the predominating features; and 2, the *degenerative,* when the white spots and hemorrhages occur without swelling or congestion. The two forms are usually associated in varying proportions.

Etiology.—The affection is usually a complication of *chronic interstitial nephritis;* much less frequently of chronic parenchymatous nephritis; it may occur with any form of nephritis, including that of scarlatina and pregnancy. From one-quarter to one-half of all patients with nephritis present some form of retinal lesion.

Pathology.—The retina presents œdema, *hypertrophy* of its elements, deposits of *fat* and *fibrin,* and *hemorrhages.* The retinal vessels are thickened and the seat of hyaline changes with proliferation of the lining epithelium; these changes are similar to those taking place in the vessels of the kidney. The spots in the macular region are caused by fatty degeneration of exudate and retinal elements; their arrangement in a star-shaped figure depends upon the disposition of Mueller's fibres in this situation.

Course and Prognosis.—Though the retinitis is often a late symptom of Bright's disease, the disturbance of vision may be the first symptom which calls attention to the nephritis; not infrequently the existence of nephritis is first discovered through an ophthalmoscopic examination made in the routine of prescribing glasses. There is no fixed relationship between the course of the nephritis, the amount of albumin, and the degree of retinitis. During the progress of the disease there are often variations in the degree of disturbance of vision, corresponding to the absorption and reappearance of hemorrhages and exudates. The condition is of great *prognostic importance* and indicates, with but few exceptions, a *fatal* termination within *two years;* the exceptions are cases occurring during pregnancy and scarlatina.

Treatment should be directed to the *nephritis;* no local treatment is of any value.

Albuminuric Retinitis in Pregnancy (*Gravidic Retinitis*) complicates the albuminuria of pregnancy. The signs and

symptoms are the same as in the other forms of albuminuric retinitis (the inflammatory being the usual type), but they tend to *clear up after delivery*. It usually occurs during the final months of pregnancy, most frequently in primiparæ, and the *prognosis* in regard to vision is often *good*, especially if labor be induced prematurely. When it occurs in the early months, the prognosis is less favorable, and the condition warrants the induction of abortion in order to save eyesight.

Uræmic Amblyopia is the term used for *loss of sight* during an attack of uræmia, *without any changes in the retina*. It occurs in the course of nephritis, in pregnancy, and during the late stages of scarlatina. Similar attacks may, of course, also occur in patients who have albuminuric retinitis. It appears suddenly, affects both eyes, and is associated with other symptoms of *uræmia:* headache, vomiting, dyspnœa, convulsions, and coma; the pupils are dilated but usually respond to light. After lasting for a day or two, *normal vision returns*, providing the patient recovers. The affection is not retinal but *cerebral*, due to the retention of excretory substances in the blood. Treatment is that of uræmia.

Diabetic Retinitis occurs as a late manifestation of diabetes, is usually bilateral, and is not so common as albuminuric retinitis. The ophthalmoscopic appearances (Plate XVII) are characteristic: small, bright, *white spots* in and around the *macular region*, grouped *irregularly* and not in the form of a stellate figure; sometimes larger spots through coalescence of the smaller ones; numerous punctate and occasionally larger *hemorrhages;* there is no swelling of the optic nerve or retina. Sometimes the picture resembles that of albuminuric retinitis. The prognosis depends upon the systemic condition. The treatment is that of diabetes.

Leukaemic Retinitis presents *swelling* of the retina and disc and numerous *hemorrhages* with greatly *dilated* and tortuous *vessels*, the blood within which is of a very light color; the entire *fundus* is *pale red* with a yellowish tinge. There are white and yellow spots of *exudation*, and some of these may present a pink border; they consist of leucocytes surrounded by red blood cells.

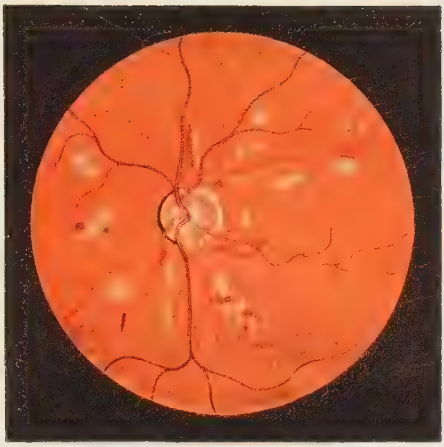

FIG. 236.—Diabetic Retinitis.

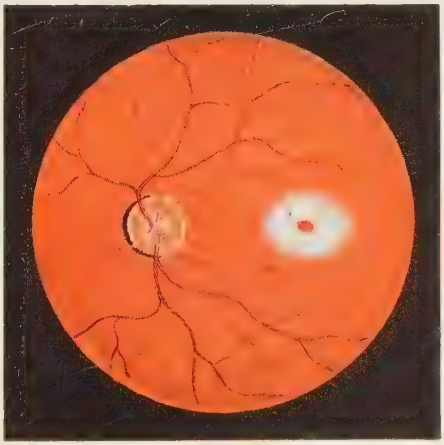

FIG. 237.—The Fundus in Amaurotic Family Idiocy.

SYPHILITIC RETINITIS

This is a *common* form, usually involves both eyes, and occurs with *acquired* as well as with *hereditary* syphilis; in the former, it is found in the secondary stage, during the first or second year; in the latter, the lesions are not infrequently seen after the subsidence of interstitial keratitis. It is generally associated with choroiditis (hence properly called *Syphilitic Choroidoretinitis*), and often with iritis.

Ophthalmoscopic Signs vary according to whether the affection is due to acquired or hereditary syphilis.

In the *acquired* form, there is clouding of the fundus due to *swelling* of the retina and disc, and to fine, *dust-like opacities* of the posterior portion of the *vitreous;* these opacities cause the disc to appear red and hazy; scattered grayish or white *spots* often fringed with *pigment*, especially in the macular region and in the periphery; circumscribed white *exudations* along the large blood-vessels, forming *white lines* (Fig. 176, Plate XIV); later, the deposits of pigment may be so pronounced as to resemble somewhat the picture of retinitis pigmentosa. The changes may be more circumscribed and be represented principally by a large, white exudate, macular or peripheral, changing later to an atrophic area with more or less pigmentation.

In the *hereditary* form we find a leaden or brownish *discoloration* of the fundus upon which are patches of *pigment* of various shapes and reddish-yellow *spots* or gray or white *patches*. All these lesions are most marked in the *periphery*.

Subjective Symptoms consist of more or less diminution in the acuteness of *vision*, diminution in the light sense, *night blindness*, annoying flashes of light, *distortion* and changes in size of objects, central and ring *scotomata*, and later, contraction of the *field* of vision.

Course and Prognosis.—The progress is *slow* and the *prognosis* depends upon the stage during which treatment is begun; if begun early and carried out vigorously, the prognosis is good, though some impairment of vision usually remains. Neglected cases are often followed by atrophy of the retina and optic nerve.

Treatment consists in thorough use of *mercury* by inunction, iodide of potassium, *rest* of the eyes, *protection* from light, and *atropine*. *Salvarsan* is often useful in the beginning of the treatment.

Hemorrhagic Retinitis presents numerous and recurrent *hemorrhages* added to the other signs of *retinitis;* the extravasations of blood, both flame-shaped (superficial) and roundly irregular (deep), may be scattered all over the fundus, or may be most abundant in the macular region or surrounding the disc. This form is sometimes a variety of albuminuric retinitis. It usually occurs in *elderly* individuals as a result of diseases of the *heart* and *blood-vessels* and other circulatory disturbances; it may also be a *local* affection and be due to changes in the retinal arteries and veins including thrombosis. It may be monocular or bilateral. The *prognosis* is *unfavorable*. New hemorrhages are apt to be added to the residua of the old ones; sometimes the affection terminates in glaucoma. It may be a forerunner of cerebral hemorrhage. *Treatment* consists in rest for the eyes, smoked glasses, sometimes local abstraction of blood, ergot, and the iodides. *Constitutional* treatment is of the greatest importance and enables the patient to profit from the warning of danger of hemorrhages in other parts of the body.

Septic Retinitis (*Metastatic Retinitis*) results from the lodgment of *septic emboli* in the retinal arteries in the course of puerperal and other forms of septicæmia and pyæmia, and also from infected wounds and foreign bodies. In the first stage there are small white *spots* and *hemorrhages* around the disc and in the macular region; very soon the uveal tract is invaded and the signs of *suppurative choroiditis* (p. 186) appear. The inflammation ends in panophthalmitis or in degeneration of the eyeball without perforation (pseudoglioma). In rare instances the process does not spread to the uvea and then the patient may recover with some vision. Non-infected embolus gives rise to characteristic retinal changes (p. 264).

Uncommon Forms of Retinal Changes.—A number of uncommon pathological conditions are found in the retina which have received names describing the clinical picture in

each case. Among these are *Retinitis Circinata*, a more or less complete circle of white spots or patches surrounding the macula, probably the results of hemorrhages; *Angioid Streaks*, dark-brown, pigmented striæ resembling obliterated blood-vessels, and probably the sequelæ of hemorrhages; *Retinitis Striata*, yellowish or white stripes, sometimes bordered by pigment, radiating from the disc to the periphery, either representing former hemorrhages or cured retinal detachment; *Retinitis Proliferans*, dense, vascularized masses of whitish connective tissue, which project from the retina into the vitreous hiding the disc (p. 221); *Hole in the Macula*, a deep red, round patch, with stippled centre, somewhat less in size than the disc, situated at the macula and looking as if a hole had been punched out, is occasionally the result of contusion or concussion injury.

Retinal Changes due to Excessive Light are seen after injurious exposure of the eye to the *sun* (solar retinitis), especially in watching an eclipse with insufficient protection, or to *electric light* (electric retinitis), as in electric welding. There are *pigment changes at the macula* and there may be slight evidences of retinitis; the subjective symptoms are limited to a central, positive *scotoma* which may become less marked, but does not disappear entirely, and some distortion of objects. The conjunctivitis which results from exposure to excessive light is described on p. 97.

Symmetrical Changes at the Macula in Infancy (*Amaurotic Family Idiocy*) occur in *infants* with general muscular and mental *weakness* and gradual *loss of sight*, ending *fatally* within two years; it is bilateral; several children of the same parents are sometimes attacked, and most cases are of Jewish parentage. Ophthalmoscopically this *resembles embolism* of the central artery: a dark red spot at the macula surrounded by a grayish-white zone somewhat larger than the size of the disc (Plate XVII) followed by optic-nerve atrophy. Histologically, changes in the pyramid cells of the cortex, and degeneration of the cord and ganglion cells of the retina, are found.

Contusion of the Retina (*Commotio Retinæ, Œdema of the Retina*) is a *transient* clouding resulting from a contusion of

the eyeball. There is grayish *œdema* of the retina at the macula and in the neighborhood of the papilla, sometimes also at or opposite the contused spot. Some reduction in vision and changes in the field are present, but disappear with the subsidence of the œdema in a few days. Treatment consists in rest of the eyes, smoked glasses, and atropine.

CIRCULATORY DISTURBANCES OF THE RETINA

Hyperæmia of the Retina, when slight, is recognized by increased *redness of the disc* and by slight *striation* of its margins; such a condition is often found in persons suffering from the effects of errors of refraction (asthenopia) and in those whose vocations expose the eye to excessive light or heat. When marked, hyperæmia is an accompaniment of inflammation of the retina and of surrounding ocular structures. The condition may be either *arterial* or *venous* in type.

Venous hyperæmia is seen as a result of local pressure, in certain general diseases (especially heart disease), emphysema, convulsions, and in most pronounced form in thrombosis of the central vein. A very marked example, called *Cyanosis of the Retina,* is found in patients with congenital heart disease and general cyanosis, presenting great distention of the blood-vessels, especially the veins, and a dark color of the blood contained therein.

Anæmia of the Retina may be merely the ocular expression of a *general* condition, or it may be *local;* its onset may be sudden or gradual. *Acute* anæmia, also known as *Ischæmia of the Retina,* may result from occlusion (embolism), compression (sudden increase of tension), cardiac failure (syncope, cholera), and vasomotor spasm; there are extreme *narrowing* of the retinal arteries, *pallor* of the disc, and *blindness;* examples due to vasomotor spasm are furnished by quinine poisoning, in which some reduction of vision and some contraction of the field are permanent (p. 286), and migraine, in which the effects are transient. The *chronic* form occurs with general anæmia and is frequently seen after *retinal disease,* causing atrophy in which the vessels become narrow,

bordered by white lines of connective tissue, or even changed into empty threads.

Hemorrhages in the Retina often occur without any signs of inflammation.

Objective Signs (Fig. 238, Plate XVIII).—Retinal hemorrhages *vary in size, shape, and position;* they are found most frequently in the neighborhood of the larger blood-vessels and also in the macular region. When situated in the nerve-fibre layer, they have a *striate* or flame-shaped form; when deep, they are *rounded* or irregular in outline. Sometimes a large, round extravasation is seen in the region of the macula, between the retina and vitreous; this is known as a *subhyaloid* (or *preretinal*) hemorrhage. Retinal hemorrhages become *absorbed slowly;* the smaller ones may leave no traces; but more frequently white *spots*, sometimes *pigmented*, indicate their previous site. They may be followed by glaucoma, opacities of the vitreous, and occasionally by detachment of the retina.

Subjective Symptoms.—*Interference with vision* depends upon the size and particularly the situation of the hemorrhage; if at the macula, vision is much diminished. A *scotoma* results if the retinal tissue has been injured. Subhyaloid hemorrhage causes no permanent change in vision after absorption, since the retina is not involved.

Etiology.—The causes of retinal hemorrhages are: (1) *Injuries;* (2) *local* disease of the vessels of the retina and choroid; (3) *cardiac* (hypertrophy and valvular); (4) diseased state of the *blood-vessels*, especially arteriosclerosis and atheroma, frequently associated with heart and kidney disease in old persons, and often a warning of cerebral apoplexy; (5) disturbances in the *circulation* (retinal embolism, thrombosis, hemorrhages in the new-born, menstrual disturbances, and after iridectomy in glaucoma); (6) changes in the *composition of the blood* and in the walls of the blood-vessels, seen in anæmia, pernicious anæmia, leukæmia, hæmophilia, purpura, scurvy, pyæmia and septicæmia, albuminuria, diabetes, malarial fevers, jaundice, poisons (phosphorus), etc.; (7) *loss of blood* (hæmatemesis, menorrhagia, etc.).

Treatment of the etiological factor is indicated. In addition, avoidance of exertion or excitement, *rest* of the eyes, cardiac sedatives, iodides, and, if the blood-pressure is excessive, nitroglycerin.

Changes in the Fundus in Arteriosclerosis are *important* since they indicate similar lesions in other parts of the body, especially the brain; ophthalmological evidence may be the first to reveal the existence of this serious vascular lesion. The fundus may present any or all of the following changes (Fig. 239, Plate XVIII): Increased *tortuosity* and *beaded* appearance of the blood-vessels; greater *opacity* of the arteries and widening of the central light-streak (to a lesser extent this applies also to the veins); *interruption of continuity in the veins* where they are crossed by arteries, and *dilatation* just beyond these points; *white lines* along the borders of vessels due to degeneration and infiltration of the walls (*perivasculitis*); retinal œdema near disc, along blood-vessels, or scattered in spots; *hemorrhages*, scattered or along blood-vessels.

Embolism of the Central Artery.—Obstruction of the central artery of the retina by a *non-infected embolus* is of *infrequent* occurrence; though it causes sudden blindness, this is sometimes unrecognized by the patient, because it is *unilateral* and there is no pain. The *left* eye is the one generally affected.

Objective Signs.—There are no external signs, but the ophthalmoscopic picture is very *characteristic*. Within a few hours, the fundus becomes *pale* and œdematous, *grayish* or even milky; this is most pronounced near the disc and macula and fades out toward the periphery. In the situation of the fovea there is a bright *cherry-red spot* which stands out in marked contrast to the neighboring grayish-white retina; this represents the normal red color of the choroid, here uncovered by the inner layers of the retina and consequently by œdema. The *arteries are very thin* and can be followed only a short distance from the disc; beyond this point they may be lost entirely. The veins also contain less than the normal amount of blood and may present a beaded appearance. Occasionally a few small hemorrhages are seen. Pressure upon the



FIG. 238.—Hemorrhages in the Retina.

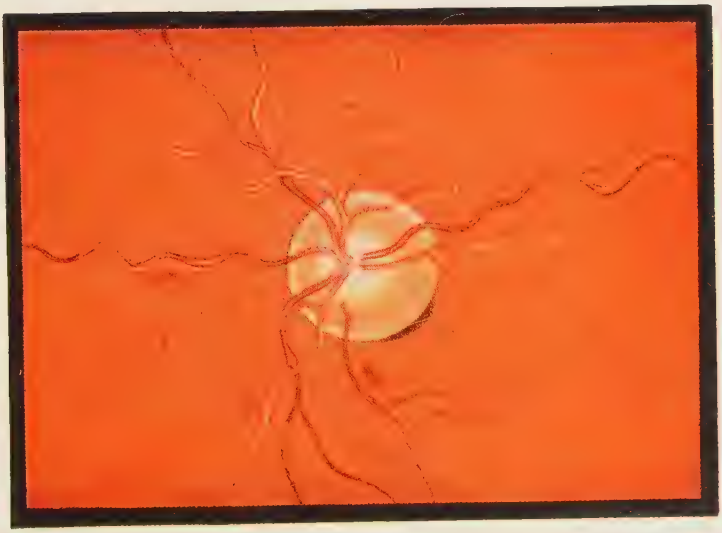

FIG. 239.—Changes in the Fundus in Arteriosclerosis.

eyeball gives rise to the appearance of *broken columns of blood* with clear spaces between them, especially in the veins; this intermittent blood-column is sometimes observed without pressure. Occasionally the embolus can be seen, but usually its presence is shown by a swelling in the artery, beyond which the vessel is thin or obliterated.

After a few days, *degeneration* of the retina occurs, and at the end of a few weeks *atrophy*. The œdema subsides, the retina and disc atrophy, the latter becomes white with sharply defined outline, and the blood-vessels become shrunken or are represented by white lines.

Subjective Symptoms.—There is *sudden and complete blindness;* even perception of light is lost. Occasionally a small part of the retina preserves its function; this occurs when there are cilio-retinal vessels (an anastomosis between the retinal and the short posterior ciliary arteries); this region usually lies between the disc and the macula.

The foregoing description applies to cases in which the *main trunk* of the central artery is occluded. The embolus may, however, lodge in one of the *branches* of the central artery. In such cases the interference with sight and the changes in the background will be limited to the *area supplied by the occluded branch.*

Etiology.—The condition is most frequently due to *valvular heart disease,* less often to atheroma, aneurism of the aorta or carotid, Bright's disease, and pregnancy.

A *thrombus* of the central artery may give rise to the same signs and symptoms as embolism, and a differential diagnosis is difficult or impossible.

Treatment is rarely effective. If the case is seen early, inhalations of *amyl nitrite, massage* of the eyeball, and paracentesis of the cornea may be employed for the purpose of driving the plug along into one of the smaller branches, where it will give rise to less serious results; in a few cases, such treatment has been beneficial.

Thrombosis of the Central Vein may occur in *old persons* with atheroma and cardiac disease; it also follows cellulitis of the orbit. It is one of the causes of hemorrhagic retinitis.

It may be complete or partial. There is *diminution of vision*, either corresponding to the entire field, or if only a branch is affected, to the part of the retina supplied by it. The *veins* are greatly *engorged* and tortuous, the *arteries* very *small*, there are numerous large *hemorrhages*, and indistinctness of the margins of the disc. The condition usually ends in atrophy of the retina and disc. There is no treatment.

PIGMENTARY DEGENERATION OF THE RETINA, OR RETINITIS PIGMENTOSA

A *chronic*, progressive *degeneration*, consisting of *atrophy* of the retina with characteristic deposits of *pigment*.

Subjective Symptoms.— *Night blindness* (nyctalopia), concentric *contraction of the field* of vision, progressive *diminution in sight*, terminating in advanced years in complete *blindness*.

In early life there is but slight reduction in the extent of the field with good illumination, and central vision is often perfect. But with feeble illumination, the peripheral parts of the retina do not react, and on this account the patient cannot find his way about at night, because the field is small. With increasing years, the field becomes contracted even with good illumination. Finally, in advanced life, central vision becomes poor, and gradually complete *blindness* follows.

Ophthalmoscopic Examination (Fig. 240, Plate XIX) shows *black spots* in the *periphery* of the fundus; these have the shape of branching cells, like bone corpuscles with connecting processes, and are found especially along the blood-vessels; they commence at the equator; in the course of years new spots form, and in this way the *pigment circle* gradually approaches the disc and also increases its width towards the periphery; the process is one of migration from the pigment layer of the retina. The larger *choroidal vessels* become plainly visible on account of absorption and decoloration of the retinal pigment. The disc and retina are *atrophied;* the disc has a *yellowish, waxy* appearance. The retinal *arteries* are very *small* and in the periphery are represented by mere threads. Posterior cortical cataract often develops.

Atypical Forms.—There are cases of retinitis pigmentosa

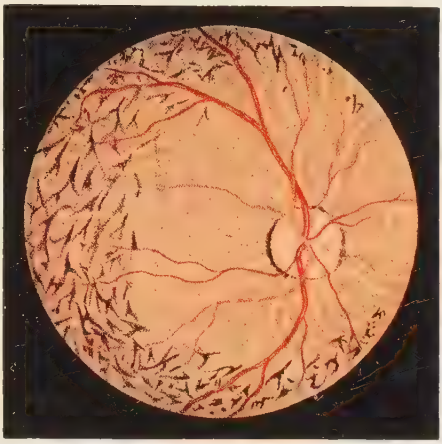

FIG. 240.—Pigmentary Degeneration of the Retina.

FIG. 241.—Detachment of the Retina.

in which all the symptoms of this disease are present, and the ophthalmoscope shows all changes *except* the presence of *pigment*, and others in which the pigment is distributed in an *atypical* manner and the spots are rounded or irregular in shape.

Syphilitic choroidoretinitis may present a picture similar to that of retinitis pigmentosa, but may be differentiated by the patches of choroidal atrophy, the absence of characteristic shape of the spots, their more irregular distribution and their position beneath the blood-vessels, and by differences in the character of the field.

A rare affection, similar to retinitis pigmentosa, having all of its symptoms except the pigmentation, is called *Retinitis Punctata Albescens;* it presents a great number of small, white spots scattered all over the fundus.

Occurrence.—The disease affects *both* eyes. It is either *congenital* or develops in childhood. It is *hereditary* and is often found in the offspring of consanguineous marriages; not infrequently other congenital defects, such as deafness and defective intelligence, are present. It may be complicated with other ocular anomalies.

Treatment is of no avail in arresting the progress. Galvanism, strychnine, thyroid, and iodides may be tried.

DETACHMENT OF THE RETINA

Retinal detachment (*Ablatio Retinæ, Amotio Retinæ*) is a separation of the retina from the choroid. The name usually refers to a separation by serum (*serous detachment*), but detachment may also occur as a result of hemorrhage, exudation, or tumor.

Subjective Symptoms.—There is more or less complete *loss of vision* in that part of the field which is opposite to the detachment, causing the appearance of a dark *cloud* before the eye and a corresponding limitation in the field as shown with the perimeter; early symptoms are *metamorphopsia* and flashes of light (*photopsia*). Central vision is preserved as long as the macula is not included.

Ophthalmoscopic Signs depend upon the degree and extent

of detachment. In addition to the other methods, the ophthalmoscope should be used at a distance.

When the detachment is flat, the retina appears but slightly changed; it is somewhat *cloudy* and its *vessels* are *dark* and *tortuous;* the variation in *level* of the affected portion can be recognized by the difference in the refraction of a blood-vessel on the separated part as compared with the rest of the fundus.

When the detachment is steep, as is generally the case, it is usually found near the *periphery.* It is at first limited in extent (*partial*); it may commence at any part of the retina, but as a result of sinking of the subretinal fluid it is usually found *below.* It tends to enlarge and become *complete,* then involving the entire retina, attached only at the disc and the ora serrata. It presents a collection of grayish, bluish-gray, or greenish *folds* (Fig. 241, Plate XIX) with white tops presenting a bright sheen, *projecting* a variable distance into the vitreous and *shaking* with movements of the eye. The *blood-vessels* pass over and follow these folds and are therefore very *tortuous,* and *hidden* at places; they appear *prominent* and of a *dark red,* almost black color and smaller than normal. Sometimes a rupture can be seen in the separated retina through which the choroid is visible. In the later stages, opacities of the vitreous and cataract are often added. The rest of the fundus presents a normal picture. Externally the eye appears normal, but tension is usually lowered and the anterior chamber deepened.

Etiology.—Detachment may be due to *disease* or *injury;* occasionally no cause can be found. When due to *disease,* it is most often found in *myopia* of high degree, and after retinitis, iridocyclitis, and iridochoroiditis; in such cases the condition probably results from the *shrinking* of the organized exudates in the vitreous, which thus *pull* the retina from its attachment; it may also result from choroidal hemorrhage, exudate, and sarcoma, in which instances the retina is *pushed* forward. *Traumatic* detachment is usually the result of blows, but occurs also after accidental or operative wounds, especially when there has been loss of vitreous.

Diagnosis is readily made after ophthalmoscopic examina-

tion and a study of the field; but it is sometimes difficult to decide whether the detachment is serous or due to sarcoma of the choroid (p. 194).

Prognosis is *unfavorable.* The detachment tends to enlarge and to become complete. Even after improvement or reattachment, *relapses* are the rule, and complete *blindness* is the usual end. Rarely spontaneous reattachment occurs.

Treatment is sometimes followed by *temporary improvement,* but is rarely productive of lasting benefit. In recent cases, the best treatment is *absolute rest in bed,* locally *atropine* and *dionine,* a firm *bandage* to both eyes, iodides and injections of *pilocarpine* to produce sweating; this treatment must be kept up for six or eight weeks.

Puncture of the sclera (posterior sclerotomy, p. 215) is frequently resorted to and may, rarely, be successful. *Subconjunctival injections* of solution of sodium chloride, either of physiological strength, or five or ten per cent., have proved of value in occasional instances.

Trephining of the sclera over the seat of the detachment, followed by *aspiration* of the subretinal fluid in this situation, has also been followed by an occasional cure.

CHAPTER XIX

DISEASES OF THE OPTIC NERVE

Anatomy.—The optic nerve may be divided into (1) an *intraocular* portion, the head of the optic nerve; (2) an *orbital* portion extending from the eyeball to the optic foramen; and (3) an *intracranial* portion situated between the optic foramen and the chiasm.

The nerve pierces the sclera and choroid a little to the inner side of the posterior pole of the eyeball. At this point the outer layers of the sclera become continuous with the sheaths of the nerve, while the inner layers together with a few bands from the choroid stretch across the foramen, presenting numerous openings for the passage of the separate bundles of the optic nerve; this sieve-like arrangement is known as the *lamina cribrosa*. Here the *nerve fibres lose their medullary layer* and become transparent. Spreading apart before reaching the level of the retina, they leave a funnel-shaped depression at the middle of the disc (Fig. 43), the *physiological excavation*.

The *lamina cribrosa* represents the weakest portion of the layers of the eyeball, and in increased tension is the first to recede. It surrounds the bundles of the optic nerve with fibrous rings of connective tissue, which serve as constricting bands when swelling occurs.

The *orbital portion* of the optic nerve presents a sigmoid curve permitting free movement of the eyeball. The nerve consists of bundles of nerve fibres separated by connective-tissue septa; between these there are *lymph spaces*. The optic nerve is surrounded by *three sheaths* originating from the three envelopes of the brain, and known as the pial, arachnoid, and dural sheaths; between the pial and the dural sheaths is a space, the *intervaginal space*, divided into two parts by the arachnoid sheath. The two spaces thus formed are *lymph spaces;* they are lined by endothelium, and communicate with the corresponding cerebral spaces. Anteriorly, the intervaginal space ends in a blind extremity and the sheaths unite with the sclera.

A short distance from the eyeball, the *central artery* (a branch of the ophthalmic) enters, and the *central vein* emerges; the latter empties into the superior ophthalmic vein or directly into the cavernous sinus.

The *intracranial portion* of the optic nerve is short and flattened. The *optic foramen* forms an unyielding ring which compresses the nerve in inflammation and injury.

Affections of the Optic Nerve comprise (1) hyperæmia, (2) *inflammation*, (3) *atrophy*, and (4) tumors (very rare)

Hyperæmia or Congestion of the Optic Disc.—*The normal disc varies greatly in color;* hence it is often difficult to decide whether the papilla is congested or not. Hyperæmia shows itself in increased *redness* due to capillary injection, slight *blurring and striation* of the margins of the disc often limited to a portion of the circumference, especially the nasal side, and some dilatation and tortuosity of the retinal vessels.

Such a picture is frequently presented in *eye strain* from hyperopia and astigmatism, excessive use of the eyes, especially with insufficient or excessive light, and after lengthy exposure to glare and heat. It is also found with inflammations of the deeper portions of the eyeball, or as the *incipient* stage of optic *neuritis*, and occasionally as a *congenital* anomaly.

When pronounced in degree, whether congenital or due to the above-mentioned causes, this condition is often called *Pseudoneuritis.*

Inflammation of the Optic Nerve, known as *Optic Neuritis,* is divided into:

1. *Intraocular Optic Neuritis,* in which the *head* of the optic nerve is the part affected, and in which there are marked *visible* changes in the disc.

2. *Retrobulbar Neuritis* affecting the nerve *behind the eyeball,* in which disc changes are *slight* or *absent,* and their existence is inferred from subjective symptoms.

INTRAOCULAR OPTIC NEURITIS

This affection is also known as *Descending Neuritis, Papillitis, Choked Disc,* and *Papillœdema.* These names are often used interchangeably and much confusion in regard to the exact meaning of each has arisen in consequence. They do not represent identical ophthalmoscopic pictures. It will be convenient to describe the symptoms of this disease in general, and then to consider the clinical forms for which each of these names is a suitable title.

Symptoms.—There is *disturbance of vision,* sometimes insignificant, often considerable, but not always proportionate

to the degree of changes as revealed by the ophthalmoscope; there may be complete blindness. The *field* of vision is usually *contracted* peripherally, especially for colors; there may be reversal of the color fields; the blind spot is enlarged; there may be hemianopsia or scotomata. There is no pain, and there are no external signs.

Ophthalmoscopic Signs.—The *disc* is *swollen*, projecting (Fig. 242 and Plate XX), enlarged, of *whitish* or gray color with reddish centre, *striated*, and often presents white spots and *hemorrhages;* its situation is recognized only by the convergence of the retinal blood-vessels, its margins having become indistinguishable. The retinal *vessels* are altered and seem *interrupted* where they are covered by the swelling; the arteries are thin, the *veins* much distended, and very *tortuous*. The adjacent retina is œdematous, congested, and presents white patches and hemorrhages.

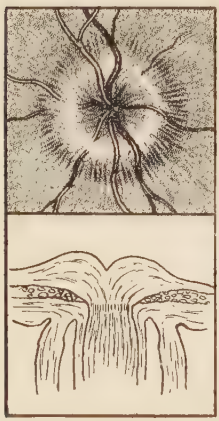

FIG. 242.—Choked Disc. The upper portion represents the ophthalmoscopic appearances; the lower half, a longitudinal section.

Clinical Forms.—We recognize two types of intraocular neuritis:

1. *Choked Disc* or *Papillœdema*, in which the condition is suggestive of compression causing *œdema and engorgement without inflammation*, and the picture is the following: *Great swelling and protrusion of the disc*, marked distortion and tortuosity of the retinal veins, and hemorrhages upon and near the œdematous papilla; the lesions are *limited* rather sharply *to the disc* and the surrounding retina is scarcely changed (Fig. 244, Plate XX).

2. *Descending Neuritis* or *Papillitis*, in which the appearances indicate *inflammation*, and consist of hyperæmia and *moderate swelling of the disc* with exudate covering the surface and margins, and slight fulness of the veins; the process is not limited to the disc but *extends to the adjacent retina.*

When to the signs of neuritis just given, there are added

PLATE XX



FIG. 243.—Neuroretinitis.

FIG. 244.—Choked Disc.

evidences that the retina is extensively involved, such as hemorrhages along retinal vessels and spots of exudate and degeneration (Fig. 243, Plate XX), the term *Neuroretinitis* is used.

Though the distinction between choked disc and papillitis is often marked, *transition forms* occur frequently.

The degree of projection of the disc is estimated by the difference in refraction between the most protruding part of of the disc and some unaffected portion of the retina, measured with direct ophthalmoscopy; this is always 2D., and often more, in choked disc.

Course and Prognosis.—Though sometimes rapid, the course is usually *chronic,* extending over many months. The changes may subside and the disc may regain its normal appearance with the preservation of good sight (especially in syphilitic cases), and in others in which the cause of the affection is removed before the process has advanced too far or lasted too long. But in many instances intraocular neuritis is followed by *Postneuritic Atrophy:* The disc becomes white or grayish-white, its margins irregular, and surrounded by changes in the choroid, while the exudation changes into connective tissue which covers the lamina cribrosa; the blood-vessels are contracted, the veins preserving some of their tortuosity, and are frequently bordered by white lines (Fig. 247, Plate XXI). The prognosis is, therefore, always *serious;* when the course is unchecked, vision is finally either much impaired or lost. The affection is usually *bilateral,* but one eye may be affected before the other.

Etiology.—The causes are: diseases of the brain and its envelopes; syphilis; general diseases; anæmia, either simple, or the acute form due to loss of blood; diseases of menstruation; nasal accessory sinus disease; lead poisoning; heredity; idiopathic (when no cause can be found); and orbital and periorbital affections.

Brain Tumor is the most frequent cause; papillitis occurs in 90 per cent. and then most often assumes the *choked disc type;* the papillœdema may be the first symptom of the intracranial growth. The occurrence or degree of papillitis depends to a certain extent only upon the size or the situation

of the tumor; the greater swelling is most often on the same side as the tumor, but there are many exceptions to this; it is often most marked with cerebellar tumors. Occasionally it gives rise to a picture resembling that of albuminuric retinitis with its star-shaped figure at the macula.

Next in frequency comes *meningitis*, especially basilar and tuberculous; in such cases the papillitis is apt to be of the descending neuritis type. Then come abscess, hydrocephalus, and enlarged pituitary body in acromegaly.

Syphilis is a frequent cause, and acts either by direct implication or through the development of specific affection in the cranial or orbital cavities.

Acute infective diseases (influenza, measles, scarlatina, diphtheria, typhoid, erysipelas) are occasional causes. General affections, such as rheumatism, malaria, nephritis, and arterial disease, are sometimes responsible; also deformities of the skull (oxycephalic) and, possibly, exposure to cold.

Orbital and periorbital affections include inflammations of the orbit, tumors of the orbit and optic nerve, and *disease of the nasal accessory sinuses*, tonsils, and dental disease; these constitute the examples of unilateral cases.

Pathology.—There are swelling, exudation of leucocytes, venous engorgement, hemorrhages, and distention of the intervaginal space. Though numerous hypotheses have been advanced to explain the production of choked disc, the exact mechanism is still unsettled. At present it is generally believed to be due to *increased intracranial pressure* forcing cerebro-spinal fluid into the intervaginal space of the optic nerve, causing stasis in the region of the lamina cribrosa and compression of the vessels, resulting in venous engorgement and œdema. But it is also conceded that secondary factors, such as direct transmission of *inflammation* from the brain and excitation by irritating substances (*toxins*), may be operative.

Treatment is directed against the *cause*. In *syphilis*, *salvarsan*, followed by *mercury* and iodides; even in non-specific cases, mercury may be of value. Orbital and periorbital affections re-

quire appropriate surgical treatment. Locally, rest of the eyes and shading from light are indicated.

Cerebral Decompression is often done to reduce the intracranial pressure responsible for choked disc (temporal for pretentorial growths, suboccipital for subtentorial tumors). This operation causes a subsidence of the papillary swelling and an improvement in vision if resorted to before much degenerative change in the nerves has taken place; incidentally other symptoms are relieved and life prolonged.

Lumbar Puncture is resorted to not infrequently not only for diagnosis but also to reduce intracranial pressure and relieve choked disc, care being exercised, especially with posterior fossa tumors, since sudden death has followed this procedure. Puncture of the corpus callosum with drainage of the ventricle has also been used for the same purpose.

Retrobulbar Neuritis (*Orbital Optic Neuritis*) is an interstitial neuritis of the axial part of the *orbital portion* of the optic nerve (*Axial Neuritis*). With few or no visible changes in the disc, at first, the diagnosis is made from the visual disturbance. Only the *papillo-macular* fibres are affected; hence the change in the field of vision is a *central scotoma*, often relative. There are two forms, *acute* and *chronic*.

ACUTE RETROBULBAR NEURITIS

This rather uncommon affection is generally *unilateral*, occasionally bilateral.

Symptoms.—Severe *headache* on the same side, *pain* in the *orbit* aggravated by movements of the eye and upon pressing the eye backward. With these symptoms there is rapid *impairment of sight*, beginning in the centre of the field and progressing in the course of a week to partial or complete blindness. Externally the eye appears normal.

Ophthalmoscopic Signs.—At first there are no changes; later there may be slight *hyperæmia* of the disc and *haziness* of its margins, with distention and sometimes diminished calibre of the retinal vessels.

Course.—The disease runs an *acute* course, and after a

month or two, if properly treated, the sight usually becomes *normal;* or the cure is partial, and a *central scotoma* remains; rarely it terminates in permanent and total blindness. Relapses are sometimes observed.

Etiology.—Infection from neighboring parts (*accessory sinuses* of the nose) or oral sepsis (teeth, tonsils); direct extension from the orbit (cellulitis, periostitis); general diseases (*syphilis,* rheumatism); acute infectious diseases (*influenza*); poisons (alcohol, lead); menstrual disturbances; *disseminated sclerosis;* exposure to cold; sometimes no cause can be found.

Treatment.—Treatment of the *cause*. Diaphoresis; potassic iodide and mercury; also strychnine.

CHRONIC RETROBULBAR NEURITIS TOXIC, TOBACCO, OR ALCOHOL AMBLYOPIA

A chronic affection of the orbital portion of the optic nerve, of *frequent* occurrence, usually attacking *both eyes*, and due in the great majority of cases to excessive indulgence in *tobacco, alcohol,* or *both* combined.

Symptoms.—There is gradual *diminution* in acuteness of *sight;* foggy vision; the patient sees better in the evening and the visual disturbance is *more marked in bright light.* The field of vision presents the normal peripheral boundary, but there is a *central color scotoma* for red and green (Fig. 245), corresponding to the distribution of the papillo-macular fibres of the optic nerve; the color defect is more marked for green than for red; sometimes the scotoma becomes absolute.

Fig. 245.—The Field of Vision in Toxic Amblyopia showing Central Color Scotoma.

Ophthalmoscopic Signs.—At first there are no changes in the papilla, or merely slight hyperæmia; later, there is very often a *pallor of the temporal side of the disc.*

Course and Prognosis.—The progress of the disease is *slow.* If poisoning continues, vision becomes more impaired, may be much reduced, or even lost. If the patient stops the use of

FIG. 246.—Simple Atrophy of the Optic Nerve.

FIG. 247.—Post-Neuritic Atrophy of the Optic Nerve.

the toxic material, there is usually *gradual improvement* and sight is often restored to the normal, with complete disappearance of the scotoma. But in severe cases, there may be some permanent reduction in the acuteness of vision, and the relative scotoma may be permanent.

Etiology.—The condition results most frequently from over indulgence in *tobacco* whether in smoking or chewing, occasionally after snuff-taking. The stronger tobaccos used in cigars and pipes are the forms which are most frequently responsible. Certain individuals are more susceptible than others. Impairment of the general health predisposes, as does also the practice of smoking when the stomach is empty. It occurs almost exclusively in *middle-aged* or *elderly* men. *Alcohol* also constitutes a very frequent cause; in most cases *both alcohol and tobacco* act together. *Other poisons* which in toxic doses may cause similar amblyopia are chloral, iodoform, lead, arsenic, the toxin of diabetes, bisulphide of carbon, nitrobenzol, and anilin.

Pathology.—The process consists of a *degeneration* of the *ganglion cells* in the macular region with *interstitial neuritis* of the papillo-macular bundle in the optic nerve, and subsequent degeneration of these fibres.

Treatment consists in *abstinence* from tobacco and alcohol; this is the most important part of the treatment. *Sweating* by various means, large quantities of *water* taken between meals, and moderate doses of *potassic iodide* will prove effective. Later *strychnine* is prescribed in increasing doses, up to the limit of tolerance.

ATROPHY OF THE OPTIC NERVE

This affection occurs either (1) as a *primary* disease (*simple, gray, non-inflammatory,* or *progressive atrophy*) or (2) *secondary* to some other affection of the nerve or retina (*neuritic, postpapillitic,* or *inflammatory atrophy*); in the latter class belong also *retinitic* and *choroiditic* atrophy.

Symptoms.—There are *reduction* in the acuteness of *vision,* concentric *contraction* or irregular or sector-shaped peripheral defects *of the field* (Fig. 248), first for colors and then for form,

diminution in the light sense, sometimes *scotomata,* and *color blindness* (first for green, then for red, then for blue). These symptoms tend to *progress* and end in complete *blindness.*

Ophthalmoscopic Signs depend somewhat upon whether the type is primary or secondary:

Primary Atrophy (Fig. 246, Plate XXI): The *disc* is *white,* grayish, or bluish-white, its edges are *sharply defined* and regular, its size is somewhat diminished, and it presents a saucer-shaped excavation (Fig. 186); the *lamina cribrosa* is often seen very *plainly;* the minute vessels of the disc have disappeared; the retinal vessels may appear normal or the arteries may be diminished in calibre.

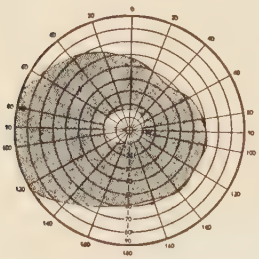

FIG. 248.—Marked Concentric Contraction of the Field of Vision in Optic-Nerve Atrophy.

Postpapillitic Atrophy (Fig. 247, Plate XXI): The *disc* is *dense white* or grayish in color, sometimes with a bluish tint, its margins *irregular* and somewhat *hazy,* its minute vessels lost, and it is *covered by connective tissue* resulting from the organization of the previous exudate; on this account the lamina cribrosa is hidden; the retinal arteries are narrow, the *veins* normal in size or contracted and generally *tortuous,* and both sets are apt to be enclosed by *white lines.*

Retinitic and Choroiditic Atrophy: The *disc* has a grayish-red or *yellow,* waxy appearance (Fig. 240, Plate XIX), its outlines are somewhat *indistinct,* the *vessels* are exceedingly *narrow* and many disappear entirely, and the retina presents evidences of the antecedent choroiditis or retinitis.

After a time, the differences in the appearances of simple and postneuritic atrophy become much less marked.

It should be borne in mind that the *disc varies in color in health* and may appear atrophied as the result of congenital or senile peculiarities, although vision is normal and the field perfect; hence the diagnosis in many cases cannot be made from the ophthalmoscopic signs alone, especially when these signs are not pronounced.

Etiology.—*Simple atrophy* is frequently due to *spinal* diseases, especially *locomotor ataxia*, developing as an early symptom in one-third of the cases of this affection. It is common also in affections of the *brain*, especially disseminated sclerosis, general paralysis of the insane, and tumors. It may also be due to *syphilis*, malaria, diabetes, acromegaly, impaired nutrition, arteriosclerosis, and certain poisons (including wood-alcohol). Occasionally it is hereditary, and in some cases *no cause* can be found. Hereditary cases occur in young adult males, involve the papillo-macular bundle, are accompanied by central scotoma, and the affection is known as *Leber's Disease.*

Secondary atrophy follows choked disc, descending neuritis, pigmentary degeneration of the retina, and embolism and thrombosis of the central artery; it may also be consecutive to choroiditis, retinitis, glaucoma, hypophysis disease, and orbital inflammations. It may result from injury to the optic nerve due to fracture of the orbital canal, following a blow or other violence; in such cases the atrophy does not show itself for a number of weeks, though reduction of vision and contraction of the field or even blindness ensues immediately.

Pathology.—The process consists of increase in the interstitial connective tissue with atrophy and disappearance of the nerve fibres.

Course and Prognosis.—The affection occurs chiefly in *middle life*, the course is *slow* extending over many months, and the prognosis is usually *unfavorable*. Simple atrophy generally progresses to absolute blindness. In *secondary* atrophy the prognosis is *better*, and depends upon the extent to which the optic nerve has escaped from the destructive influences of the preceding processes.

Treatment consists in attempting to control the *cause*. For the atrophy itself very little can be done. Potassium iodide, strychnine hypodermically, mercury, nitroglycerin, galvanism, and the high-frequency current are remedies often employed; in syphilitics, injections of salvarsan and salvarsanized serum intraspinously should be tried.

CHAPTER XX

AMBLYOPIA, AMAUROSIS, AND DISTURBANCES OF VISION WITHOUT APPARENT CHANGES

Amblyopia is a *reduction in the acuteness of vision* which cannot be relieved by glasses and which is not dependent upon any visible changes in the eye. The term is sometimes used in a less restricted sense to designate *poor sight*, even when changes are found in the eye, as, for instance, toxic amblyopia in which temporal pallor of the disc exists.

Amaurosis is the name applied to *absolute blindness* when unaccompanied by discoverable ocular changes; the use of this term is, however, sometimes extended so as to comprise all cases of absolute blindness, including those which show ophthalmoscopic or external changes.

CONGENITAL AMBLYOPIA AND AMBLYOPIA EX ANOPSIA

Congenitally defective vision usually affects *one eye;* it is frequently associated with high degrees of *hyperopia* and *astigmatism.* Probably in many of the so-called congenital cases, the amblyopia is really acquired —the errors of refraction have prevented perfect images from being focussed on the retina, and this lack of training has caused poor vision. The most careful correction of the error of refraction fails to produce normal vision; in young patients, however, the sight can frequently be improved or brought up to the normal after suitable glasses have been worn for a time.

Amblyopia ex Anopsia.—Any interference with vision, either congenital or dating from early life, which prevents perfect focussing upon the retina, such as cataract and corneal opacity, causes *amblyopia from non-use;* hence the advisability of operating upon congenital and infantile cataracts early. An obstacle to vision beginning after the age of

seven or eight years does not usually interfere with the functional activity of the retina.

Unilateral amblyopia predisposes to *squint* by lessening the value of binocular vision. Very commonly amblyopia develops in an eye which has squinted from early life on account of its exclusion from the visual act, the retinal image in this eye being suppressed (p. 373). Exercise of such an eye before the end of the sixth year, by forcing it to work while the sound eye is covered or atropinized, will frequently improve its visual power. Bilateral amblyopia is nearly always associated with *nystagmus*.

Congenital Word-Blindness is met with not infrequently, especially in boys, and is supposed to be due to a defect in the visual memory centre for words and letters. The defect consists in an inability or difficulty in reading and spelling. If detected early in life, much improvement can be effected by training.

CONGENITAL COLOR AMBLYOPIA

Congenital Color-Blindness occurs in from 3 to 4 per cent. of males and in only 0.3 per cent. of females. It generally affects both eyes, is often hereditary, and the functions of the eyes are otherwise normal. The cause and pathology are unknown; the defect is incurable, but the color sense can be developed, if training is begun at a sufficiently early period of life. The condition is usually a *partial achromatopsia*—a loss of perception of one or two of the fundamental colors (red, green, and blue). The absence of all appreciation of colors (*total achromatopsia*) is very rare as a congenital defect, though it is not uncommon in acquired color blindness occurring in optic-nerve atrophy.

Theories of Color Perception and Color Defects.—A number of theories have been advanced to explain color vision and its derangements. The principal ones are those of Young-Helmholtz, Hering, and Edridge-Green.

(1) *The Young-Helmholtz Theory* assumes that there are three sets of color-perceiving elements in the retina, each of which, if stimulated alone, would give rise to the sensation of one of the three fundamental colors—red, green, and violet; and that all other colors arise from com-

binations of these. With a defect of one of these primary perceptions, a color will be seen as if composed of the remaining two only. According to the color which is deficient, the patient is said to be *red-blind*, *green-blind*, or *violet-blind*. The more commonly recognized forms are *red blindness*, *green blindness*, and *red-green blindness*.

(2) *The Hering Theory* is that the color sense depends upon chemical changes in three different visual substances in the retina—white-black, red-green, and blue-yellow, by the decomposition and restoration of which substances the sensations of color are produced; for instance, red light produces destruction in the red-green substance and thus the sensation of red; green light causes a restoration in the red-green substance and thus the sensation of green. According to this theory, color blindness is caused by the absence of one or two of these visual substances; if one is absent, the patient is either red-green (frequent), or blue-yellow (rare) blind; if two are absent, nothing but the white-black substance is left, and the patient has total color-blindness, everything appearing gray.

(3) *The Edridge-Green Theory* supposes that a photograph is formed in the retina by decomposition of the visual purple in the rods; this chemically stimulates the ends of the cones, causing a visual impulse to be transmitted through the optic-nerve fibres to the brain. It assumes that this impulse differs in quality according to the wave-length (color) of the rays of light producing it, and that there is a special centre in the brain to distinguish these differences. Edridge-Green describes two distinct kinds of color blindness: (a) an inability to perceive certain rays of the spectrum, the latter being shortened at one or both ends, *e.g.*, a red-blind person will say that he sees no light at all when shown a pure red light by means of a lantern; (b) a defect in the power of distinguishing differences of wave-length (color) of light, though the light itself is perceived.

Tests for Color Vision are particularly useful in the examination of employees in certain occupations in which perfect color perception is essential. This is of especial importance in the *railway* and *steamship* service, in which the most commonly used *signals* are *red* and *green*, the colors in which most color-blind persons are defective.

The most common and convenient method of examination is *Holmgren's Test* with a large assortment of colored worsteds. This collection consists of (1) certain colors called "*test colors*" (a pale *green*, a light *pink*, and a bright *red*), (2) lighter tints and darker shades of these colors ("*match colors*") and (3) "*confusion colors*" (yellow, brown, gray, drab, fawn, mauve, pale blue, etc.), hues which experience

has shown that the color-blind individual will select as matching the test colors, but which appear entirely different to the normal eye. The test must be made in good daylight.

The pale-green sample is given to the individual and he is required to select colors which match the test sample; if he does this correctly, he has normal color sense. If he not only selects similar colors but also confusion colors, and in addition shows a certain hesitancy, his color sense is defective.

Next a pink skein is selected and the person examined is asked to match this. If besides similar skeins he also selects blue or violet, he is *red-blind;* if he selects green or gray, he is *green-blind.*

Finally, the bright-red test skein is given to the individual for matching. If, besides reds, he chooses green and brown colors darker than the red, he is *red-blind;* if he selects shades of those colors lighter than the red, he is *green-blind.*

Edridge-Green uses four test colors (orange, violet, blue-green, and red) in skeins of colored wool and in a lantern with colored glasses. The person examined is required to *name* and to match the four test colors.

The skeins of colored worsteds have been collected upon a stick (*Thomson's Test*) and numbered, so as to facilitate testing of employees and the record of their examinations. Railroad and steamship men are often tested by *Color Test Lanterns* (Thomson's, Williams', Edridge-Green's) in which colored discs are slid in front of an aperture; over these smoked glass can be placed, so as to imitate the appearance of signal lights under all conditions of weather and atmosphere.

The *spectroscope* is also employed for testing the color sense.

Acquired Color Blindness is often found as a symptom of diseases of the retina and optic nerve. It is generally present in *optic-nerve atrophy* when vision is markedly impaired.

Colored Vision is occasionally complained of by patients with or without changes in the retina. The most frequent form is *red* vision (*Erythropsia*) after cataract extraction. Rarely green, blue, yellow, or white vision is met with.

HYSTERICAL AMBLYOPIA

This affection usually occurs in *young* girls and women, occasionally in young persons of the male sex, and is most often *unilateral.*

Symptoms.—The most constant symptom is a *diminution* in the acuteness of *vision* which frequently amounts to complete *blindness.* The *field* of vision is *contracted* concentrically, both for white and colors; it may be tubular; since the retina becomes exhausted rapidly, this limitation may become more marked with each succeeding test during the same examination. The *color fields* have not the same relative areas as with the normal eye; they may be larger than that for white; their order is often *reversed—i.e.*, green the largest, red next, and blue the smallest. There may be central, annular, or irregular scotomata or hemianopsia. A *great variety* of other ocular symptoms may be present, such as photophobia, flashes of light, blepharospasm, corneal anæsthesia, monocular diplopia, ptosis, and metamorphopsia. The pupillary reflexes and ophthalmoscopic appearances are normal.

With these ocular manifestations there are usually *other hysterical symptoms,* especially hemianæsthesia of the affected side. It is sometimes difficult to distinguish between this affection and malingering. It sometimes follows injuries (traumatic neurosis) even when these do not involve the eye.

Prognosis is *good,* but the affection may last many months.

Treatment is directed to the hysterical condition. Locally, *electricity,* massage, and hypodermic injection of *strychnine* are productive of good results, probably through psychic or suggestive influences.

SIMULATED AMBLYOPIA

Patients sometimes *pretend* to be blind in *one eye* in order to escape military duty or to recover damages for alleged injury; occasionally bilateral blindness is simulated. The detection of pretended monocular blindness is usually easy, but occasionally difficult. The following tests may be employed:

Tests.—1. Place a lighted candle fifteen or twenty feet in

front of the patient and put a *prism* of 6°, base upward or downward, before the sound eye; if the patient sees *double* it is an indication of binocular vision.

2. With the lighted candle in the same position, cover up the supposed blind eye. Then produce *monocular diplopia* by moving a 6° prism, base upward or downward, until the apex corresponds to the centre of the pupil. Next uncover the blind eye and at the same time move the prism until it covers the entire pupil. If now there is still double vision (binocular diplopia) it is evident that both eyes see.

3. Place a *strong convex lens* (12 D.) before the good eye and a weak concave lens (0.25 D.) in front of the supposed blind eye, and direct the patient to read the distant test types; if he succeeds, it is proof of malingering, since it is impossible for him to see with the sound eye when covered by the strong lens.

4. Snellen's test types of alternate *red and green* color are often used to detect malingering: We place a red glass before the admittedly sound eye; if the subject reads the green letters, he must do so with the so-called blind eye, since only the red letters can be seen through the red glass.

It is uncommon for a patient to simulate blindness in *both eyes*, and more difficult to detect him in such cases. A diminution in acuteness of vision of both eyes is more frequently feigned than binocular blindness. In such cases, malingering is suspected, when there are *absence of agreement* in the results of the functional and objective examination of the eyes, *contradictory statements* regarding the different steps in the functional examination, or contraction of the pupils to light. In some instances, the pupils react on exposure to light in cases of absolute blindness, the lesion being situated in the visual centres or in the connection between these centres and the corpora quadrigemina (3, Fig. 249). In feigned binocular blindness a *close watch* must be kept on the patient when he thinks he is free from observation, and the following test may be employed: Place a lighted candle in front of the patient; hold a 6° prism base outward before one eye; if both eyes see, the one covered by the prism will move

inward in order to avoid diplopia; on removing the prism it will move outward, the other eye remaining fixed.

AMBLYOPIA AND AMAUROSIS FROM VARIOUS CAUSES

Besides the forms of amblyopia already described, there are others, of less frequent occurrence, due to uræmia, reflex irritation, malaria, quinine, and wood-alcohol. A considerable number of *drugs and poisons*, also tea and coffee, are occasionally responsible for more or less amblyopia.

Uræmic Amblyopia has been described on p. 258.

Reflex Amblyopia, due to reflex irritation, is rare and of rather doubtful occurrence, except in the case of the teeth, irritation from which has been found responsible for amblyopia in occasional instances.

Malarial Amblyopia has been observed, without apparent changes in the fundus, as a result of the action of the malarial poison upon the optic nerve. It affects one or both eyes, lasts some hours or days, and usually disappears completely as a result of the use of antiperiodics.

Quinine Amblyopia or Amaurosis occurs after large quantities of quinine have been taken, occasionally with moderate doses in susceptible individuals. Besides other symptoms of cinchonism there are more or less complete *blindness*, often noticed suddenly, *contracted fields*, dilated pupils, and marked *pallor of the disc*, with extreme *contraction* of the *retinal vessels*. The condition is due to *spasm* of the retinal vessels causing *anæmia* of the fundus, degeneration of the ganglion cells and nerve fibres of the retina, and later *atrophy* of the optic nerve. After a time, central vision is restored completely or partially, and the field widens, but rarely regains its full extent. Treatment consists in discontinuing the drug, inhalations of amyl nitrite, the use of nitroglycerin, strychnine, digitalis, and the bromides.

Methyl-Alcohol Amblyopia or Amaurosis results from the drinking of variable quantities of wood-alcohol in the form of cheap whiskeys, cordials, essences, and other alcoholic beverages, which are often adulterated with Columbian

spirits, the trade name for rectified methyl-alcohol; it has also been caused by inhaling the fumes to which the varnishers of the interior of beer casks, for instance, are exposed. The general symptoms consist of *severe gastro-intestinal disturbance,* headache, vertigo and sometimes coma, and not infrequently terminate fatally. The ocular symptoms are *marked reduction of vision,* peripheral contraction of the *field,* and absolute central *scotoma; blindness* often follows. The ophthalmoscopic appearances are hyperæmia of disc with blurring of edges and, later, atrophy of the optic nerve with small retinal vessels. The prognosis is *unfavorable* both to life and to sight; some cases recover, but very few with useful vision. The anatomical changes are alterations in the ganglion cells of the retina with extension to the optic nerve. Treatment consists in the use of pilocarpine, nitroglycerin, potassium iodide, and later strychnine.

Night Blindness (*Nyctalopia,* sometimes incorrectly called hemeralopia) is a condition in which the *sight is good by day* or with good illumination, but *deficient at night* or with reduced illumination It is a symptom of certain forms of secondary atrophy of the optic nerve, especially retinitis pigmentosa.

A second form of diminished light sense occurs *without ophthalmoscopic changes* and is due to anæsthesia of the retina, probably from defective regeneration of the visual purple; this variety depends upon *diminished ocular nutrition* as a result of a *debilitated* state of the system, such as exists in starvation, profound anæmia, scurvy, and the like; sometimes there is the history of exposure to bright light; xerosis of the conjunctiva is often present at the same time. The condition is observed chiefly in the tropics, among the inmates of prisons, workhouses, and asylums; it is endemic in some countries, Russia for example, after the Lenten fasts; it is found most frequently in adult males, especially in the spring of the year. The prognosis is favorable, though there is some tendency to recur, and the defect usually disappears with improvement of the general health by good and sufficient food, tonics (cod-liver oil, iron), and the use of dark glasses.

Day Blindness (*Hemeralopia*, sometimes incorrectly called nyctalopia) is the name given to a condition in which the *sight is better at dusk* or in feeble illumination than in bright light. This symptom is found in toxic amblyopia and with central scotoma in general. In cases in which there are central opacities of the lens or cornea, the patient sees better in reduced illumination because the dilated pupil permits vision through the peripheral clear portion of the cornea and lens.

HEMIANOPSIA

Connection between the Retinæ, the Fibres of the Optic Nerves and Tracts, and the Cerebral Cortex (Figs. 170 and 249; also Plate XXII).—Familiarity with the course of the optic-nerve fibres from the eye to the cortex is of great practical value in the localization of various lesions causing defects in the field of vision.

The *optic nerves* terminate at the *chiasm*, which lies in the optic groove on the body of the sphenoid bone, in front of the infundibulum and above the hypophysis; here they *semi-decussate;* from the chiasm they are continued backward as the optic tracts which wind around the crura cerebri to the *primary optic ganglia* –the external geniculate body, the anterior corpus quadrigeminum, and the pulvinar of the thalamus opticus (*POG*, Figs. 170 and 249). Here the fibres divide into two portions: (1) a smaller part passing to the *nuclei of the oculomotorius* and presiding over the reflex action of the pupils and the movement of the ocular muscles, and (2) a larger bundle, composed of visual fibres, transfers its impulses (Fig. 170) to other fibres which carry the *visual impressions* to the cortex; the latter fibres pass through the posterior portion of the internal capsule, then form the *optic radiations* or fibres of Gratiolet, and end in the cortical ganglion cells of the mesial surface of the cuneus and the parts surrounding the *calcarine fissure;* this portion of the occipital lobe is known as the *visual area of the cortex* (*O*, Fig. 249).

In the ganglion cells of the visual area, an excitation in the optic-nerve fibres is changed into a sensory perception (sight) or into permanent changes (memories, optical-memory pictures). After destruction of this area, excitation of the optic-nerve fibres either fails to arouse visual sensation of any kind (*blindness*) or fails to summon forth any recollection of objects or circumstances acquired through previous education; in the latter case, objects are seen but not recognized (*psychical blindness*).

Each retina is supplied by optic-nerve fibres passing to *both sides of the brain*. Each *optic nerve* is composed of an *external* set of fibres derived from the outer or temporal half of the retina, and an *internal* set derived from the inner or nasal half of the retina. In the axis of the optic nerve is found a special set of fibres which pass to the *macula* and

the space between it and the disc. These macular fibres, when they reach the eyeball, are collected into a sector corresponding to the outer third of the disc, the apex directed toward the centre and the base toward the margin of the papilla. The *external* or temporal fibres are continued along the lateral part of the chiasm and tract and pass to the primary optic centre of the *same side*. The *inner* fibres, derived from the nasal half of the retina, pass into the chiasm and *decussate;* they are continued in the tract of the *opposite side*, thus passing to the side of the brain opposite to the eye which they supply.

The *chiasm* presents laterally the direct or temporal fibres of both eyes, and in its centre, the decussation of the inner or nasal fibres of both retinæ. Consequently, the decussation in the chiasm is not complete but partial—a semi-decussation.

Each optic tract contains fibres from both eyes. The right optic tract consists of non-decussating fibres from the right (temporal) half of the retina of the right eye, and decussating fibres from the right (nasal) half of the left eye. Hence the *right halves of both retinæ* and thus the *left halves of both visual fields* are connected with the *right tract* (Plate XXII). It follows, therefore, that the visual impulse excited by objects placed to the left of the median line passes to the cortex of the right hemisphere by means of the right optic tract; and that the perception of all objects placed to the right of the median line is conveyed by the left optic tract to the cortex of the left hemisphere.

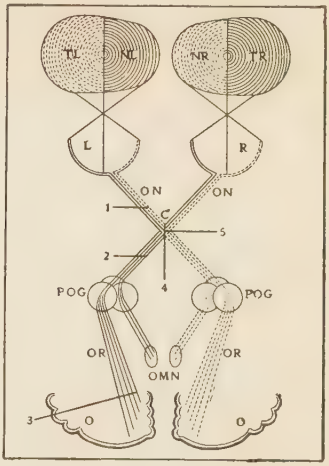

FIG. 249.—Schematic Representation of the Visual Paths. *L*, left eye; *R*, right eye; *TL*, temporal field of left eye; *NL*, nasal field of left eye; *NR*, nasal field of right eye; *TR*, temporal field of right eye; *ON*, optic nerve; *C*, chiasm; *POG*, primary optic ganglia; *OMN*, oculomotor nuclei; *O*, occipital lobe; *OR*, optic radiations. Division of fibres at 1 causes complete blindness of the left eye and loss of direct pupillary reaction; at 2, right homonymous hemianopsia with loss of reaction of the pupil when the left halves of the retinæ are illuminated; at 3, right homonymous hemianopsia with preservation of the reaction of the pupil when the left (and right) halves of the retinæ are illuminated, at 4, bitemporal hemianopsia; at 5, left nasal hemianopsia.

Hemianopsia.—This arrangement of fibres in the chiasm explains the occurrence of a form of visual disturbance known

as hemianopsia (*hemianopia, hemiopia*), by which we mean the loss of vision for *corresponding halves or sectors of the visual fields.* If a lesion interrupts the continuity of the right optic tract, the right cortical visual area, or any portion of the visual path between these parts, there will be blindness of the right halves of both retinæ; as a result, the left halves of the fields of vision of both eyes will be lost, and only objects which are placed to the right of the median line will be perceived. This is known as *homonymous* or lateral *hemianopsia,* and in this particular case the condition is called left homonymous hemiopia, because the left halves of the fields of vision are wanting. Homonymous hemianopsia (Fig. 251), therefore, always points to a lesion situated in the visual path or cortex on the *central side of the chiasm* and upon the *same side as the blind halves of the retinæ.* It is the commonest form of hemianopsia.

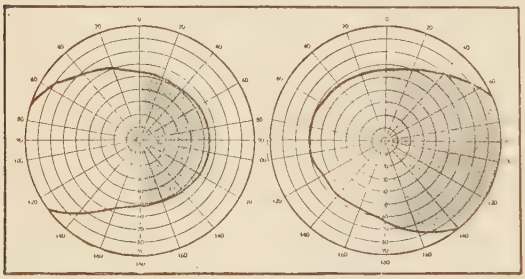

Fig. 251.—The Fields of Vision in Right Homonymous Hemianopsia.

If a lesion extends antero-posteriorly through the chiasm it will destroy all the decussating fibres which supply the inner or nasal halves of both retinæ, and there will be a loss of vision in the outer or temporal halves of the field of both eyes, a condition called *bitemporal hemianopsia* (4, Fig. 249). It is often seen in pituitary body disease.

If a lesion attacks each side of the chiasm, it will destroy the non-decussating fibres which come from the temporal halves of the retinæ, and will, therefore, cause a loss of the nasal or inner half of the field of vision of each eye; this is known as *binasal hemianopsia.* Bitemporal and binasal hemianopsia are known as *crossed hemianopsia.* It is doubtful whether binasal hemianopsia ever occurs; another rare

PLATE XXII

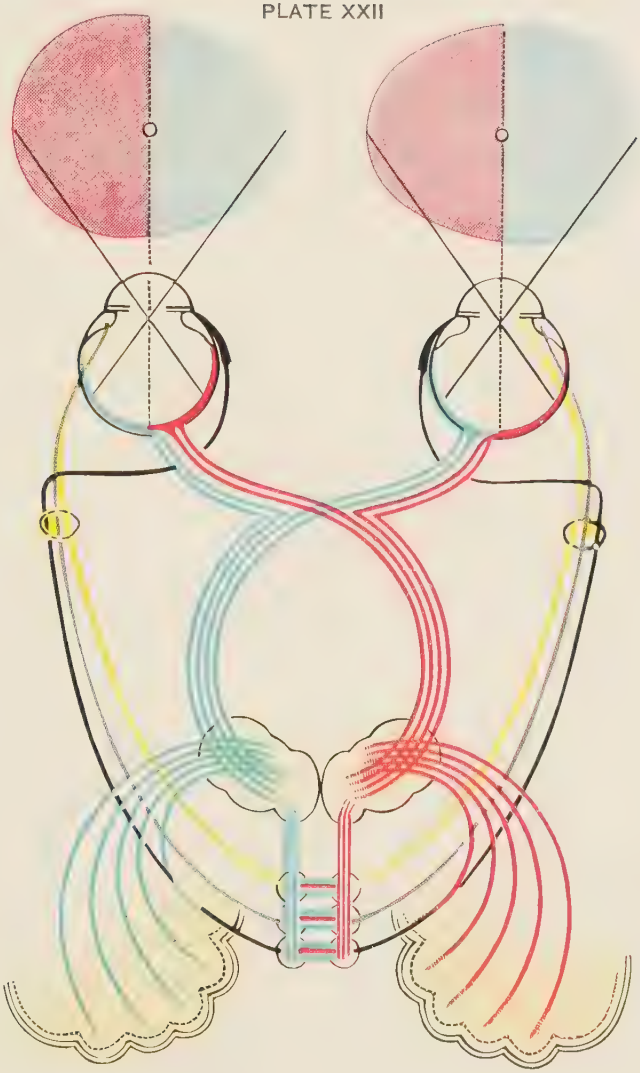

FIG. 250.—Schematic Representation of the Visual and the Pupillary Paths.

form of hemianopsia is altitudinal (inferior or superior)—when the upper or the lower half of each field is wanting.

Hemianopsia is said to be *complete* when there is a symmetrical absence of the *entire half* of the field of vision. It is *incomplete* when there is an absence of a *small portion* or *sector* occupying a symmetrical position in the visual fields of the two eyes; the lesion then involves only a portion of the fibres of a visual tract or cortical visual area.

Even in cases of complete hemianopsia, the line between the absent and the preserved portion of the field seldom extends through the fixation point, the portion of the field corresponding to the *macula* being usually *preserved.* In the rare instances in which both halves of the fields are lost successively (double homonymous hemianopsia), there will be blindness except at the situation of these macular fibres, indicating that the macula is supplied by a special region in the cortical visual area.

Hemianopsia is known as *absolute* when there is loss of all three functions of sight (light, form, and color sense); and *relative* when only the color sense or both the color sense and form sense are destroyed over the symmetrically defective areas, the light sense and the form sense being preserved in the first instance, and the light sense only being present in the second case. When the hemianopic defect is present for colors alone, the condition is known as *hemiachromatopsia;* it is believed to point to a lesion of less intensity than that which causes absolute hemianopsia.

Complete blindness in one eye only is always due to a lesion situated *in front of the chiasm.* The same applies to *scotomata,* which are defects in the visual field of one eye (p. 17), or non-symmetrical defects in the fields of both eyes; when central, they indicate an involvement of the papillo-macular sector of the optic nerve.

The Hemiopic Pupillary Reaction (Wernicke) is of value in determining whether a lesion causing homonymous hemianopsia is situated *behind* or in *front* of the *primary optic ganglia.* Light is thrown into the eye obliquely so as to illuminate one or the other side of the retina. If the lesion is back of the

ganglia, the pupillary light reflex will be preserved whether the blind or the seeing half of the retina be lighted up; if in front of these ganglia (in the optic tract) the pupil will respond when light falls upon the seeing half of the retina, but there will be no contraction or only a feeble reaction when the blind half of the retina is illuminated (Fig. 170). This test is a difficult one.

Scintillating Scotoma (*Transient Hemianopsia*) is a form of temporary blindness generally associated with *migraine* and probably due to a circulatory disturbance in the occipital lobe. The attack begins with a central *dark spot* before both eyes, which spreads by *scintillating* and colored zigzag lines until there is a considerable *gap in the field*, often assuming the form of homonymous hemianopsia. Accompanying the attack there are *headache*, general malaise, vertigo, and sometimes nausea and vomiting. The attacks vary in frequency and last about fifteen minutes, after which the amblyopia disappears entirely. The affection occurs after excessive mental or physical exertion and following marked eye strain. Unless associated with paralysis, aphasia, or other symptoms of cerebral trouble, it is not of serious import. Treatment consists in attention to the general health, correction of eye strain, avoidance of fatigue of any kind, and the use of remedies suited to migraine.

CHAPTER XXI

GENERAL OPTICAL PRINCIPLES

From a luminous point, rays of light pass out in straight lines in every plane and in every direction; the lines of direction are called *rays*. These travel with a rapidity which diminishes with the density of the medium traversed. The amount of divergence of the rays of light falling on a given area is inversely proportionate to the distance of the luminous source; the nearer this point, the more divergence. When proceeding from a point distant *20 feet or more*, the divergence of rays is so slight that for practical purposes we assume them to be *parallel*.

When a ray of light meets an *opaque* body, it is either *absorbed* or *reflected*. When it meets a *transparent* medium, some of it is absorbed and reflected, but the greater part traverses the medium, being *deflected* in its course; this bending is called *refraction*.

Reflection occurs from any polished surface (mirror)—plane, concave, or convex. The ray striking the mirror is called the *incident ray* (*IB*, Fig. 252); that returning from the mirror, the *reflected ray* (*BR*, Fig. 252).



Fig. 252.—Reflection by a Plane Surface.

Laws of Reflection: (1) The angle of reflection is equal to the angle of incidence. (2) The reflected and incident rays are both in a plane perpendicular to the reflecting surface. In Fig. 252 *IB* is the incident ray on the reflecting surface *AC*, *BR* the reflected ray, and *PB* the perpendicular. The angle of incidence, *IBP*, is equal to the angle of reflection, *PBR*. *IB*, *PB*, and *BR* lie in the same plane.

Reflection by a Plane Mirror.—The image is formed at a distance behind the mirror equal to the distance of the object in front of it; it is a *virtual* image, *erect*, and of the *same size* as the object. In Fig. 253, *O* is the object, *I* the image, and *E* the eye of the observer. The image of the candle *O* is found behind the plane mirror *MM;* the observer's eye *E* receives the rays from *O* as if they came from *I*.

Reflection from a Concave Mirror.—A concave surface may be considered as made up of a number of plane surfaces inclined toward one another. *Parallel rays* falling on a concave mirror are *reflected* as *convergent* rays which meet on the axis of the surface at a point called

the *principal focus* (*Pf*, Fig. 254); the latter is midway between the mirror and its optical centre *C*. The distance of the principal focus from the mirror is called the *focal length* of the mirror.



FIG. 253.—Formation of Image by a Plane Mirror.

The Position of an Image formed by a concave mirror varies with the distance of the object from the mirror. If the object be placed at the principal focus, *Pf*, the reflected rays are parallel to each other and to the axis of the mirror. If the object be placed at the centre of concavity *C*, the reflected rays return along the same lines. If the object is beyond the centre, at *CF*, the reflected rays focus between the centre and the principal focus at *cf;* and conversely, if the object be moved between the principal focus and the centre, at *cf*, its focus will be beyond the centre, at *CF;* these two points, *CF* and *cf*, bear a reciprocal relation to each other and are known as *conjugate foci;* the nearer the object approaches the principal focus the greater the distance at which the reflected rays meet. If the object be placed nearer the mirror than the principal focus, at *X*, reflected rays will be divergent and never meet; if, however, these divergent rays are continued backward, they will unite at a point, *Vf*, behind the mirror; this point is called the *virtual focus*, and an observer placed in the path of the reflected rays will receive them as though they came from this point.

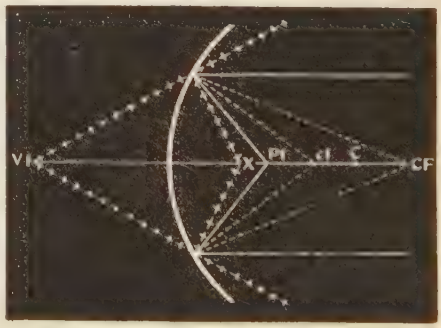

FIG. 254.—Reflection by a Concave Mirror.

It follows, therefore, that concave mirrors produce an enlarged, erect, and virtual image if the object is placed nearer than the principal focus; no image of an object placed at the principal focus; an enlarged, inverted, real image if the object is placed between the principal focus and the centre; an inverted image of the same size when placed at the centre; and a smaller, inverted, real image if the object is placed beyond the centre.

Reflection by a Convex Mirror.—Parallel rays falling on a convex surface are reflected *divergent* and hence never meet; but if prolonged backward a *negative image* is formed at a point called the

principal focus (Fig. 255, *F*). The image is always *virtual*, *erect*, and *smaller* than the object, independent of the position of the object before the mirror.

Refraction is the *deviation* in the course of rays of light in passing from one transparent (dioptric) medium into another of different density (refracting medium). The ray which falls *perpendicular* to the surface separating the two media is *not refracted* but continues in a straight course (Fig. 256,*PP*).



FIG. 255.—Reflection by a Convex Mirror.

In passing from a *rarer to a denser* medium, a ray is refracted *toward the perpendicular* to the refracting surface; in passing from a *denser to a rarer* medium, the ray is refracted *away from the perpendicular*. In Fig. 257, the incident ray *IR*, in passing from a rarer medium (air) into a denser medium (glass), is refracted toward the perpendicular *PP;* in passing from a denser to a rarer medium, the emergent ray *ER* is refracted from the perpendicular *PP*. The ray continues in a line parallel to its original course, but has suffered lateral deviation. The angle formed by the incident ray with the perpendicular, *IRP*, is known as the *angle of incidence;* the angle formed by the emergent or refracted ray with the perpendicular, *PER*, is known as the *angle of refraction.*

FIG. 256.



FIG. 257.

FIG. 256.—Passage of a Perpendicular Ray Through a Transparent Medium.
FIG. 257.—Refraction by a Transparent Medium with Parallel Surfaces.

Index of Refraction.—The *relative density*, or the comparative length of time occupied by light in travelling a definite distance in different transparent media, is known as the index of refraction. Air being taken as 1.00, the index of refraction of water is 1.33, of the cornea 1.33, of the lens 1.40, of crown glass 1.5, of flint glass 1.6, and of diamond 2.50.

PRISMS

A prism is a piece of glass or other refracting substance bounded by *plane surfaces inclined toward each other* (Fig. 258). The angle formed by the two surfaces is called the *refracting angle* of the prism (*BAC*), the thin edge where the intersecting surfaces meet is known as the *apex* (*A*), and the opposite thick portion as the *base* (*BC*).

Refraction by a Prism.—Rays of light passing through a prism are *bent toward the base.* In Fig. 258, the incident ray



FIG. 258.—Refraction by a Prism.



FIG. 259.—Passage of Parallel Rays Through a Prism

IR is refracted toward the perpendicular *PR*, at *R*, and assumes the direction *RR* in the prism; on emerging, it is refracted away from the perpendicular and continues as *RE* toward the base of the prism. To the eye placed at *E*, the ray *RE* seems to come from *X;* hence *an object seen through a prism appears displaced toward the apex.* A prism has neither converging nor diverging power, and therefore has no focus and cannot form an image; rays that are parallel before entering the prism are parallel on emerging (Fig. 259).

The Numbering of Prisms.—The strength of a prism is expressed (1) in degrees, (2) in centrads, and (3) in prism-diopters. In the first method (*degrees*), which in spite of certain faults is the one most generally used, the value of the prism corresponds to the *refracting angle* (geometrical angle) and is expressed: Prism 1°, 2°, 10°, etc. A *centrad* corresponds to a deviation, the arc of which is $\frac{1}{100}$ of the radius, and is expressed $1\triangledown$, $2\triangledown$, $10\triangledown$, etc. The *prism diopter* is a deviation, the tangent of which is $\frac{1}{100}$ of the radius, and is expressed: 1 P. D. or $1\triangle$, 2 P. D. or $2\triangle$, etc. Within the limits of common use, the three scales can practically be considered alike.

The Position of a Prism when placed in front of an eye is indicated by the *direction of its base;* " base out " means that the thick part of the prism is toward the temple; the base may be up, down, in, or out.

The Uses of Prisms: (1) To counteract the effects of muscular paralysis or insufficiency; (2) for the exercise of weak muscles; (3) to test the extent to which the eyes can be de-

viated from parallelism; (4) as a test for heterophoria; (5) for detecting simulated blindness.

LENSES

A lens is a transparent *refracting medium*, usually made of glass, in which one or both surfaces are *curved*. There are two kinds: *spherical* and *cylindrical* lenses.

FIG. 260.—The Relation of the Surfaces of Lenses to Spheres. 1. Plano-convex; 2, biconvex; 3, convex meniscus; 4, plano-concave; 5, biconcave; 6, concave meniscus.

Spherical Lenses are so called because the curved surfaces are segments of spheres (Fig. 260); such lenses refract rays of light equally in *all meridians* or planes. There are two kinds of spherical lenses, *convex* and *concave*.

Convex Spherical Lenses are formed of *prisms* with their *bases together* and toward the centre (Fig. 261, *A*); they are therefore *thick at the centre* and thin at the edge. They are known as *converging*, magnifying, positive, and *plus* lenses, and denoted by the sign +. They have the power of *converging* parallel rays and of bringing them to a *focus* (Fig. 264). There are three different forms: (1)

FIG. 261.—The Formation of Lenses by Prisms.

FIG. 262.—Convex Lenses. 1. Plano-convex; 2, biconvex; 3, convex meniscus.

FIG. 263.—Concave Lenses. 1. Plano-concave; 2, biconcave; 3, concave meniscus.

Plano-convex, one surface plane, the other convex (1, Fig. 262); (2) *biconvex* or double convex, both surfaces convex (2, Fig. 262); (3) *concavo-convex* (*convex periscopic*, convex or converging *meniscus*), one surface convex, the other

concave—the former having the shorter radius of curvature (3, Fig. 262). The *periscopic* lens (whether + or −) diminishes spherical aberration and enlarges the field of vision.

Concave Spherical Lenses are formed of *prisms* with their *apices together* and toward the centre (Fig. 261, *B*); they are therefore *thin at the centre* and thick at the edge. They are known as *diverging*, reducing, negative, or *minus* lenses, and

FIG. 264.—The Action of a Convex Lens on Parallel Rays.



FIG. 265.—The Action of a Concave Lens on Parallel Rays.

denoted by the sign −. Rays of light after passing through a concave lens are rendered *divergent;* if prolonged backward they form an image on the same side as the object (Fig. 265). There are three different forms: (1) *Plano-concave*, one surface plane, the other concave (1, Fig. 263); (2) *biconcave* or double concave, both surfaces concave (2, Fig. 263); (3) *convexo-concave* (*concave periscopic*, concave or diverging *meniscus*), one surface convex and the other concave, the latter having the shorter radius of curvature (3, Fig. 263).

The Action of Spherical Lenses.—Since spherical lenses are formed of prisms with their bases (convex) or apices (concave) in apposition, and since rays in passing through a prism are refracted toward its base, it follows that *convex lenses cause convergence* (Fig. 264), and *concave lenses produce divergence* of rays (Fig. 265).



FIG. 266.— Principal and Secondary Axes of a Convex Lens.

A line passing through the centre of the lens (optical centre or nodal point, *O*, Fig. 266) at right angles to the surfaces of the lens is called the *principal axis* (*A B*, Fig. 266). A ray passing through this axis (*axial ray*) is *not refracted;* all other rays

suffer more or less refraction. Rays passing through the optical centre of a lens, but not through the principal axis (*secondary rays*) are slightly deviated, but emerge in the same direction as they entered (*CD* and *EF*, Fig. 266); the deviation in thin lenses is so slight that practically they may be considered as straight lines and are called *secondary axes*.

Foci of a Convex Lens.—The point to which rays converge after refraction by a convex lens is called its *focus*. The *principal focus* is the *focus for parallel rays* (*F*, Fig. 267); the distance of this point from the optical centre is called the *focal distance* of the lens (*XF*, Fig. 267). Since the course of a ray passing from one point to another is the same, independent of the direction, it follows that rays from a luminous point placed at the principal focus will emerge as parallel after passing through the lens.



FIG. 267.—The Principal Focus of a Convex Lens.

In Fig. 267, the rays *ABC* strike the surface of the lens at *LMN;* the axial ray *B* strikes the lens at *M* perpendicular to its surface and consequently continues in a straight line to *F*. The ray *A* strikes the lens obliquely at *L* and is bent toward the perpendicular of the surface of the lens at that point, shown by the dotted line *PR;* on leaving the lens obliquely at *S* it is deflected away from the perpendicular *RT*, being directed to *F* where it meets the axial ray *BF*. The ray *C* is refracted in a similar manner; it is bent upon entering the lens at *N* and rendered additionally convergent when emerging from the lens, and finally it meets the other rays at *F*. If, in this same illustration, the rays proceed from *F*, the principal focus, they emerge parallel (*LA*, *MB*, *NC*) after passing through the lens.

Conjugate Foci of a Convex Lens.—Conjugate foci are *interchangeable foci* in which the image can be replaced by the object and the object by the image. When divergent rays (*i.e.*, rays coming from a point nearer than twenty feet) proceed from a point beyond the principal focus, they will meet at a point beyond the principal focus on the other side of the lens. The more distant the luminous point, the nearer the principal focus (on the other side of the lens) will the rays be focussed. If the luminous point is situated at a distance equal to twice the focal length of the lens, the rays will focus at the same distance on the opposite side. These are conjugate foci.

In Fig. 268, the rays diverging from *O* and passing through the lens converge at *I;* if they diverge from *I*, they would return in the same path, and meet at *O;* the points *O* and *I* are conjugate foci. In the preceding example the conjugate focus is *positive* or *real.*



FIG. 268.—Conjugate Foci of a Convex Lens.

Virtual or Negative Focus of a Convex Lens. — When rays diverge from some point between the lens and its principal focus (Fig. 269, *O*), they will continue divergent after refraction, but less so than before entering the lens; if prolonged backward they will meet at a point (*I*, Fig. 269) on the same side of the lens from which they diverged; this point is a *negative* or *virtual focus.*

Foci of a Concave Lens.—After passing through a concave lens, rays of light, whether originally parallel or divergent, are always *divergent* and the *focus* is, therefore, always *negative* or *virtual;* it is found by continuing these divergent rays backward until they meet at a point (Fig. 265).



FIG. 269.—Virtual Focus of a Convex Lens.

Formation of Images.—The *image* of an object formed by a lens is a *collection of foci,* each corresponding to a point in the object. Such images are either *real* or *virtual.* A *real image* is formed by the *meeting of rays;* it can be projected on a screen. A *virtual image* is formed by the *prolongation backward of diverging rays* until they meet at a point; it can only be seen by looking through the lens.



FIG. 270.—Real, Inverted, and Reduced Image Formed by a Convex Lens.

To find the Position and Size of an Image formed by a lens, it is necessary to obtain the conjugate focus of each extremity of the object: Two lines are drawn from each of these points, one parallel to the axis of the lens and then through the principal focus, and the other through the optical centre; the im-

age will be formed at the point where these rays intersect (Figs. 270, 271, 272).

In Fig. 270, *AB* is the object, *O* is the optical centre of the lens, and *PF* its principal focus. From *A*, two rays are drawn, one parallel to the axis of the lens and then through the principal focus *PF*, and a secondary ray through *O;* the image of the point *A* is formed at *a*, where these two lines intersect. The conjugate focus of *B* is found in the same manner.



FIG. 271.—Real, Inverted, and Enlarged Image Formed by a Convex Lens.

The Relation in Size between Image and Object depends upon their respective distances from the optical centre of the lens. In Fig. 270, the object is placed at a greater distance than twice the principal focus, hence the image is real, inverted, and smaller. If the object is situated

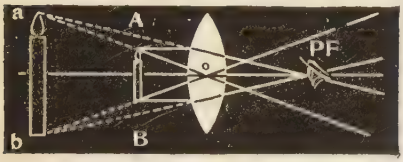

FIG. 272.—Virtual Image Formed by a Convex Lens.



FIG. 273.—Virtual Image Formed by a Concave Lens.

at exactly twice the distance of the principal focus, the image will be real, of the same size, and inverted. If the object is situated just beyond the principal focus, the image will be real, enlarged, and inverted (Fig. 271). If the object be placed at the principal focus, the rays will be parallel after refraction and no image will be obtained. If the object be nearer than the principal focus, the rays will be divergent after passing through the lens (Fig. 272), and no real image will be formed; but by projecting these rays backward they would meet, and an eye placed at *PF*, Fig. 272, will receive the rays from *AB* as if they came from *ab;* the image will be enlarged, erect, and virtual; it is on the same side of the lens as the object, and is seen only by looking through the lens, which acts as a *magnifying glass*.

Images formed by Concave Lenses are always virtual, erect, and smaller than the object; they are seen only by looking through the lens, which acts as a *reducing glass* (Fig. 273).

Cylindrical Lenses.—A cylindrical lens or *cylinder* is a *seg-*

ment of a cylinder parallel to its axis (Fig. 274). Cylinders are divided into *convex* and *concave*. Light passing through a cylinder *in the plane of its axis is not refracted* and behaves exactly as though passing through a plate of glass with parallel sides; in this direction, the surface of the lens is straight. But when light passes through in a *plane opposite* or perpendicular *to the axis* of a cylinder, the rays are rendered *convergent* or *divergent*, according as the cylinder is convex or concave; in this direction the surface of the lens is curved. Parallel rays of light after refraction by a cylinder are focussed in a straight line which corresponds to the axis of the cylinder (Figs. 275, 276). A spherical lens refracts equally in all planes; a cylindrical lens does not refract in the axial plane, but all other rays are refracted, those the most which pass at right angles to its axis. It is necessary to *indicate the direction of the axis of a cylinder;* in the lenses of the trial case, used for the estimation of the refraction of the eye, this is done by a short linear scratch on the lens at its margins or by having a portion of the surface on each side ground parallel to its axis (Fig. 278).



FIG. 274.—The Construction of a Convex and a Concave Cylindrical Lens from a Cylinder.



FIG. 275.—The Action of a Convex Cylindrical Lens upon Parallel Rays.



FIG. 276.—The Action of a Concave Cylindrical Lens upon Parallel Rays.

The Numeration of Lenses. —The *strength* of a lens refers to its power of bringing parallel rays to a focus—*i.e.*, its *refrac-*

tive power; this is indicated by its *principal focal distance,* the interval between the optical centre of the lens and the principal focus. The shorter this distance, the stronger the lens; the greater the principal focal distance, the weaker the lens. *The strength of a lens is the inverse of its focal distance.*

There are *two systems of numbering lenses:* (1) The Inch, and (2) the Metric or Dioptric.

In the Inch System, the *unit* is a strong lens which brings parallel rays to a focus at one inch; this is known as $\frac{1}{1}$ or 1, and every other lens is a *fraction* of this unit, in which the *focal distance* in inches forms the *denominator.* For instance, $\frac{1}{4}$ has a focal distance of 4 inches, $\frac{1}{10}$ of 10 inches, $\frac{1}{40}$ of 40 inches. Such lenses are also expressed by the terms No. 4, No. 10, No. 40, indicating their focal strength. This system, though very simple, is open to the objections (1) that the inch varies in length in different countries, (2) the lack of uniform intervals, and (3) the inconvenience of adding or subtracting vulgar fractions in practical work.

The Metric or Dioptric System accepts as its *unit* a lens which has its principal focus at *one meter* distance ($39\frac{1}{3}$ Eng-

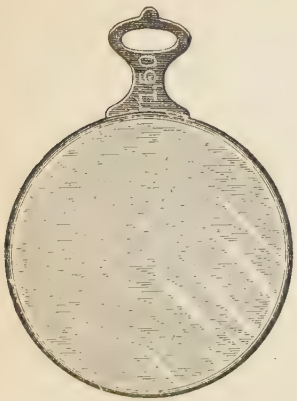

FIG. 277.—Spherical Lens from Trial Case.

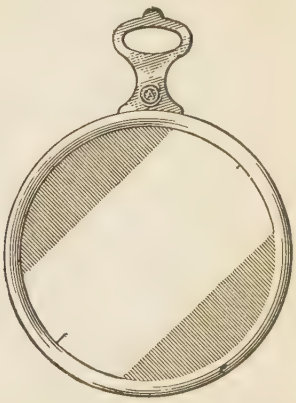

FIG. 278.—Cylindrical Lens from Trial Case.

lish inches, in round numbers 40 inches); this lens is known as 1.00 *diopter* (abbreviated D.). Every lens is numbered by its strength in *whole numbers* and in *decimal fractions* (0.25,

0.50, 0.75). A lens which has twice the strength of the unit is known as 2 D.; its focal distance is one-half of a meter. If the lens has a strength four times that of the unit, it is called 4 D., and its focal distance is one-quarter of a meter. If ten times as strong as the unit, it is known as 10 D., and its focal distance is one-tenth of a meter. If one-quarter, one-half, or three-quarters as strong as the unit, it is known as 0.25 D., 0.50 D., or 0.75 D. respectively. In this system the number of the lens does not express its focal distance; but the focal distance in centimeters is obtained by dividing 100 cm. by the number of the lens; for example a 2 D. lens has a focal distance of $\frac{100}{2} = 50$ cm.; a 5 D. lens has a focal distance of $\frac{100}{5} = 20$ cm. *The dioptric system is the one now universally adopted.*

To convert the focal distance in inches into the focal distance in diopters, or vice versa, divide the number 40 by the number of inches or diopters expressed. For example, 8 D. $= \frac{40}{8} = 5$ inches $= \frac{1}{5}$; 0.50 D. $= \frac{40}{0.5} = 80$ inches $= \frac{1}{80}$; $\frac{1}{20}$ (twenty inches) $= \frac{40}{20} = 2$ D.; $\frac{1}{10}$ (ten inches) $= \frac{40}{10} = 4$ D. The following table gives the commonly employed (approximate) *equivalents* in the inch and the dioptric systems:

COMMONLY EMPLOYED (APPROXIMATE) EQUIVALENTS OF LENSES NUMBERED IN THE DIOPTRIC AND INCH SYSTEMS

Diopters	Inches	Diopters	Inches	Diopters	Inches	Diopters	Inches
0.25	160	2.25	18	5.50	7.0	13	3.0
0.50	80	2.50	16	6.00	6.5	14	2.8
0.75	50	2.75	14	7.00	5.25	15	2.6
1.00	40	3.00	13	8.00	5.0	16	2.4
1.25	32	3.50	11	9.00	4.5	..	...
1.50	26	4.00	10	10.00	4.0	18	2.2
1.75	22	4.50	9	11.00	3.5	..	...
2.00	20	5.00	8	12.00	3.3	20	2.0

The Trial Case (Fig. 279) is a box containing + and − spherical, and + and − cylindrical lenses, arranged in pairs. The spherical lenses usually correspond to those given in the

preceding table (30 pairs), the weaker ones separated by intervals of 0.25 D. (sometimes 0.12 D.), those of moderate strength by 0.50 D., and the stronger ones by 1 D. The cylindrical lenses usually run from 0.25 D. to 6.00 D. The + lenses are mounted in nickelled rims, the − lenses in brass



FIG. 279.—The Trial Case of Lenses.

rims. Besides these lenses, a complete trial case contains a set of prisms, various metal discs one of which (obturator) is solid and is used to exclude one eye in the examination, and a trial spectacle frame (Fig. 289).

Recognition of the Kind of Lens and Estimation of its Strength.—By moving a *spherical lens* before the eye and looking at an object, the latter will appear to move, rapidly if the lens is a strong one, slowly if a weak one. If the object seems to move in the *opposite* direction and appears *enlarged*, the lens is *convex*. If the object appears to move in the *same* direction and seems *smaller*, the lens is *concave*.

When a *cylinder* is moved before the eye in the direction of its axis, an object looked at does not appear to change its position; when moved in the opposite direction, objects appear to move as with spherical lenses—in the opposite direction when the cylinder is convex, in the same direction when concave.

Having recognized the character of the lens, the *strength* can be determined by *neutralizing*. Lenses of opposite kind and known strength are taken from the trial case and placed in front of the one to be tested, and the two lenses moved in front of the eye. The neutralizing lens is the one which *stops all apparent movement* of an object looked at, when the com-

bined lenses are moved in front of the eye. The Lens Measure (Fig. 280) furnishes a very quick and reliable method of determining the character and strength of any lens.

Finding the Centre of the Lens.—Unless especially desired (for prismatic effect) the optical centre of the lens should coincide with the geometric centre. To find the optical centre we look at two lines at right angles to each other through the lens held a few inches above. The portion of the vertical and of the horizontal line seen through the lens is made continuous with the portion seen beyond the lens; then the two lines should cross at the geometrical centre of the lens.



FIG. 280.—Lens Measure.

Varieties of Lenses Used to Correct Errors of Refraction: 1. Simple spherical lens, convex or concave. 2. Simple cylindrical lens, convex or concave. 3. Sphero-cylinder, a combination of a spherical with a cylindrical lens. 4. Cross-cylinder, a combination of two cylindrical lenses with their axes at right angles to each other (infrequently used). 5. Simple prism. 6. Prism combined with various lenses.

Abbreviations and Signs Used in Ophthalmology

A. or Acc.....Accommodation.
Am.....Ametropia.
As.....Astigmatism, astigmatic.
As. H.....Hyperopic astigmatism.
As. M.....Myopic astigmatism.
Ax.....Axis (of cylindrical lens).
B.....Base (of prism).
C. or Cyl.....Cylindrical lens or cylinder.
cm.....Centimeter.
D.....Diopter
E.....Emmetropia or emmetropic.
F.....Field of vision.
H.....Hyperopia, hyperopic, horizontal.
Hl.....Hyperopia latent.
Hm.....Hyperopia manifest.
Ht.....Hyperopia total.
L. or L. E.....Left eye.

M.....Myopia or myopic.
m.....Meter.
M. A.....Meter angle.
mm.....Millimeter.
n.....Nasal.
O. D. (R., or R. E).....Oculus dexter (right eye).
O. S. (L., or L. E.).....Oculus sinister (left eye).
O. U.....Oculus uterque (both eyes).
Oph.....Ophthalmoscope or ophthalmoscopic.
P. D.....Prism diopter.
P. L.....Perception of light.
P. p.....Punctum proximum (near point).
P. r.....Punctum remotum (far point).
Pr.....Presbyopia.
R. or R. E.....Right eye.
S. or Sph.....Spherical lens.
t.....Temporal.
T.....Tension.
V.....Vision, visual acuteness, vertical.
w.....With
+.....Plus or convex.
−.....Minus or concave.
=.....Equal to.
⌔.....Combined with.
∞.....Infinity (20 feet or more distance).
′.....Foot, minute.
″.....Inch, second.
‴.....Line.
°.....Degree (prism).
∇.....Centrad (prism).
Δ.....Prism diopter.

CHAPTER XXII

OPTICAL CONSIDERATION OF THE EYE

The eye may be considered as an optical instrument, often compared to the photographic camera, in which by means of a refracting (dioptric) system a *small and inverted image* of external objects is formed *on the retina;* it is well adapted for its function of refraction; the outermost portion of the retina consists of a layer of pigment cells which absorbs the excess of light and prevents dazzling. The impression received by the rods and cones is conveyed through the optic nerve to the cortical area where the visual act is completed and results in the sense of sight.

Dioptric Apparatus of the Eye.—In passing through the eyeball rays of light traverse the cornea, aqueous, lens, and vitreous. The *refracting surfaces* of the eye are the cornea, the anterior surface and the posterior surface of the lens; the *refracting media* are the aqueous, the substance of the lens, and the vitreous. These surfaces and media constitute the *dioptric or refractive apparatus of the eye*, a system which is represented by a convex lens of 23 mm. focus; hence in an emmetropic eye, in a condition of rest, parallel rays are brought to a focus on the retina. The greatest deflection of rays takes place at the anterior surface of the cornea; additional deviations occur at the anterior and posterior surfaces of the lens. In each case the effect is one of *convergence*. By the term *refraction of the eye*, we mean the changes which the ocular media exert upon rays of light when the eye is in a *state of rest*.

Cardinal Points of the Eye.—It is necessary to know the cardinal points of the eye (Fig. 281) in order to understand the course of rays of light through this organ; they are the two principal points, the two nodal points, and the two principal foci, all situated on the optical axis.

The Principal Points (*P*, Fig. 281) are two points so related that when an incident ray passes through the first principal point, the corresponding emergent ray passes through the second principal point. These two points are placed so close together in the anterior chamber that they may be considered as one point, situated about 2 mm. behind the cornea.

The Nodal Points (*N*, Fig. 281) correspond practically to the optical centre of the dioptric system; they are so close together that they may be considered as one point situated near the posterior pole of the lens about 7 mm. behind the cornea. Rays passing through this point are not refracted and form either the axial or secondary rays.

The First Principal Focus (*A*, Fig. 281) is that point on the axis at which parallel rays in the vitreous meet; it is situated about 14 mm. in front of the cornea.

The Second Principal Focus (*F*, Fig. 281) is that point on the axis at which parallel rays meet after being refracted by the dioptric system of the eye; it is situated to the inner side of the macula, between it and the optic disc, about 23 mm. behind the cornea.

The Centre of Rotation of the eyeball (*R*, Fig. 281) is situated in the vitreous, about 10 mm. in front of the retina.

The Optical Axis (*A F*, Fig. 281) is the line connecting the centre of the cornea, the nodal point, and the posterior principal focus.

The Visual Line (*O M*, Fig. 281) is the line passing from the object looked at, through the nodal point, to the macula.

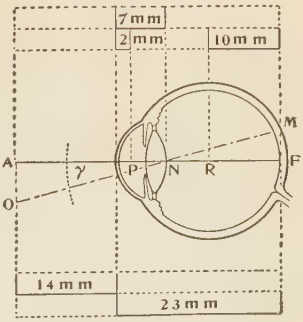

FIG. 281.—Cardinal Points of the Eye.

The Line of Fixation is the line joining the object looked at with the centre of rotation; practically it corresponds to the visual line.

The Angle Gamma (γ, Fig. 281) is the angle formed by the optical axis with the line of fixation (practically with the visual line); it varies with the refraction of the eye, being about 5° in emmetropia, larger in hyperopia, and smaller in myopia.

The Angle Alpha is the angle formed by the visual line with the major axis of the corneal ellipse.

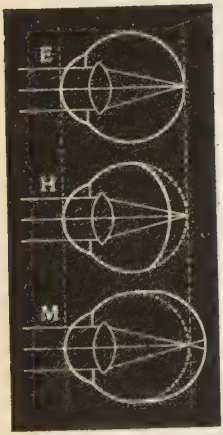

FIG. 282.—Emmetropia.
FIG. 283.—Hyperopia.
FIG. 284.—Myopia.

REFRACTION OF THE EYE

Emmetropia.—When parallel rays are focussed exactly on the retina with the eye in a condition of rest, the refraction of the eye is normal or *emmetropic* (Fig. 282) and the condition is known as emmetropia.

Ametropia.—When, with the eye in a condition of rest, parallel rays are *not focussed on the retina*, but behind or in front of it, the eye is *ametropic*, and the condition is known as ametropia. The forms of ametropia (*errors of refraction*) are hyperopia, myopia, and astigmatism.

Hyperopia is that form of ametropia in which the axis of the eyeball is too short or the refractive power of the eye too weak, so that *parallel rays* are brought to a *focus behind the retina* (Fig. 283).

Myopia is that form of ametropia in which the axis of the eyeball is too long or the refractive power too strong, so that *parallel rays* are *focussed in front of the retina* (Fig. 284).

Astigmatism is that form of ametropia in which the *refraction of the several meridians* of the eyeball is *different* (Figs. 310–314).

ACCOMMODATION

Accommodation is the *power of altering the focus of the eye* so that divergent rays (those coming from an object nearer than 20 feet) are brought together on the retina; this is accomplished by means of an *increase in the convexity of the lens* and thus in its refractive power. The degree of accommoda-



FIG. 285.—The Emmetropic Eye in a State of Rest.



FIG. 286.—The Emmetropic Eye During Accommodation.

tion must *vary for every distance* of the object; the eye cannot be adapted for two different distances at the same time.

In the emmetropic eye *at rest*, *parallel* rays are brought to a focus on the *retina* (*P F*, Fig. 285), but rays coming from a near object (*divergent* rays) are focussed *behind* the retina (*D X*, Fig. 285); hence distant objects appear distinct and near objects blurred. If the refractive power of the eye is increased by *accommodation*, *parallel* rays will be brought to a focus in *front* of the *retina* (*P F*, Fig. 286), while *divergent* rays will be focussed *on the retina* (*D X*, Fig. 286); consequently near objects appear distinct and distant objects appear blurred during accommodation.

Mechanism of Accommodation.—The *lens* is an elastic structure, and when released from the flattening influence of

its suspensory ligament tends to assume a spherical shape. During accommodation, the *ciliary muscle* (especially the circular fibres) *contracts*, drawing forward the choroid and *relaxing the suspensory ligament;* this diminishes the tension of the lens capsule and allows the inherent elasticity of the lens to *increase its convexity*. The change in curvature affects chiefly the anterior surface of the lens (Fig. 287). This is *Helmholtz's theory* and the one usually accepted. Tscherning has advanced a different theory: He maintains that the ciliary muscle increases the tension of the suspensory ligament during contraction, and that this causes peripheral flattening of the lens with bulging anteriorly at its centre.

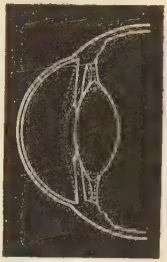

FIG. 287.—Section of the Anterior Portion of the Eyeball. The dotted lines illustrate the changes during accommodation.

The act of accommodation is accompanied by *contraction of the pupil* and by *convergence* of the visual lines.

The Far Point.—When the eye is in a state of rest, with accommodation completely relaxed, it is adapted for its far point (*punctum remotum*). This is the *farthest* point of *distinct* vision, and in the emmetropic eye it is situated at *infinity*.

The Near Point (*punctum proximum*) is the *nearest* point at which the eye can see *distinctly* when employing its maximum amount of accommodation. It *varies* with the amount of accommodation possessed by the eye. The usual plan of determining the near point is to note the shortest distance at which the patient can read the smallest test type (Jaeger, No. 1, Fig. 18) with each eye separately.

The Range of Accommodation is the *distance* between the far point and the near point.

The Amplitude of Accommodation is the *difference* between the refractive power of the eye when at *rest* and when the *accommodation* is exerted to the utmost. It is *expressed in diopters* representing that convex lens which it would be necessary to place before the eye to take the place of accommodation for the near point.

The amplitude of accommodation in diopters is found by dividing 40 by the distance of the near point in inches, or 100 by the near point in centimeters; for example, if the near point of an emmetropic eye is 8 inches or 20 cm., $\frac{40}{8}$ or $\frac{100}{20}$ = 5 D. = amplitude of accommodation; this rule applies to *emmetropia.*

In hyperopia some of the accommodation is required for distant vision; hence we find the apparent amplitude of accommodation and then add that lens which enables the patient to see distant objects without his accommodation; for example, if the near point of a hyperopic eye is 8 inches or 20 cm., and the patient is compelled to use 2 D. of accommodation for distant objects, his amplitude of accommodation would be $\frac{40}{8}$ (or $\frac{100}{20}$) = 5 + 2 = 7 D. With the same amplitude of accommodation the near point is farther away than in emmetropia, since some of the power of accommodation is expended in adapting the eye for distant objects; and if the near point were the same, the amplitude of accommodation would be greater in hyperopia than in emmetropia.

In myopia, since a concave lens is necessary to enable the patient to see distant objects clearly, we must deduct the strength of this glass from that the focal length of which equals the distance of the near point from the eye; for example, if the myopia equals 2 D. and the near point is 4 inches or 10 cm., the amplitude of accommodation will be $\frac{40}{4}$ or $\frac{100}{10}$ = 10 D. − 2 D. = 8 D. With the same amplitude of accommodation, the near point is closer to the eye in myopia than in emmetropia; and if the near point were the same, the amplitude of accommodation would be less in myopia than in emmetropia.

The power of accommodation gradually diminishes and the near point recedes as age advances, owing chiefly to loss of elasticity of the lens. In the emmetrope at 10 years, the p. p. is at 7 cm.; at 40 years it has receded to 22 cm.; at 60 years to 100 cm.; and at 75 years to infinity, the accommodation being suspended and the p. p. coinciding with the p. r. The following table gives the amplitude of accommodation and the near point at various periods of life. The near point applies

only to emmetropic eyes, but the amplitude of accommodation applies to all eyes, whether emmetropic or ametropic. There is a tendency toward increased amplitude of accommodation in hyperopia and diminished amplitude in uncorrected myopia.

Year	Amplitude of Accommodation in Diopters	Near Point in Centimeters	Near Point in Inches	Year	Amplitude of Accommodation in Diopters	Near Point in Centimeters	Near Point in Inches
10	14.0	7.0	2.8	45	3.5	28.0	11
15	12.0	8.5	3.3	50	2.5	40.0	16
20	10.0	10.0	4.0	55	1.75	55.0	22
25	8.5	12.0	4.7	60	1.0	100	40
30	7.0	14.0	5.6	65	0.75	133	53
35	5.5	18.0	7.0	70	0.25	400	160
40	4.5	22.0	9.0	75	0.0	∞	∞

Presbyopia.—When the near point of the emmetropic eye has receded to a distance at which the finer kinds of work become difficult, the condition is known as presbyopia (Chapter XXIV). This state is the result of a *physiological process* which affects *every eye* and must not be considered a disease. It is usually said to be present when the near point recedes to a distance of more than 22 cm. (9 inches) from the eye, an event which generally happens *between the fortieth and the forty-fifth years.*

The Association Between Accommodation and Convergence.—The preceding considerations of the subject of accommodation referred to monocular vision or sight with one eye. With *binocular vision* it is necessary to consider *convergence* as well as accommodation, for these two actions (together with the contraction of the pupil) are normally *associated.*

Convergence is the power of directing the visual lines of the two eyes to a near point, and results from the action of the internal recti muscles. When we look at a distant object accommodation is at rest and the visual lines are parallel. When we look at a near object, we are compelled both to accommodate and to converge for that distance; *with a certain*

amount of accommodation, a corresponding effort of convergence of the visual lines is associated.

The *angle* which the visual line makes in turning from a distant object to a near one is called the *angle of convergence*. The unit of convergence is the *meter angle* (M.A.), which is the angle formed by the visual line with the median line at a distance of 1 meter (Fig. 288). If the eyes look at an object half a meter distant the convergence is twice that of the unit, and convergence (C.) = 2 M.A.; if directed toward a point one-third of a meter distant, C. = 3 M.A.; if toward an object 2 meters distant, C. = ½ M.A.

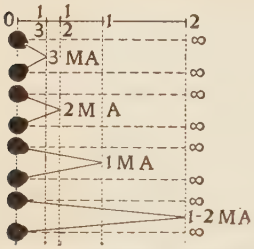

FIG. 288.—Diagram Illustrating the Unit of Convergence, the Meter Angle.

The *emmetropic* eye requires for each distance of binocular vision as many *meter angles* of convergence as it needs *diopters of accommodation*. To see an object at 1 meter distance, 1 meter angle of convergence is required and also 1 diopter of accommodation; at 10 cm., 10 meter angles of convergence and 10 D. of accommodation would be required.

This harmonious relationship between accommodation and convergence is not, however, unchangeable. Within certain limits either of these actions may take place independently of the other.

The Range or Amplitude of Convergence.—The *far point of convergence* is the point to which the visual lines are directed when convergence is at rest; the *near point of convergence* is the point to which the visual lines are directed with the maximum amount of convergence. The distance between the far point and the near point of convergence is the *amplitude of convergence;* it is expressed by the greatest number of meter angles of convergence of which the eyes are capable. In a state of rest the far point of convergence is at infinity and the visual lines are either parallel or more commonly somewhat divergent, in which case convergence is spoken of as *negative*. In cases of convergent squint, the visual lines deviate in-

ward even when convergence is relaxed; convergence is then said to be *positive*. In a case of divergent squint convergence is a negative quantity. Normally, the eyes diverge during sleep.

Methods of Determining the State of Refraction of the Eye.—There are three principal methods of testing the refraction of the eye: (1) the *subjective method*, in which the refraction is estimated by the acuteness of vision with test types and trial lenses; (2) the *ophthalmoscope;* and (3) *retinoscopy;* the last two are objective methods.

Every examination should be undertaken in a *systematic* manner. We begin with the *external examination* of the eyes as described in Chapter I. Next the patient is taken into the dark room and the *media and fundus* are examined with oblique illumination and the ophthalmoscope (Chapter III). Then the state of the refraction is determined with the *ophthalmoscope*. The retinoscopic mirror is now employed to estimate the state of the refraction with the *shadow test;* and the *ophthalmometer* may also be brought into service. Finally, the patient is examined by the *subjective method* with test lenses and test types. By employing this order we will save time, since the ophthalmoscopic examination may show changes in the media or fundus which convince us of the impossibility of improving the patient's vision with glasses, or lead us to be satisfied with a limited result. The *objective* methods of determining the state of refraction of the eye give very close and accurate results; the *subjective* method serves to verify these conclusions and often perfects them.

THE DETERMINATION OF THE STATE OF REFRACTION BY TEST TYPES AND LENSES (THE SUBJECTIVE METHOD)

After having determined the acuteness of vision for distance as described on page 12, we endeavor to ascertain *which lenses* are necessary to correct any error of refraction and to *bring the vision up to the normal* $\frac{20}{20}$. The patient is placed in front of the test types, which must be well illuminated by daylight or artificial light, at a distance of 20 feet. The trial frame (Fig. 289) is worn by the patient, and the left

eye excluded by means of a solid metal disc. After testing the right eye, we proceed with the left.

If the patient reads $\frac{20}{20}$, we may assume the absence of myopia; the patient is either *emmetropic* or he has *hyperopia* or *astigmatism.* A weak convex spherical lens (+0.50 D. Sph.) is held in front of the eye; if he is still able to read the $\frac{20}{20}$ line as well as without a lens, he has hyperopia, and the *strongest* convex spherical lens with which he can read $\frac{20}{20}$ is the measure of his manifest hyperopia. Even though he accepts a convex spherical lens, this is probably not the measure of his total hyperopia, which can be estimated in young persons only after the eye has been placed under the effects of a

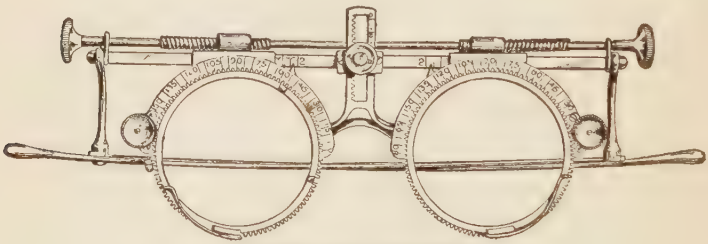

FIG. 289.—The Trial Frame.

cycloplegic. The difference between the manifest and the total hyperopia is known as the latent hyperopia; it is this portion which is discovered after accommodation has been paralyzed.

If the patient reads $\frac{20}{20}$, and a weak convex spherical lens blurs his vision, he is either *emmetropic* or has *hyperopia* which is *latent.*

If the patient's vision is below normal, and instead of reading $\frac{20}{20}$ he reads $\frac{20}{40}$ or $\frac{20}{70}$, he either has considerable manifest *hyperopia,* or else he is *myopic* or *astigmatic;* or he may have a combination of these errors. If hyperopic, spherical lenses will improve his vision. If such improvement does not result upon placing convex spherical lenses before the eye, we may try a weak concave spherical lens; if this aids his vision, he is myopic, and the *weakest* concave spherical lens that brings his vision to $\frac{20}{20}$ is the measure of his myopia. If concave spherical lenses do not improve the vision, we assume the

existence of astigmatism; and cylinders, alone or in combination with spherical lenses, are placed in front of the eye for the purpose of estimating the kind, the axis, and the amount of astigmatism.

This is, briefly, the method pursued in determining the state of refraction by means of the acuteness of vision (*subjectively*); greater details will be supplied in discussing the errors of refraction. But, as already pointed out, it is better and saves time to precede this subjective test by the objective methods, using the former to confirm the findings of the others; this is especially advisable if the error of refraction be a difficult or complicated one.

The Vision for Near is also tested. A page of *Jaeger's test types* (Fig. 18) is given to the patient, and we note the *smallest* type which he is able to read with each eye separately, the *distance* which he selects, and the *nearest* and *farthest* distances at which he is able to read. These data give us valuable information regarding the state of refraction. In myopia, the patient will hold the print closer than normal. In presbyopia he will hold it at a greater distance than normal.

THE OPHTHALMOSCOPE AS A MEANS OF DETECTING AND ESTIMATING REFRACTIVE ERRORS

The Ophthalmoscope at a Distance gives us *qualitative* information regarding errors of refraction. When the patient is *emmetropic,* no details of the fundus will be seen when the light is thrown into the eye from an ophthalmoscope held at a distance of 15 inches. If some part of the disc or vessels is seen, the patient is *ametropic.* If the examiner moves his head from side to side and the *vessels* seem to move in the *same* direction, the case is one of *hyperopia* (for in hyperopia the rays emerge divergent and the image is a virtual, erect one). If the *vessels* seem to move in the *opposite* direction, the case is one of *myopia* (since in myopia the emerging rays are convergent and form an inverted image). If the *vessels of one meridian only* are seen, *astigmatism* is present; this is hyperopic if the vessels move with the movements of the observer's head, myopic if they move in the opposite direc-

tion, and mixed if one set move with and the other against them.

The Indirect Method is not used for determining the amount of error of refraction, but we obtain information of the *form of ametropia* by noting the size and shape of the inverted image of the disc and its behavior upon withdrawing or approaching the lens before the patient's eye. If no change takes place in the shape and size of the image when we withdraw the lens, the eye is *emmetropic*. If the shape remains the same but the image becomes smaller when the lens is withdrawn, it indicates *hyperopia*. If the shape remains the same but the image becomes larger on withdrawing the lens, the case is one of *myopia*. In *astigmatism* the disc usually appears oval and the shape of its image changes in withdrawing the lens; one diameter decreases or increases, the other remains stationary in simple astigmatism; both increase or decrease unequally in compound astigmatism; one increases and the other decreases in mixed astigmatism.

The Direct Method is a useful means of determining the condition of refraction, and, in case of error, the kind and the amount; fairly reliable findings are obtained, but only after considerable practice. For accurate results, it is *necessary* that the *accommodation* of both patient and observer be *in abeyance*. The beginner always has difficulty in relaxing his accommodation, and requires considerable training before he masters this necessary step (p. 30). The patient's accommodation is suspended by directing him to look at the wall or at a distant object, or, better, by the use of a cycloplegic. The examiner, if ametropic, corrects his error by wearing suitable glasses, by having a special correcting lens applied to the sight-hole of the ophthalmoscope, or by subtracting the amount of his



FIG. 290.—The Estimation of the Refraction by the Direct Method of Ophthalmoscopy. Both patient and observer are emmetropic.

error from the result which he obtains in the examination. The examination is conducted in the manner described on page 28; for accurate results it is essential that the *shortest possible distance* separate the eye of the patient from that of the observer.

Emmetropia.—The examiner selects a *blood-vessel* at the outer margin of the disc or between the disc and the macula. If the vessel appears *distinct*, and if upon rotating a + 0.50 D. lens before the sight-hole it becomes blurred, the eye is *emmetropic*. Rays coming from an emmetropic eye at rest are parallel, and the observing eye will focus these rays on the retina (Fig. 290).

Hyperopia.—If the image is *blurred*, we rotate the lens disc of the ophthalmoscope so as to place *convex lenses* in the sight-hole; if these render the image distinct the eye is *hyperopic*. The *strongest convex lens* with which we get a distinct image is the measure of the hyperopia. In Fig. 291, *H* is the hyperopic eye under examination, and *E* the emmetropic eye of the observer. Rays from *a* emerge divergent as though

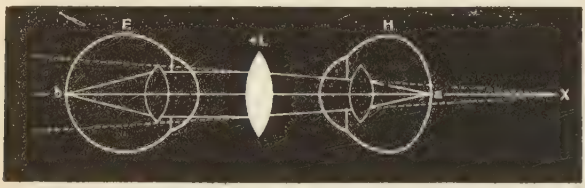

FIG. 291.—The Estimation of Hyperopia by the Direct Method of Ophthalmoscopy.

coming from *x*. The convex lens + *L* makes them parallel so that they focus at *b*, on the retina of *E*, the emmetropic eye of the observer.

Myopia.—If when the image appears *blurred*, a convex lens makes it more indistinct, we rotate the disc of the ophthalmoscope so that *concave lenses* are brought opposite the sight-hole. If these render the image *distinct*, the eye is myopic. The *weakest concave lens* is the measure of the myopia. We stop at the weakest concave lens which accomplishes this, since stronger lenses of this sort would only encourage the

observer to accommodate. In Fig. 292, *M* is the myopic eye under examination, and *E* the emmetropic eye of the observer. Rays from *a* leave the myopic eye convergent and would meet at *X*. The concave lens $-L$ renders them parallel so that they are focussed at *b*, on the retina of the observer.

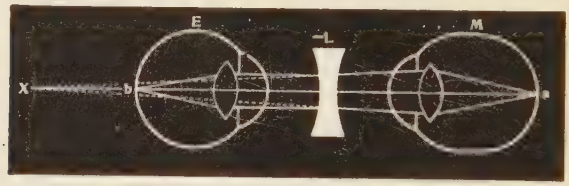

FIG. 292.—The Estimation of Myopia by the Direct Method of Ophthalmoscopy.

Astigmatism.—We find the lens with which a small *vertical vessel* is seen distinctly, and then the lens which enables a small vessel *at right angles* to be seen clearly, always remembering that the lens which clears up the image of a vessel in one direction is the measure of the refractive error of the meridian at right angles to it.

Suppose the horizontal vessels appear distinct without any lens—then the vertical meridian is emmetropic; and that the vertical vessels require a convex or a concave lens to render them distinct—then the horizontal meridian is hyperopic or myopic; the case is one of *simple* hyperopic or myopic *astigmatism* (Figs. 310 and 311).

If both vertical and horizontal vessels are rendered distinct by convex lenses but a stronger one can be used for the horizontal, the case is one of *compound hyperopic astigmatism* (Fig. 312) with the vertical meridian the more hypermetropic; if both vertical and horizontal vessels are best seen with concave lenses but of different strength, the case is one of *compound myopic astigmatism* (Fig. 313).

If the vertical vessels can be seen clearly with a convex lens and the horizontal vessels require a concave lens, the case is one of *mixed astigmatism* (Fig. 314), the horizontal meridian being hyperopic, the vertical meridian myopic.

RETINOSCOPY

Retinoscopy (*The Shadow Test, Skiascopy*) is a very accurate, objective method of determining the state of the refraction by illuminating the eye with a plane or concave mirror, and observing the *direction of the movement* of the retinal illumination and its bordering shadows, when the mirror is rotated. The shadow test has many *advantages:* It can be used in *children, illiterates,* and in markedly *defective sight;* it is entirely *objective,* and hence requires no co-operation on the part of the patient; it is *quick* and *accurate;* and it requires no expensive apparatus.

The Principle of Retinoscopy is the finding of the *point of reversal or the myopic far point.* In myopia an inverted image is formed in the air in front of the eye at the far point—the distance from which rays would be focussed on the retina; this point is known as the point of reversal. If the eye is hyperopic or emmetropic, a convex lens is placed before it so as to give it an *artificial far point.*

When light is thrown into the eye by means of a plane or concave mirror at a distance of one meter, the fundus is illuminated. By looking through the sight-hole of the mirror an observer will see the *illuminated* portion (red fundus reflex) and also the *shadow* bounding this bright area. On rotating the mirror the illuminated area and the shadow will *move across the pupil.*



FIG. 293.—Retinoscopic Mirror.

FIG. 294.—Small Retinoscopic Mirror upon Metal Disc.

The examination is conducted in the *dark* room, the darker the better. The source of *illumination* is placed *above* the head of the patient and somewhat behind so that his face is

in darkness (Fig. 295, *A*). An *Argand burner* is the most common form of illumination; it is often surrounded by an asbestos chimney with a large circular opening opposite the brightest part of the flame, so that the light is thrown only toward the observer. Some oculists prefer the light placed near the observer, about 6 inches to his left and in front, with a small (10 mm.) opening in the opaque chimney (Fig. 295, *B*).

Either a plane or a concave mirror may be employed; the *plane mirror* has certain advantages and is more commonly used. The retinoscopic mirror (Fig. 293) usually has a diameter of 3.5 cm. with a 3 mm. opening, though sometimes a 2

FIG. 295.—The Retinoscopic Examination.

cm. mirror upon a 4 cm. metal disc (Fig. 294), with a 2 mm. opening, is preferred, especially if the light is placed near the observer.

The patient is seated, his *pupils* are *dilated*, and preferably his *accommodation* should be *paralyzed*. He is directed to *look at the forehead* of the examiner, just above the mirror. Each eye is tested separately, and one eye is usually covered.

The observer is seated at *one meter distance* (Fig. 295); he should *wear correcting lenses* if ametropic; he need not relax his accommodation as in using the ophthalmoscope, since this does not influence the result.

If now the mirror be rotated slowly from side to side on its vertical axis, so that the light moves across the pupil horizontally, the observer will see an *illuminated area and a shadow* coming from behind the pupil; if the mirror be rotated on its horizontal axis the light will move across the pupil vertically. *The direction of movement* of this light and shadow as compared to that of the mirror *depends upon the state of the refraction* of the eye. The shadow moves either in the same (with) or the opposite direction (against) to that of the mirror; if we turn the mirror toward the right and the shadow moves toward the right, we say it moves with the mirror; if upon turning the mirror toward the right the shadow moves toward the left, we say it moves against the mirror. *With the plane mirror, the shadow moves with the mirror in hyperopia, emmetropia, and in myopia of less than* 1 *D., and against the mirror, in myopia of more than* 1 *D.* The illuminated area and the shadow appear to move with the mirror when the observer is within the point of reversal, and against the mirror when he is beyond this point.



FIG. 296.—Retinoscopic Illumination and Shadow in Astigmatism.

FIG. 297.—Retinoscopic Illumination and Shadow in Myopia, Hyperopia, or Emmetropia.

Besides the direction of the movement, we acquire information from the *brightness,* the *form,* and the *rate of movement* of the light and shadow: If the reflex is bright, its edge sharp, and the light and shadow move rapidly, the error of refraction is a low one; if the illumination is dull, its edge indistinct, and the movement of light and shadow slow, the error is a high one. If the shadow has a *straight* edge it is an indication of astigmatism (Fig. 296); in hyperopia, myopia, or emmetropia, the shadow has a *crescentic* edge (Fig. 297).

Next we *find the correcting lens—i.e.,* the lens which causes a *reversal* of the direction of movement of the shadow. This lens will be correct for the distance separating the observer from the patient, one meter. For infinity, we must *add* − 1

D. to all results; this increases the myopia 1 D., and diminishes hyperopia 1 D.

If with the plane retinoscope the *shadow moves against* the mirror, we place *concave* spherical lenses before the eye until we succeed in causing a reversal of the movement of the shadow—*i.e.*, cause it to move with the mirror; this lens, to which we add − 1 D., is the measure of the patient's *myopia*. Suppose on placing − 1 D. before the eye, the shadow still moves against the mirror, the same with − 2 D., but with − 2.50 D. the movement of the shadow is reversed; then − 2.50 + − 1.= − 3.50 D. is the correction.

If with the plane retinoscope the *shadow moves with* the mirror, the eye may be hyperopic, emmetropic, or myopic less than 1 D. In such a case we begin by adding a convex lens of + 0.50 D. If this causes a reversal of the shadow the eye is *myopic* 0.50 D., since + 0.50 ⊂ − 1.00 = − 0.50 D.

If the + 0.50 D. lens does not alter the direction of the movement of the shadow, but the next lens (+ 1 D.) causes a reversal, the eye is *emmetropic*, since + 1.00 ⊂ − 1.00 = 0 = E.

If the + 1.00 D. lens has no effect upon the direction of movement of the shadow, the eye is *hyperopic;* we place stronger + spherical lenses before the eye until we find the one which causes a reversal of the movement of the shadow. Say this is + 4 D.; then the hyperopia amounts to + 4.00 ⊂ − 1.00 = + 3 D.

In the previous examples, the results were the same whether the mirror was rotated upon its vertical or its horizontal axis. In *astigmatism*, upon correcting each of the two principal meridians separately, one meridian will require a different lens to cause a reversal of the shadow than the other. The most common positions of the two meridians in astigmatism are *vertical* and *horizontal*. But frequently the edges of the shadows lie more or less *obliquely*. In such cases the mirror must be rotated so that the light moves obliquely and parallel with the movement of the shadow.

For example, suppose the *shadow moves with* the mirror in both meridians, but one shadow is more distinct and moves more quickly than the other; we diagnose astigmatism. Then

we correct the vertical meridian and find it requires + 1 D. for the reversal of the shadow. Next we find that in the horizontal meridian + 2 D. are required for reversal. We add − 1 D. to each of these results and have + 1 ⌒ − 1 = 0 or E in the vertical, and + 2 ⌒ − 1 = + 1 in the horizontal meridian. The case is one of *simple hyperopic astigmatism* and requires for its correction + 1 D. cylinder, axis vertical.

If in the horizontal meridian − 2 D. are required for reversal, and in the vertical meridian, − 4 D.: Adding − 1 to each, we will have − 3 in the horizontal and − 5 in the vertical meridian. The error of refraction is *compound myopic astigmatism* and the correcting sphero-cylinder will be − 3 D. ⌒ − 2 D. cyl. axis horizontal.

Finally, let us take an example of *mixed astigmatism:* The shadow will move *with* the mirror in one meridian and *against* the mirror in the other. If in the vertical meridian the shadow moves with the mirror and + 2 D. are required to cause a reversal, and in the horizontal meridian the shadow moves against the mirror and − 2 D. effect a reversal, and we add − 1 to each, we obtain + 1 for the vertical and − 3 for the horizontal. The correcting lens will be + 1 D. Sph. ⌒ − 4 D. cyl. axis vertical.

CHAPTER XXIII

ERRORS OF REFRACTION

In *emmetropia* (E.) the eye in a state of rest, without accommodation, focusses the image of distant objects exactly upon the retina (Fig. 282); such an eye enjoys distinct vision for distant objects without effort or fatigue. Any variation from this standard constitutes *ametropia*, a condition in which the eye, in a state of rest, is unable to focus the image of distant objects (parallel rays) upon the retina. Ametropia includes *hyperopia*, *myopia*, and *astigmatism*. The effects of ametropia are not only *indistinctness* of vision but various pains and other symptoms comprised under the term *asthenopia* (weak sight, eye strain).

HYPEROPIA

Hyperopia (*Hypermetropia*, *Farsightedness*, H.) is an error of refraction in which, with accommodation completely relaxed, *parallel rays* (rays from distant objects) are brought to a *focus behind the retina* (Figs. 283, 298); divergent rays (from near objects) are focussed still farther back.

Etiology.—It is most commonly due to *shortening* of the antero-posterior diameter of the eyeball (*axial H.*), less frequently to diminished convexity of the refracting surfaces of the eye (*H. of curvature*), changes in the media, or absence of the lens (*aphakia*). It is by far the *most frequent* error of refraction and is *congenital;* in a certain sense it may be considered due to imperfect development of the eye. It is often *hereditary*. Children are usually hyperopic at birth and subsequently become less hyperopic, emmetropic, or even myopic.

The Course of Rays.—The hyperopic eye cannot, without accommodation, see either distant or near objects distinctly (Fig. 298). In a condition of rest, it is adapted for convergent rays, and these are not found in nature. To focus parallel rays on the retina it must either *accommodate, i.e.,* increase

the convexity of its lens as shown in Fig. 299, or a *convex lens* of such a strength that the rays are made sufficiently convergent to be brought to a focus on the retina (Fig. 300) must be placed in front of the eye.

To focus divergent rays, *i.e.*, rays from *near* objects, the hyperope must not only



FIG. 298.—Hyperopic Eye in a State of Rest.
FIG. 299.—Hyperopic Eye during Accommodation.
FIG. 300.—Hyperopia Corrected by a Convex Lens.



FIG. 301.—Emmetropic Eye Accommodating for Near Vision.
FIG. 302.—Hyperopic Eye Accommodating for Near Vision.

accommodate the amount required of an emmetropic eye (Fig. 301), but an *additional amount* to compensate for his error. In other words, he requires some accommodation constantly in order to see distant objects distinctly, and in addition the amount equal to that required by the emmetrope for near vision (Fig. 302). Such an eye (when the error is uncorrected) is *never in a condition of rest* as long as it enjoys distinct vision.

Changes in the Eye.—As a result of the constant strain and overaction of the *ciliary muscle,* the latter becomes *hypertrophied,* especially its circular fibres (Fig. 304); it remains in a greater or lesser condition of spasm. In high degrees of H. the eyeball may be diminished in size, the anterior chamber shallow, the sclera flat with a sharp curve at the equator, and

there may be an apparent external squint, owing to the high angle gamma (see p. 309).

Varieties.—Hyperopia is divided into (1) manifest, (2) latent, and (3) total.

(1) The *manifest* hyperopia (Hm.) is that which is detected *without paralyzing the accommodation* and is represented by the strongest convex glass with which the patient sees most distinctly; it corresponds to the amount of accommodation which he relaxes when a convex lens is placed before the eye. Manifest hyperopia may be either *facultative*, when it can be overcome by an effort of accommodation, or *absolute*, when it cannot be overcome in this manner.

FIG. 303. FIG. 304. FIG. 305.

FIG. 303.—Section of the Ciliary Muscle in an Emmetropic Eye.

FIG. 304.—Section of the Ciliary Muscle in a Hyperopic Eye.

FIG. 305.—Section of the Ciliary Muscle in a Myopic Eye.

(2) The *total* hyperopia (Ht.) is the *entire* amount of hyperopia detected after the *accommodation* has been *paralyzed* or during complete relaxation of the ciliary muscle.

(3) The *latent* hyperopia (Hl.) is the difference between the Hm. and the Ht., and is the amount which is *habitually concealed* and is discovered only after the use of a cycloplegic.

The application of these terms can be illustrated by considering an example of H. of 2.5 D. in a young person. If in such a case V = $\frac{20}{40}$, and, without the use of a cycloplegic, a + 1 D. spherical lens brings up the vision to $\frac{20}{20}$, we say Hm. = 1 D.; if now we paralyze the accommodation with a cycloplegic and find V = $\frac{20}{100}$, and that a + 2.50 D. spherical lens increases this to $\frac{20}{20}$, the Ht. = 2.50 D.; the difference between 2.50 D. and 1.00 D. = 1.50 D.= Hl.

The *ratio* between the manifest and the latent hyperopia is not constant; it depends more or less upon the age and vigor of the individual. In *youth*, the amount of Hl. is apt to be considerable, and consequently a cycloplegic is essential in estimating the amount of hyperopia. The *older* a person

grows, the less accommodative effort he is able to make; hence the Hl. becomes less, and the Hm. greater. In *old* persons there is no Hl., the total hyperopia becoming manifest.

Symptoms.—Unless the error be considerable or the patient be advanced in years, there is usually *good vision for distance.* A great many patients with hyperopia present *no symptoms* whatever; this is apt to be the case when the hyperope is young and in good health. In other cases, the accommodative efforts will be unequal to the task imposed in near work, and as a result the hyperopia will give rise to *accommodative asthenopia* (weak sight, eye strain).

The Symptoms of Asthenopia show themselves particularly after reading, writing, sewing, and other forms of *near* application, especially in the evening and with artificial illumination. They comprise *pain* referred to the eyes or above the eyes; *headaches,* usually frontal, but also occurring in the occiput and other parts of the cranium; various neuralgias; *congestion* of the conjunctiva and margins of the lids; lacrymation, blinking, and slight photophobia; *burning* sensation in the lids; and *blurring* of near vision. These symptoms are more pronounced whenever the general health is unsatisfactory.

With advancing years, there will be greater difficulty in reading without correcting glasses.

In *early childhood,* hyperopia often causes *convergent squint* in a patient whose fusion sense is deficient (p. 372).

In *children,* H. shows a physiological tendency to *diminish* with the growth of the child; after puberty it may become greater. In the adult it remains stationary; after fifty there is a tendency to a slight increase.

Hyperopic eyes are *predisposed* to conjunctivitis and blepharitis, phlyctenular affections, congestion of the retina and choroid, internal squint, and glaucoma.

Tests.—These have been described in the preceding chapter. They are the following:

The Subjective Test with Test Types and Test Lenses.—We first record the acuteness of vision and then place convex lenses before the eye, commencing with + 0.50 D. The *strongest lens* with which the patient sees $\frac{20}{20}$ or better is

the measure of the *manifest* hyperopia. Then the accommodation is paralyzed and the test repeated; the strongest lens "accepted" (*i.e.*, with which the patient's vision is improved) is the measure of his *total* hyperopia. Such an examination is recorded as follows:

O. D. V = $\frac{20}{20}$; Hm. 0.50 D.; Hom: V = $\frac{20}{100}$; $\frac{20}{20}$ w. + 2 D. S. Translated, this line would read: Oculus dexter (right eye), vision equals $\frac{20}{20}$; manifest hyperopia 0.50 D.; after the use of homatropine, vision equals $\frac{20}{100}$, increased to $\frac{20}{20}$ with a convex spherical lens of 2 diopters.

The Ophthalmoscope at a Distance.—The retinal vessels appear to move in the same direction as the observer's head.

The Ophthalmoscope, Indirect Method.—On withdrawing the lens in front of the patient's eye, the size of the disc diminishes.

The Ophthalmoscope, Direct Method.—The disc and vessels can be seen distinctly with a convex lens in the sight-hole, the strongest being the measure of the H.

Retinoscopy.—With the plane mirror held at one meter, the shadow moves with the mirror; the direction of movement is reversed by convex lenses placed in front of the patient's eye. The lens which causes a reversal, minus 1 D., is the measure of the H.

Treatment consists in prescribing such *convex spherical lenses* as will make *vision distinct* and enable the patient to do near work *without fatigue.* The mere existence of hyperopia is no indication for the use of correcting glasses unless these are worn in childhood for the cure of convergent squint. It is only when there is a diminution in the acuteness of vision or when symptoms arise indicating eye strain that convex lenses should be used.

Though theoretically it would seem proper to prescribe the full correction (for Ht.), practically there are many objections and exceptions to this. In *every case* of hyperopia occurring in *children* and in *young adults,* the *accommodation should be paralyzed* and the *total error* estimated so as to serve as a basis for the prescription for glasses.

The *symptoms* of the individual give us reliable indications as to the *proportion* of the Ht. which ought to be corrected,

and the *constancy* with which the glasses should be worn. In cases of squint, and when glasses are prescribed for the relief of conjunctivitis, blepharitis, and headaches which are continuous, or the occurrence of which is independent of near use of the eyes, they must be worn constantly. In other cases, glasses should be worn continuously or only for near, according to whether the symptoms are always present or follow only after using the eyes for reading and the like. When distant vision is perfect and comfortable, and the patient does not suffer from any symptoms except when engaged in near work, glasses need be prescribed only for such use; this is often the case in young adults who enjoy good health. Under such circumstances, the correction of the Hm. may be sufficient; or we may add to this the correction for part of the Hl., or we may correct the Ht. In cases in which the correction is only partial, the glasses may require changing from time to time. In hyperopes after forty-five, convex lenses should be worn to improve distant vision, and a stronger pair for near; the weaker set is for the H., the stronger pair to correct both the hyperopia and the presbyopia. Under such circumstances, *bifocal lenses* (Figs. 324–327) are very convenient, the upper segment corresponding to the weaker glass, the lower to the stronger.

MYOPIA

Myopia (*Nearsightedness, Shortsightedness,* M.) is that refractive condition in which, with accommodation completely relaxed, *parallel rays* are brought to a *focus in front of the retina.* These rays cross in the vitreous; when they reach the retina they have become divergent, forming a circle of diffusion and consequently a blurred image (Fig. 306, *PPF*). Certain divergent rays, coming from the myopic far point, are focussed on the retina (Fig. 306, *DX*) without accommodation.

The greatest distance at which the patient can read fine print is the *far point.* This is always at a definite distance *corresponding to the amount of M.;* the higher the M., the closer to the eye is the far point; the distance of the latter is the *measure of the M.* For example, if the far point is at 20

inches (.5 meter) the M. = 2 D. ($\frac{40}{20}$ or $\frac{100}{50}$ = 2); if at 10 inches (.25 meter) the M. = 4 D. In these two instances concave lenses of 2 and 4 D. respectively would render parallel rays as divergent as if they came from a distance of 20 and 10 inches (.5 and .25 meter); and with these lenses, the myope would be able to see distant objects distinctly (Fig. 307)

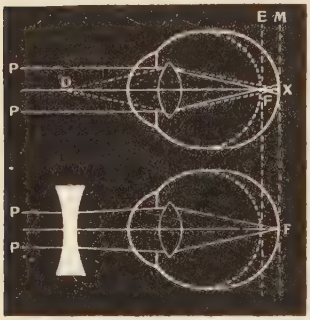

FIG. 306.—The Focussing of Parallel and Divergent Rays in Myopia.

FIG. 307.—The Correction of Myopia by Means of a Concave Lens.

Etiology.—Myopia almost always depends upon a *lengthening* of the antero-posterior diameter of the eyeball (*axial myopia*); in M. of 3 D., for example, the eyeball measures 24 mm. in its antero-posterior diameter, and in M. of 10 D., 27 mm. from before backward, instead of 23 mm., the normal diameter. Much less frequently M. is due to increased curvature of the cornea (anterior staphyloma and keratoconus), increase in the refraction of the lens from swelling in incipient cataract, and spasm of accommodation. The determining *causes* are associated with the demands which *civilization* and *education* make upon near vision. It is rarely congenital, though there is often an *hereditary* tendency for its development. It is an *acquired* change which commences at an early age when, during the developing period, the *eyes are used excessively or improperly for near work*. Its occurrence is in direct proportion to the standard of education, and also bears a certain relation to the general health and strength of the individual. It is much more common in cities than in the country. It increases in percentage from the lower to the higher classes in schools and universities.

Excessive study with insufficient outdoor exercise, fine or *indistinct print*, *poor illumination*, opacities of the cornea and other lesions causing imperfect vision, faulty construction of *desks*, sedentary habits, and *poor health* are among the fre-

quent exciting causes of myopia, especially in those who are predisposed.

The cause of the lengthening of the eyeball is attributed (1) to pressure of the extraocular muscles during excessive convergence causing the posterior pole, which is the least resistant part of the eyeball, to bulge; (2) to congestion, inflammation, and softening of the layers of the eyeball, together with increased tension, produced by fulness of the veins of the head as a result of stooping postures and other predisposing causes; and (3) to the shape of the orbit in broad faces causing excessive convergence, as seen in the German race, which is especially subject to this error of refraction.

Clinical Forms.—In most instances, myopia is of low degree, develops during youth, and then comes to a standstill or increases very little; this is known as *stationary* or *simple myopia.*

In other cases, the error reaches a considerable height in youth, and *increases* steadily up to the twenty-fifth year or even later, resulting in a *high degree* of myopia; this is known as *progressive myopia.* These are the cases which are accompanied by destructive *changes* in the choroid and other parts of the eye, leading to a considerable impairment of vision, and in which myopia may properly be considered *a disease.* Extreme cases of progressive myopia are known as *malignant myopia.*

Symptoms depend on the degree of myopia.

In slight degrees and in many cases of moderate amount, there are often no symptoms except *indistinct vision for distance.* Near work can be accomplished with comfort; in fact, since the myope requires less accommodation than the emmetrope, he may have an advantage in close application. It is on this account that the circular fibres of the ciliary muscle are less developed than in the emmetropic eye (Fig. 305).

In other cases of moderate myopia and in *high degrees,* distant vision is very *indistinct;* there is often *pain* in the eyes after near use; the patient will be unable to continue at work for any length of time on account of excessive convergence; the eyes *tire easily,* are sensitive to light, and *irritable;* there

are black spots before the eyes (muscæ volitantes), and sometimes bright flashes of light. In some cases there may be absolute scotomata.

In high myopia, there are often prominence of the eyes, a deep anterior chamber, and dilated pupils; the patient is apt to screw the eyelids together; there is sometimes an appearance of convergence. The strain of excessive convergence is so great and painful, that the effort is sometimes given up and divergent squint results.

Ophthalmoscopic Signs.—*In low* (less than 3 D.) *or moderate* (3 to 6 D.) degrees, there are frequently no changes except a crescent-shaped patch of atrophy of the choroid of whitish or grayish-color, embracing the outer side of the disc; this is called a *myopic crescent.*

In high myopia (more than 6 D.), a well-marked *crescent* is usually found, often *posterior staphyloma* (bulging of the sclera, Fig. 177, Plate XIV), and there may be patches of *choroidal atrophy* with pigmented margins, exposing the sclera. In *progressive cases*, there are frequently added to these lesions atrophic and pigment changes in the *macular region* (Fig. 174, Plate XIII), *hemorrhages*, especially at the yellow spot, *fluid vitreous* (causing tremulous iris), *opacities of the vitreous* and of the lens; sometimes there is detachment of the retina. Owing to these changes, the *vision* is often very markedly *reduced* and is sometimes *lost* in severe forms of progressive myopia.

Tests.—*The Subjective Test with Test Types and Test Lenses.* Distant vision is below the normal and the patient requires a *concave* spherical lens to bring the sight up to $\frac{20}{20}$. The *weakest* lens which accomplishes this is the measure of the myopia. In young persons it is important to *paralyze the ciliary muscle*, so that spasm of accommodation will not cause the patient to select too strong a lens. The results are recorded as follows: O.D. V = $\frac{20}{200}$; $\frac{20}{20}$ w.− 4 D. Sph. The reduction in distant vision generally corresponds to the amount of M.

The myope is able to read the smallest print, but at a shorter distance than that which the emmetrope selects. The

farthest distance at which he is able to read the finest print is his *far point*, and this is also the *measure of his M.*

The Ophthalmoscope at a Distance shows an inverted image of the fundus which appears to move in the opposite direction to the examiner's head.

The Ophthalmoscope, Indirect Method.—The disc appears small and seems to increase in size upon withdrawing the objective lens.

The Ophthalmoscope, Direct Method.—The fundus cannot be distinctly seen until a concave lens is placed behind the mirror; the weakest concave lens with which the details are seen clearly, indicates the amount of myopia.

Retinoscopy.—With the plane mirror and the observer at 1 meter distance, the shadow moves in the opposite direction (except when M. is less than 1 D.), and is reversed by the addition of concave lenses. The lens which causes reversal plus − 1 D. is the measure of the M. In high M. the shadow is very faint, but becomes plainer when concave lenses are added.

Prognosis.—In low and moderate degrees of *stationary myopia*, the prognosis is *good* when suitable glasses are worn. *Progressive myopia* is always a *serious* condition, especially when the choroidal and vitreous changes are marked; it frequently necessitates absolute cessation of all near work. In *malignant myopia* the prognosis is *grave*.

Treatment consists in prescribing suitable *glasses, limiting* the amount of *work* so that there will be no fatigue, and *preventing the progress* of the disease.

In general terms, it is proper to give a *full correction for low and moderate myopia in young persons,* as soon as discovered, and to direct these glasses to be worn for *both distance and near;* this places the eyes under normal conditions of vision and accommodation. The glasses must be prescribed after the accommodation has been paralyzed, so that there will be no danger of over-correction on account of spasm of accommodation. Full correction corresponds to the *weakest* concave spherical lens which, with accommodation paralyzed, gives the best vision. In low degrees of M. an adult may be allowed to read without glasses if he finds this convenient.

In *high myopia,* the full correction is prescribed for distance, and about two-thirds correction for near work; the reading-glasses should be such as to enable the patient to read at a comfortable distance, say 13 inches (33 cm.). Suppose − 10 D. gives the best vision for distance; then − 10 D. + 3 D. Sph. = − 7 D. will enable him to read at this distance without accommodation.

After the age of 45, the distance glasses cannot be worn for near work, since the convex lenses usually required for presbyopia must be added to the concave lenses, thus reducing the strength of the latter.

In prescribing glasses in M. every case must be considered on its merits. Many myopes wear strong lenses, representing the full correction, constantly and with absolute comfort; others require two sets of lenses, one for distance and a weaker pair for reading.

In order to check any tendency to increase of M., *rigid hygienic rules,* both local and general, should be carried out. These are of especial importance in the young. The patient's *habits* should be *regulated* to insure good health. He should have an abundance of *outdoor exercise* and plenty of *sleep.*

Near work should be restricted and the patient not be allowed to read too long at a time. The book should be held at 13 inches (33 cm.). In most cases the *full correcting lenses* should be worn for near work. The *illumination* should be good, neither too bright nor too dim, and should come *from behind;* the myope should avoid reading at dusk or with feeble illumination; the amount of work done with artificial light should be limited. The *print* should be large and clear, with ample spacing. *Desks* should be constructed so that the sitting posture is comfortable, and so that the child is not encouraged to stoop over his books; the myope must be taught not to bend over his work, but to lift the latter to the required distance from the eyes.

If notwithstanding such precautions, myopia progresses, it is necessary to forbid all near use of the eyes. A good plan is to take the patient from school and send him to the *country* for a long period, during which he is instructed to be out-of-

doors as much as possible, and to avoid all reading and near work. Young adults suffering from progressive myopia should *give up sedentary occupations* necessitating close application, and select those in which but little near use of the eyes is required.

Operative Treatment.—In children and young adults with *high myopia,* uncomplicated by excessive pathological changes in the fundus, the *removal of the lens* by discission and subsequent extraction is frequently very successful. The lens is needled, and after several days the swollen lens substance is removed by extraction. The operation is limited to *M. of* 15 *D. or more.* After the removal of the lens the eye may be almost emmetropic, since the optical effect in such highly myopic eyes is quite different from that which follows extraction of the lens in the emmetrope; a weak convex glass may be required for distance, and a stronger one for near work since the accommodation has been sacrificed. The operation does not seem to increase or decrease the danger of complications. Suitable cases present themselves much less frequently in America than in Germany, where myopia is very common.

ASTIGMATISM

Astigmatism (*Astigmia;* As.) is that refractive condition of the eye in which there is a *difference in degree of refraction in different meridians,* so that each will focus parallel rays at a different point (Figs. 310–314).

In E., H., and M., rays coming from a luminous point are brought to a single focus at a certain distance behind the cornea. In astigmatism, since the refractive surfaces are not spherical, rays from a luminous point are brought to a focus at different points; the shape of the image may be a line, an oval, or a circle, but never a point.

Astigmatism may be (1) *Regular,* very common, and (2) *Irregular,* comparatively infrequent.

Regular Astigmatism is that form in which, though the refraction in a meridian is the same throughout, there is a *difference in the degree of refraction in every meridian*—the curvature of the cornea is different in different meridians.

One meridian exhibits the *maximum* and the other the *minimum* refraction; these are called the *principal meridians* and are *always at right angles* to each other. The refractive power of all other planes will be regularly intermediate according to their position with regard to the principal meridians.

Irregular Astigmatism, on the other hand, is that variety in which there is not only a difference in refraction in different meridians, but also in *different parts of the same meridian.*

When the term astigmatism is used without qualification, it refers to regular astigmatism.

Etiology.—Astigmatism is usually due to a change in the *curvature of the cornea*, with or without some shortening or lengthening of the antero-posterior diameter of the eyeball. It is also caused, in part at least, by defects in the curvature of the lens; this *lenticular* astigmatism may partly neutralize that of the cornea. It is usually *congenital* and there is often an *hereditary* tendency; it may, however, be *acquired*, and is then caused by corneal changes from inflammation, injury, or operation. Pressure of the lids in ametropia is believed to be capable of producing permanent regular astigmatism.

Even the normal eye has a slight amount of regular astigmatism, due to the fact that the cornea is the segment, not of a sphere, but of an ellipsoid; consequently there is a slight difference in the refraction of the two principal meridians, the curvature of the vertical meridian being greater than that of the horizontal; hence the focus of the former is somewhat shorter than that of the latter.

Refraction of Rays in Regular Astigmatism.—Parallel rays refracted by a spherical surface form a circular cone and focus at a point. In astigmatism, those rays which pass through the meridian of greater curvature come to a focus sooner than those which pass through the meridian of lesser curvature; the resulting cone will not be circular, but more or less oval; hence the vision of astigmatic subjects is not simply indistinct, but the diffusion images are more or less elongated.

In looking at straight lines (which are made up of a succession of points), these may appear distinct or indistinct to astigmatic persons according to their direction. If an astig-

matic eye, in which the vertical meridian is out of focus and the horizontal meridian normal, looks at a vertical line, this will be slightly elongated; but the sides will appear distinct, since each point of light will be seen as a small vertical line, and these overlap each other. But if such an eye looks at a horizontal line, each point of light will again be seen as a small vertical line, and consequently the line will appear blurred (Fig. 308). There is, therefore, one direction in which straight lines appear most distinct, and another at right angles to it, in which they appear most indistinct; this forms the basis for the construction of the astigmatic dial or fan (Fig. 315) commonly used as a test for this error. *The lines parallel with the ametropic meridian are seen most clearly, and those parallel with the emmetropic meridian are seen most indistinctly* (in simple As.).



Fig. 308. Fig. 309.

Fig. 308.—Vertical and Horizontal Lines as Seen by an Astigmatic Eye in which the Horizontal Meridian is Emmetropic.

Fig. 309.—Vertical and Horizontal Lines as Seen by an Astigmatic Eye in which the Vertical Meridian is Emmetropic.

Varieties of Regular Astigmatism.—According to the refraction of the principal meridians, astigmatism is divided into:

1. *Simple*, in which one meridian is emmetropic and the other hyperopic or myopic; it comprises simple hyperopic astigmatism (H. As., Fig. 310), and simple myopic astigmatism (M. As., Fig. 311).



Fig. 310.—Simple Hyperopic Astigmatism.



Fig. 311.—Simple Myopic Astigmatism.

2. *Compound*, in which both meridians are either hyperopic or myopic, but unequal in degree; it comprises compound hyperopic astigmatism (H. + H. As., Fig. 312), and compound myopic astigmatism (M. + M. As., Fig. 313).

3. *Mixed*, in which one meridian is hyperopic and the other myopic (H. As. + M. As., Fig. 314).

In most cases of astigmatism, the cornea presents its



FIG. 312.—Compound Hyperopic Astigmatism.



FIG. 313.—Compound Myopic Astigmatism.

maximum curvature in or near the *vertical meridian* and the least curvature in or near the horizontal meridian, corresponding to the slight astigmatism of the normal eye; when this is the case, it is said to be *astigmatism with the rule;* when the relative curvatures are reversed, it is *astigmatism against the rule.* In astigmatism with the rule the axis of the cylinder is vertical or nearly so in hyperopic astigmatism, and horizontal or nearly so in myopic astigmatism. The chief meridians, though *vertical* and *horizontal* in the majority of cases, may occupy an *oblique* position; in such cases they are most frequently *symmetrical*, *i.e.*, inclined an equal number of degrees from the vertical or horizontal on each side.



FIG. 314.—Mixed Astigmatism.

Symptoms.—There is always a *diminution in the acuteness of vision* both distant and near, varying with the degree and variety of astigmatism; it is least with simple astigmatism, more with compound astigmatism, most with mixed astigmatism. There is commonly considerable *asthenopia*, especially upon use of the eyes for near work. These asthenopic symptoms are similar to those occurring in hyperopia (p. 329), but are apt to be more pronounced and continuous. They vary with the degree and variety of astigmatism, the amount of near work indulged in, and especially the state of the patient's health; a small amount (0.50 D. or even 0.25 D.)

will, for instance, often give rise to severe asthenopic and nervous symptoms in a young, delicate, neurasthenic individual. The involuntary accommodative efforts of the ciliary muscle, made to diminish the effects of the error, cause continuous *eye strain* and explain the frequency of asthenopia.

Tests.—We usually *suspect astigmatism* when vision cannot be brought up to $\frac{20}{20}$ with spherical lenses, notwithstanding the fundus is normal and the media are clear. In testing for astigmatism in children and in young adults, sometimes even in adults of forty, and occasionally after this age, it is necessary to have the eye under the influence of a *cycloplegic;* otherwise the results are apt to be unsatisfactory.

The Astigmatic Dial.—The diagnosis of astigmatism is made if the patient, when placed before the astigmatic dial or fan (formed of radiating lines numbered like the face of a clock, Fig. 315), is unable to see all the lines with equal distinctness. The line seen most distinctly and the line seen least distinctly indicate the axes of the two principal meridians; the axis of the former corresponds to the ametropic meridian, that of the latter to the emmetropic meridian (in simple astigmatism).

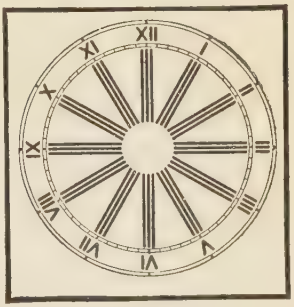

FIG. 315.—Astigmatic Dial.

Suppose in an example of simple astigmatism, the patient sees lines *XII* and *VI* most distinctly and those at right angles, *IX* and *III*, least clearly; then the ametropic meridian is vertical. If a weak convex lens placed in front of the eye makes lines *XII* and *VI* indistinct, we know that the horizontal meridian is emmetropic. Next we find which spherical lens clears up lines *IX* and *III;* this glass is the measure of the refractive error of the vertical (ametropic) meridian.

The Metal Disc with Stenopæic Slit (about 1 mm. in diameter) may be used to discover the *two principal meridians* (and the amount of astigmatism). It is placed in front of one eye, the other being excluded, and is rotated slowly so

that the slit occupies each meridian successively. The patient is placed at 20 feet before the distant test types and the position of the slit in which the best vision is obtained is noted. Then convex or concave lenses are placed in front of the slit, and the strongest convex or the weakest concave lens which gives the most improvement is the measure of the refraction in this meridian. The slit is then turned 90°, and convex and concave lenses are again applied until one is found which improves vision most. In this way the refractive error of the two principal meridians is determined. If, for instance when the slit is vertical the patient reads $\frac{20}{20}$, and convex lenses in front of the slit make the types indistinct, the vertical meridian is emmetropic; if, when the slit is horizontal, the patient reads $\frac{20}{50}$, but this increases to $\frac{20}{20}$ when + 3 D. Sph. is placed in front, the horizontal meridian is hyperopic 3 D.; this case would be one of simple hyperopic astigmatism corrected by a + 3 D. cylinder, axis vertical.

The Subjective Method with Test Types and Test Lenses is best employed after the objective tests have furnished us with pretty definite conclusions regarding the correcting lenses. It then serves to confirm or improve upon the results obtained by objective methods: The lenses selected by the latter tests are placed in the trial frame and may then require modification, either in the strength of the sphere or the strength and axis of the cylinder, so as to secure the most acute vision.

The Ophthalmoscope, Indirect Method.—The shape of the disc is *oval* instead of circular, and changes when the objective lens is withdrawn.

The Ophthalmoscope, Direct Method.—The disc appears oval, the elongation corresponding to the meridian of greatest refraction. To determine the kind and amount of error we estimate the refraction of a small vertical blood-vessel and then of a small horizontal vessel near the disc, by means of the strongest convex or the weakest concave lens with which these are distinctly seen. For instance, suppose a vertical vessel is seen clearly with + 2 D. Sph. (indicating hyperopia of horizontal meridian), and a horizontal vessel with + 4 D. (indicating a greater amount of hyperopia in the vertical

meridian); the case is one of compound hyperopic astigmatism. When the principal meridians are oblique, we find a vessel the direction of which corresponds to one of the meridians, and then another at right angles to the first, and estimate the refraction of each.

Retinoscopy is the *most rapid and reliable* objective method of determining astigmatism. The principal meridians are clearly indicated by the edge of the shadow (Fig. 296). Each of the principal meridians is corrected separately by causing a reversal of the movement of the shadow by spherical lenses, and adding − 1 D. (with plane mirror at 1 meter distance).

The Cphthalmometer (Fig. 316) is an instrument used for determining the principal meridians and the amount of *corneal astigmatism.* It is of service when used in connection with other tests. It consists of a telescope containing a combina-

FIG. 316.—The Ophthalmometer.

tion of convex lenses and a bi-refracting prism, supporting a graduated arc upon which are two sliding objects called "mires" (Fig. 316). The latter are of white enamel, one quadrilateral in shape, the other of similar size but cut out on

one side into steps; both are divided in the middle by a horizontal black line. The patient's face is placed in a frame at the other end of the instrument and steadied by chin and forehead rests. The mires are reflected upon the cornea, and the observer, looking through the tube and focussing, sees four images in a line. The two peripheral images are ignored; the two central ones are approximated until their inner edges touch and the black lines subdividing the mires form one continuous straight line; it may be necessary to revolve the barrel of the telescope more or less of 45° to the right or left to accomplish this. This position, indicated on a dial, gives the meridian of least refraction. Next the arc is turned at right angles to this meridian. If the images of the mires are still in apposition, the curvature of the cornea is uniform and there is no corneal astigmatism (Fig. 317). If in the second meridian the relative position of the images of the mires has changed, each step which is overlapped by the quadrilateral figure indicates 1 D. of astigmatism (Fig. 318).

FIG. 317.



FIG. 318.

FIG. 317.—The Mires of the Ophthalmometer Indicating an Absence of Corneal Astigmatism.

FIG. 318.—The Overlapping of the Mires of the Ophthalmometer Indicating 1 D. of Corneal Astigmatism.

Placido's Disc or Keratoscope (Fig. 6) consists of a circular disc upon which are painted alternate rings of black and white. The patient is placed with his back to the light and fixes the centre of the disc, while the examiner looks through an opening in the centre and sees an image of the concentric circles reflected upon the patient's cornea. If no astigmatism is present the rings are circular (Fig. 319). If regular astigmatism exists, the rings will appear elliptical with the long axis corresponding to the meridian of least curvature (Fig. 320). If the cor-

FIG. 319.



FIG. 320.

FIG. 321.

FIG. 319.—Corneal Reflection of Placido's Disc in Emmetropia.

FIG. 320.—Corneal Reflection of Placido's Disc in Regular Astigmatism.

FIG. 321.—Corneal Reflection of Placido's Disc in Irregular Astigmatism.

nea is the seat of irregular astigmatism the rings will be distorted (Fig. 321). This forms a very useful test for irregular astigmatism.

The Correction of Astigmatism.—Astigmatism is corrected by cylinders, sphero-cylinders, and sometimes by crossed cylinders (p. 306). The curve of the correcting cylinder corresponds to the ametropic meridian; consequently its axis is at right angles to this meridian.

Treatment consists in prescribing *glasses* which correct the error. In some cases of high degree it is impossible to obtain V. $\frac{20}{20}$ even with full correction; we often have to be satisfied with $\frac{20}{30}$ or $\frac{20}{40}$. But the vision often improves after the lenses have been worn for a time. The glasses should be *worn constantly*. When the correction has been estimated with the eye under the effects of a cycloplegic, a slight reduction must be made in cases of moderate or high degrees of astigmatism; after a while, the full correction will be tolerated. The relief which cylinders give is usually very pronounced.

The Direction of the Axis of a Cylinder is indicated according to two systems:

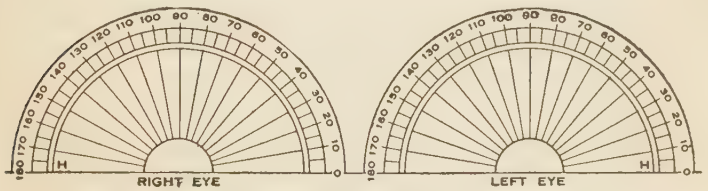

FIG. 322.—Ordinary Method of Designating the Axis of Cylinders.

(1) By the angle which the axis makes with the horizontal, this angle being numbered from 0° on our right (as we stand before the patient) to 180° on our left (Fig. 322); *i.e.*, 0° is placed at the end of the horizontal meridian to the patient's left, and the degrees are counted on the upper semicircle to 180° at his right (either eye).

(2) The position of the axis is denoted by the angular deviation of the upper end of the cylinder from the vertical meridian, either on the nasal or the temporal side. The vertical

meridian is indicated by V, the horizontal meridian by H, the angles on the temporal side by t, and those on the nasal side

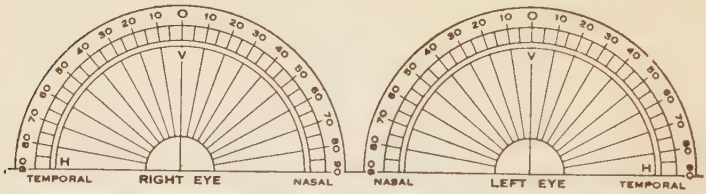

FIG. 323.—Bisymmetrical Method of Designating the Axis of Cylinders.

by n. Thus, $30n = 30°$ toward the nasal side; $60t = 60°$ toward the temporal side, from the vertical meridian (Fig. 323).

Irregular Astigmatism is that variety in which there is not only a difference of refraction in different meridians, but also in *different parts of the same meridian.* It is generally due to changes in the *cornea*, such as opacities and cicatrices following ulceration, injuries, or surgical operations, and keratoconus. It may also result from partial dislocation of the *lens*, or from a congenital or acquired change in the refractive power of different sectors of the lens. The acuteness of *vision* is considerably *diminished* and *cannot be improved materially by glasses.* Details of the *fundus* when seen with the ophthalmoscope appear *distorted.* An insignificant amount of irregular astigmatism is present normally, and accounts for our seeing the stars as stellate points instead of round dots.

ANISOMETROPIA

This term is applied to cases of *marked inequality* in the state of refraction of the two eyes; slight differences are present in most cases of errors of refraction. Every combination may occur: (1) One eye may be emmetropic and the other ametropic; (2) both eyes may have the same variety of ametropia, but of unequal degree; (3) one eye may be myopic and the other hyperopic, either simple or combined with astigmatism. Notwithstanding the unequal refraction, there is usually binocular vision; sometimes the eyes are used alternately; in other cases one eye is habitually excluded from vision.

In prescribing glasses no arbitrary rules can be followed; each case must be considered by itself. When one eye is emmetropic and the other ametropic, no glass will probably be required, unless it be to prevent the ametropic eye from suffering from disuse, or for the relief of asthenopic symptoms. When the difference in the refraction is not great (1 to 2 D.) and there is good binocular vision, we may give each eye its correction. Even when the difference is greater, correcting lenses will often give satisfaction; but when full correction causes discomfort we must be satisfied with a partial correction. When there is no binocular vision, we generally give a correcting glass for the better eye; in such cases, if the poor eye still possesses vision, the patient should be advised to exercise it daily with the aid of a suitable lens, the good eye being excluded.

ASTHENOPIA

Asthenopia (*Weak Sight* or *Eye Strain*) is a convenient term which embraces the group of symptoms dependent upon *fatigue* of the *ciliary* muscle or of the *extraocular muscles*.

Symptoms.—The condition is of very *frequent* occurrence and causes a great variety of symptoms. The most common manifestations of asthenopia are: (1) *Pain* in or around the eyes or *headache*, usually aggravated by use of the eyes for close work, and in some cases present only after near use. (2) *Fatigue and discomfort* upon use of the eyes for near; this shows itself by inability to indulge in such work for more than a short period at a time, without the occurrence of dimness of vision and confusion of the lines of print, pain in and about the eyes, headache, drowsiness, lacrymation, photophobia and congestion, and an irritable condition of the lids accompanied by itching and burning sensations. These symptoms are regularly *worse at night*, when the patient is *tired*, or when *artificial illumination* is employed. (3) *Vertigo* and a tendency to diplopia. (4) *Reflex symptoms*, such as nausea, twitching of the facial muscles, migraine, chorea, neurasthenia, and possibly other neuroses.

The amount of asthenopia depends not only upon the kind

and degree of defect, but also upon the *state of the patient's health*, and is therefore pronounced in delicate, anæmic, and neurasthenic individuals.

Varieties.—1, Accommodative. 2, Muscular. 3, Neurasthenic. Two of these varieties may be associated.

Accommodative Asthenopia is the most common variety. It is due to strain and *fatigue of the ciliary muscle* when used too constantly or excessively, in *ametropia*. It is especially frequent in astigmatism and hyperopia, but is common enough in myopia and in presbyopia. Treatment consists in the use of *glasses* correcting the error of refraction as advised in preceding pages. In delicate and neurasthenic individuals attention to the *general health* is very important.

Muscular Asthenopia is due to a want of balance of the motor apparatus of the eye (*heterophoria*), necessitating an abnormal strain to preserve single binocular vision. It may be associated with ametropia and its existence be dependent upon the latter error, or it may occur in emmetropia. Heterophoria is described in Chapter XXV.

Neurasthenic Asthenopia (*Nervous, Hysterical, or Retinal Asthenopia*) is the variety which occurs in emmetropic patients, or in ametropes in whom proper correcting lenses and treatment of any existing heterophoria give no relief. The symptoms are ascribed to *lack of nerve-tone;* occasionally they are supposed to be due to retinal anæsthesia or hyperæsthesia. The condition is a neurosis and dependent upon a general asthenic condition of the nervous system; consequently it is found most frequently in young women with hysterical tendency, who suffer from anæmia, neurasthenia, and often menstrual disorders; also in neurasthenic individuals in general, and in convalescents from debilitating diseases. It is often very *troublesome* and *obstinate*. The more carefully one investigates the state of refraction and the motor balance of the eye, the fewer cases one finds necessary to classify as neurasthenic. *Treatment* consists in removing the defect in the *general condition, rest* of the eyes, and particularly *attention to hygiene*, such as the regulation of habits, outdoor *exercise*, etc.

MYDRIATICS AND CYCLOPLEGICS

The action of these agents and the method of obtaining the best results with them are described in Chapter XXVI.

A cycloplegic is *indicated* in the estimation of the refraction in all cases of *children and young adults*, in many cases between the ages of 40 and 45, and occasionally between 45 and 50 when the previous investigation of the refraction without paralysis of accommodation has been unsatisfactory. Before using these agents in elderly persons, any suspicion of *glaucoma* must be excluded.

Homatropine (2 per cent.), or homatropine, 2 per cent., combined with cocaine, 1 per cent., is the agent most frequently employed; one drop is instilled every 3 minutes for 4 doses, and the examination begun at the end of an hour and a quarter after the last instillation.

Exceptionally, homatropine fails to produce complete paralysis of accommodation, as shown by more or less contradiction in the results of the objective and subjective tests. In such cases, particularly in children, we may resort to atropine (1 per cent.), one drop being instilled 3 times daily for 2 or 3 days (smoked glasses may be worn during this period), and a final drop directly before the examination.

In children and in young adults, it is proper to make one examination without a mydriatic, a second under the influence of homatropine, and then to base the prescription for glasses upon a comparison of these results, according to the rules given in the preceding pages.

THE FITTING OF EYEGLASSES AND SPECTACLES

Much of the comfort and relief which lenses bring depend upon the skill with which the glasses are *fitted* to the face. Whether eyeglasses or spectacles, the lenses must be supported in their frames in such a manner that the distance between their geometric centres corresponds to the interval between the centres of the pupils (*interpupillary distance*).

If the glasses are to be worn constantly, the geometrical centre of the lenses should be slightly below the centre of the pupils, and the lenses *tilted* so that their surfaces form an

angle of about 15° with the plane of the face. If worn for distance only, the level of the lenses should be the same and the tilting about 10°. If worn for near work only, the lenses should be lower, and inclined about 25°.

In every case the glasses should be worn as *near the eyes* as possible, just avoiding the lashes.

Lenses are usually made of crown glass. The *periscopic* form of spherical lenses (p. 298) is preferred. In *cylinders*, one surface may be plane and the other curved; but such lenses can also be ground with two curved surfaces, the cylinder corresponding to the outer surface. *Sphero-cylinders* usually have the spherical lens on one surface and the cylindrical lens on the other. In *toric lenses* both the cylindrical and spherical curves are ground on the outer surface, the inner being deeply concave; this gives an enlarged field and reduces the weight and thickness of the lens. Lenses cut from crystal are known as *pebbles;* they have the advantage of being less easily scratched.

In cases of *astigmatism*, it is necessary that the *axis of the cylinder be constant.* On this account spectacles are often preferred to eyeglasses, because with the latter the axis of the



FIG. 324.—Bifocal Lens (Oval Paster).



FIG. 325. Bifocal Lens (Circular Paster).

cylinder may vary according to how the glasses are worn or how they preserve their original adjustment. But eyeglasses can be worn in such cases, if the optician exercises sufficient skill in fitting and the patient has the glasses readjusted from time to time.

Bifocal Lenses consist of an upper portion of one focus, and a lower part of another. They are used principally in cases

of *presbyopia associated with ametropia*, the lower portion being used for reading and near work, and the upper for distance. The bifocal lenses most often used are those in which the addition consists of an oval or circular segment cemented to the lower portion of one surface of the distance glass (Figs. 324 and 325). The objections to these are that the Canada balsam used as cement becomes slightly opaque in time, bubbles of air may form, that dirt collects at the edge of the paster, and that the latter often becomes loosened. These objections are overcome by the use of *"invisible bifocals"*; the latter are of two kinds: 1. The *fused bifocal* (*Kryptok*), in which the small reading segment, made of flint glass, is fused into the lower hollowed portion of the larger distance lens (crown glass) (Fig. 326); the increased strength of the smaller lens depends upon the higher refractive index of flint glass; 2. The *onepiece Bifocal* (Ultex), in which both distance and near correction are ground on a single piece of crown glass in toric form (Fig. 327). These forms of bifocals are very neat, but rather expensive compared to the paster variety.



FIG. 326.—Section of Fused Bifocal Lens.

FIG. 327.—Section of Onepiece Bifocal Lens.

Protective Glasses.—To keep out excessive light and ultraviolet rays, lenses used for distance may be tinted, or better, made of *Crookes' glass* which has an imperceptible grey tint (Crookes' A) or a slight grey tint (Crookes' B) and yet, on account of the chemical composition of the glass, has the same effect as smoked glasses, without the disadvantage of altering the color of objects and keeping out visible rays. Or we may order Crookes' B glass or various shades of smoked glasses (Nos. 1 to 6) or of yellow (noviol), green-yellow (chlorophyll, euphos), or amber, to be worn over the distance glasses. Such protection is useful in photophobia in general, in many ocular inflammations, and in guarding against the glare of the sun or the reflection from snow.

CHAPTER XXIV

ANOMALIES OF ACCOMMODATION

Under this heading are included presbyopia, paralysis of accommodation, and spasm of accommodation.

PRESBYOPIA

Presbyopia (*old sight*, Pr.) is a *physiological* change which affects every eye, commencing between the *40th and 45th* years, as a result of which the *near point recedes* beyond the distance at which we read ordinary print; this distance has been fixed somewhat arbitrarily at 22 cm. (about 9 inches). The change is due chiefly to *loss of elasticity of the lens*, preventing a response to the action of the ciliary muscle; consequently the power of *accommodation is lessened*. As explained on page 312, this diminution in the power of accommodation begins early, about the 10th year. Between the 40th and 45th years it becomes sufficient to interfere with the comfortable exercise of near vision; then presbyopia is said to be present.

At the age of 40, there are 4.5 D. of accommodation, and the near point is at 22 cm., or 9 inches. To read at 9 inches, such an individual would require all of his accommodation and the effort would soon become fatiguing, since only one-half or two-thirds of this power can be used for any length of time without causing asthenopia. Generally, however, the adult holds print at about 13 inches (33 cm.), requiring 3 D. of accommodation and leaving a reserve of 1.50 D., usually sufficient for comfort. At 45 his accommodation has diminished to 3.5 D.; all or nearly all of this would be required to read comfortably at 13 inches, leaving little or no reserve. If he keeps one-third of his accommodation in reserve, he will have about 2.25 D. available for near work; with this, his reading distance would be 45 cm., or 18 inches—too great for comfortable and continuous near work. Hence we must sup-

ply the defect in accommodation by a convex lens sufficient to bring the near point to a convenient distance.

Symptoms.—The presbyope is compelled to hold reading, sewing, and other forms of near work *farther* away than the usual distance, making such efforts *uncomfortable.* With recession of the near point beyond the usual situation, the *print becomes pale and indistinct,* and fine type can be read only with great difficulty. The patient is apt to use strong illumination; this produces contraction of the pupil, and thus improves the definition by diminishing the circles of diffusion. If the condition be uncorrected, he suffers from *asthenopic symptoms,* especially pain, fatigue, lacrymation, dimness of vision, and irritation of the lids, all of these symptoms being more marked with poor light or at night with *artificial illumination.* Presbyopia has *no effect upon distant vision.*

Treatment consists in prescribing *convex spherical lenses* for near work so as to compensate for the lack of power of accommodation, and to bring the near point back to a comfortable working distance, about 13 inches.

We can generally prescribe the correcting glasses *according to age.* The rule is to give + 1 D. at 45, and to add 1 D. for every five years; this will bring the near point back to 22 cm., or 9 inches:

Age 45,	glass required	+ 1 D.
" 50,	" "	+ 2 D.
" 55,	" "	+ 3 D.
" 60,	" "	+ 4 D.
" 65 and over	"	+ 4.50 D.

The numbers just given are somewhat *arbitrary;* frequently we will find that a *slightly weaker lens* will be sufficient. The *age* at which patients are obliged to wear glasses *varies* within a few years, and is influenced, to a certain extent, by the vigor of the individual; a delicate or neurasthenic person will require glasses for reading earlier than a robust individual.

The glasses must also be selected with reference to the *occupation* or the *special use* for which the patient wishes them. Thus in reading, writing, and sewing, 13 inches (33 cm.) is a comfortable working distance for most persons; but a musi-

cian may prefer a distance of 20 inches (50 cm.), and consequently he will require a weaker glass.

To find the glass required, we note the patient's near point; then we estimate the lens which represents this point; finally we subtract this number from the lens whose focus corresponds to the distance at which the patient desires to work. For example, suppose the near point has receded to 50 cm. (20 inches); this is represented by a + 2 D. lens ($\frac{100}{50}$ or $\frac{40}{20}$ = 2). We wish to bring the near point to 33 cm. (13 inches), which corresponds to + 3 D. ($\frac{100}{33}$ or $\frac{40}{13}$ = 3). Hence + 2 D. from + 3 D. = + 1 D., the glass required.

The existence of *ametropia* will modify the strength of glasses required for presbyopia. Hence the patient's vision for distance, and the state of his refraction, must be determined before estimating the glasses required for near work. In any case of ametropia the *lenses required for distance must be added* to those which would be selected for presbyopia in the emmetrope. This would have the effect of increasing the strength of the convex lens required for presbyopia in cases of hyperopia, and of diminishing its power in myopia. For example, suppose a patient of 50 has hyperopia of 1.50 D.; his glasses for reading would be H. 1.50+Pr. 2 D. = + 3.50 D. A myope of 2 D. will require no glass at 50, since − 2 D. and + 2 D. (Pr.) neutralize each other. At 55, he would require + 1 D. instead of the usual + 3 D. (− 2 D. + 3 D. = + 1 D.). If the myopia amounts to 5.00 D., the patient will never require glasses for reading, since his far point will always be 20 cm., or 8 inches. In astigmatism, the cylinders must be added to the convex lenses required for the correction of presbyopia.

Since presbyopia increases with age, glasses will require *changing* for stronger ones *every few years*. When glasses have to be changed for stronger lenses very frequently, we suspect *glaucoma* and examine the eye carefully for this disease.

PARALYSIS OF ACCOMMODATION

Paralysis of Accommodation (*Cycloplegia*) is a *partial* (paresis) *or complete* (paralysis) *loss of power in the ciliary muscle*

due to paralysis of the *third nerve*, or of that branch of the motor oculi which supplies the ciliary muscle and iris. Though occasionally confined to the ciliary muscle, the paralysis usually includes the sphincter pupillæ. When limited to the ciliary muscle and iris, it is known as *ophthalmoplegia interna* (p. 367).

Etiology.—The most frequent cause is the use of *mydriatics*. It may be part of a complete paralysis of the *third nerve*. It occurs not infrequently after *diphtheria*. Other causes are *contusions* of the eyeball, debilitated states of the system, grippe, syphilis, diabetes, and cerebral disease.

Symptoms.—These are *loss of power of accommodation* and *dilatation of the pupil*. If emmetropic, the patient will have good vision for distance, but will be unable to do near work without convex glasses. If hyperopic, both near and distant vision will be impaired. If myopic, the patient will be able to see only at his far point; he may therefore be able to do without his accommodation, if the myopia is considerable.

Prognosis is usually *good*, especially when the affection is due to syphilis or diphtheria. In traumatic cases the condition may be permanent.

Treatment.—We attempt to *remove the cause:* In syphilis, *specific treatment* is indicated. In post-diphtheritic paralysis, and in that due to debilitated conditions, tonics are given, especially *strychnine*. Locally, the *miotics* (eserine or pilocarpine) are employed. These cause contraction of the pupil and of the ciliary muscle, producing spasm of accommodation, and temporarily relieve the symptoms; the alternate contraction and relaxation of the ciliary muscle often stimulate it to action. The local application of electricity is sometimes useful. In traumatic cases, complete rest is indicated, in addition to the remedies just mentioned. If the paralysis has lasted some time, *convex glasses* may be given for near work.

SPASM OF ACCOMMODATION

Tonic spasm of the ciliary muscle is frequently met with in *children* and in *young adults;* it occurs generally in *hyperopia*, but it may accompany E. or any error of refraction.

Etiology.—It is usually due to long-continued application of the eyes for near work, especially when the young patient is in poor health, has uncorrected ametropia, and the work has been excessive and done with poor illumination.

Symptoms.—*Both eyes* are usually affected. There are *asthenopia* and *diminished acuteness of vision.* In emmetropia, the spasm gives rise to the signs of myopia; in hyperopia, it reduces the amount of manifest error and increases the proportion of latent hyperopia, or it may even cause the patient to appear myopic; in myopia the error is increased. The diagnosis is made after instilling a cycloplegic; in some of these cases homatropine is insufficient and *atropine* must be used.

Treatment consists in the *abstinence* from near work, the *correction of ametropia*, attention to the *general health*, and the production of paralysis of accommodation for a few days or weeks by instillations of *atropine.*

CHAPTER XXV

DISTURBANCES OF MOTILITY OF THE EYE

Anatomy and Physiology.—The eyeball is moved by six muscles, the *extrinsic muscles*, consisting of the four straight and the two oblique; these arise from the wall of the orbit and are inserted into the sclera.

The Recti (*internal, external, superior, inferior*) arise from the circumference of the optic foramen at the apex of the orbit, run forward surrounding the optic nerve and posterior portion of the eyeball, and are inserted into the sclera by means of flattened tendons about 10 mm. wide. The lines of insertion of these muscles are not equidistant from the cornea, but have somewhat the form of a spiral; that of the internal rectus is 5 mm., of the inferior rectus 6 mm., of the external rectus 7 mm., and of the superior rectus 8 mm., from the cornea.

The Superior Oblique arises from the border of the optic foramen, runs forward to the upper and inner angle of the orbit, at the anterior extremity of which it passes through a fibrous pulley; it then continues outward and backward, passing beneath the superior rectus, and is inserted into the upper part of the sclera behind the equator. *The Inferior Oblique* arises from the superior maxillary bone at the inner portion of the lower border of the orbit, passes outward below the inferior rectus, and is inserted into the outer part of the sclera behind the equator.

The muscles are ensheathed by the fascia of the orbit, *Tenon's capsule*, which also covers the sclera and sends prolongations to the walls of the orbit which serve to fix the eyeball in its place. These prolongations are most prominent upon the internal and external recti muscles; they serve to restrain the excursions of the eyeball and are known as "*check ligaments.*"

Nerve Supply.—The *third* nerve (oculomotor) supplies all the muscles except the external rectus, innervated by the *sixth* (abducens), and the superior oblique, which is supplied by the *fourth* (trochlearis). The nuclei for these three nerves are found in the floor of the fourth ventricle.

Action of the Muscles.—The six extrinsic muscles serve to rotate the eyeball around a *vertical, transverse, and antero-posterior axis*, the centre of rotation corresponding approximately to the centre of the eyeball, and the movements being free in all directions, like a ball-and-socket joint. The movements which take place about the vertical axis are *adduction* (toward the nose) and *abduction* (toward the temple); about the transverse axis, *elevation* and *depression;* and about the antero-

posterior axis, *wheel rotation or torsion*, causing the upper end of the vertical meridian to be inclined inward or outward.

The External Rectus moves the eyeball outward.

The Internal Rectus moves the eyeball inward.

The Superior Rectus moves the eyeball upward, inward, and turns the upper extremity of the vertical meridian inward.

The Inferior Rectus moves the eyeball downward, inward, and turns the upper end of the vertical meridian outward.

The Superior Oblique rotates the upper end of the vertical meridian inward, and moves the eyeball downward and outward.

The Inferior Oblique rotates the upper end of the vertical meridian outward, and moves the eyeball upward and outward.

Except in the case of the internal and external rectus, none of the muscles has a simple action. Each of the other muscles —the elevators and depressors—has a *main action* and also certain *subsidiary actions*. The main action (elevation and depression) of the superior and inferior recti increases as the eye is abducted, and that of the obliques increases as the eye is adducted.

The Field of Action of a muscle is that direction of gaze in which its main action is greatest. In every movement of the eyes *several muscles of each eye act at the same time;* but on moving them in any of the six cardinal directions of gaze (see below), there is always *one muscle of each eye acting predominantly in that direction;* this is the muscle in whose field of action the eye is placed. Duane gives the following table of the field of action of the various muscles:

	Eyes Directed to	*Muscle Predominantly Acting*	
Cardinal Directions of Gaze	Right	R. External Rectus	L. Internal Rectus
	Left	R. Internal Rectus	L. External Rectus
	Up and Right	R. Superior Rectus	L. Inferior Oblique
	Up and Left	R. Inferior Oblique	L. Superior Rectus
	Down and Right	R. Inferior Rectus	L. Superior Oblique
	Down and Left	R. Superior Oblique	L. Inferior Rectus

Both eyes always move simultaneously (*associated movements*), regulated by centres of association which innervate certain muscles or groups of muscles of the two eyes simultaneously. The associate or conjugate movements occur either in the same direction, with the *visual lines parallel*, or with the lines inclined toward each other (*convergence*).

The Field of Fixation corresponds to the *limits* of movement of the eyeball *in different directions*, without moving the head. It is best estimated by the perimeter (Fig. 19). The patient's head is fixed so that the eye under examination is opposite the centre of the instrument, and the other eye covered. A short word printed with small test-letters is moved along the arc of the perimeter, from the periphery to the centre, until the patient can name the word, using the eye alone and not moving the head. The field of fixation in the normal eye is about 45° upward, inward, and outward, and about 60° downward. A special instrument (Stevens' Tropometer) may be used for the determination of the rotations of the eyes.

Binocular Vision and Diplopia.—Under ordinary conditions, both eyes are concerned in the act of vision, and are involuntarily adjusted, so that the image of an object is focussed on the macula of each eye. The two images are then fused into a single mental perception. This faculty constitutes *binocular single vision*, and is controlled by the sense of *fusion*, the origin of the impulse being the fusion centre of the brain.

When images fall on symmetrical points of the two retinæ, a single visual sensation is produced (*binocular single vision*). When the visual lines of the two eyes are not directed toward the same object, *i.e.*, when one eye deviates, *diplopia or double images* result, unless the image of the deviating eye is suppressed. The diplopia is proportional to the amount of deviation. The image which corresponds to the eye which "fixes" the object is distinct, because it lies at the macula, and is known as the *true image;* the image of the deviating eye is less distinct, because it is perceived by a peripheral part of the retina, and is known as the *false image.*

Objects situated to the right of the point of fixation throw their images to the left of the macula; those placed to the left of the point of fixation form images to the right of the macula. In the same manner objects above or below the point of fixation cast their images below or above the macula respectively. By reversing this process we judge of the situation of an object, and place it at the extremity of an imaginary line drawn from the retinal image through the nodal point; this process is

known as *projection*, and is learned by experience. It enables us to judge of the relative positions of objects; an object which forms its image to the right of the macula is situated to our left; one which throws its image below the macula is situated above, etc.

If an eye is deflected, an object situated straight ahead will form its image on either side of the macula, and following out this process of projection, it will be referred to the opposite side of the outside world.

Diplopia is said to be *homonymous* when the false image is on the same side as the deviating eye, and *crossed* when it is on the opposite side. When the two images are level, the diplopia is known as *horizontal;* when displaced vertically, the diplopia is called *vertical.*

In Fig. 328, the right eye is turned in, and diplopia results. The patient sees a true image with the left eye, forming at the

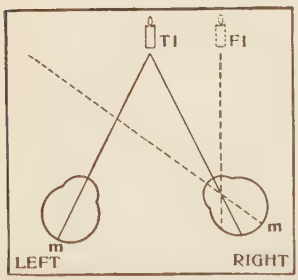

FIG. 328.—Deviation of the Right Eye Inward. Homonymous Diplopia. *TI*, True Image; *FI*, False Image; *m*, Macula.

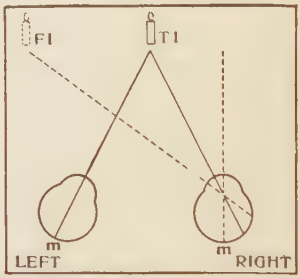

FIG. 329.—Deviation of the Right Eye Outward. Crossed Diplopia. *TI*, True Image; *FI*, False Image; *m*, Macula.

macula and referred to its proper place, *T I*. In the right eye on account of the deviation inward, the image is thrown upon the retina to the left of the macula and consequently is projected to the right, at *F I*. The image of the right eye being to the right of the image of the left eye, the case is one of *homonymous double images.*

In Fig. 329, the right eye turns out and diplopia results. The image of the candle lies on the macula in the left eye and is referred to its correct position; a true image is seen at *T I*. In the right eye, because of its outward deviation, the image

falls to the right of the macula and is consequently projected to the left, at *F I*. The images having crossed in their relative positions, that of the right eye being seen to the left of the image of the left eye, the case is one of *crossed diplopia.*

Double images may also be produced without any deviation by placing a *prism* in front of the eyes. The prism will deflect the rays so that instead of falling upon the macula, they reach the retina to one side of it.

Varieties of Ocular Deviations.—A deviation may be

1. *Paralytic,* or
2. *Non-paralytic.*

1. In *Paralysis,* the deviation is due to a loss of function of one or more of the ocular muscles; the paralysis may be (a) *complete* or (b) *partial* (paresis).

2. *Non-paralytic* (*concomitant*) deviations are produced by anomalies of the power of convergence and of divergence. In these cases the amount and character of the deviation does not vary in the different directions of gaze since we can converge or diverge our eyes with the same facility on looking to the right as on looking to the left. Such deviations may be (a) *manifest,* and (b) *latent.*

a. *Strabismus* (*Squint* or *Heterotropia*) is a *manifest* deviation in which binocular fixation is impossible. Fixation is maintained with one eye or the other but never with both at the same time.

b. *Heterophoria* is a condition in which the eyes have a constant *tendency* to deviate, but are forced into simultaneous fixation by muscular effort prompted by the desire for binocular single vision. Ordinarily the deviation is not apparent, hence it is said to be *latent.*

There is no sharp distinction beyween heterophoria and squint; frequently a heterophoria progresses until the patient is no longer able to overcome the deviation and it then becomes manifest (squint).

PARALYSIS OF THE OCULAR MUSCLES

Symptoms.—1. *Limitation of Movement* of the eye in the field of action of the paralyzed muscle; this is pronounced

in complete paralysis and less marked in paresis. It can usually be detected when the patient keeps his head fixed and tries to follow with his eyes an object moved in the six cardinal directions of gaze (excursion test). The limitation of movement may be so slight that the diagnosis must be made from the nature of the diplopia.

2. *Paralytic Squint.* When the eyes are turned in the field of action of the paralyzed muscle, the sound eye will be directed properly, but the affected eye will refuse to move, and will squint. The deviation is generally apparent, but becomes more marked the farther the eyes are moved in the field of action of the paralyzed muscle. When the eyes are turned in any direction in which the paralyzed muscle does not have to participate, there is no squint.

The deflection of the squinting eye is known as the *primary deviation;* it is always in the direction opposite to the normal action of the paralyzed muscle. If the affected eye be made to fix an object and the sound eye be covered, the latter will squint in a corresponding direction, and much more than the affected eye; this deflection of the sound eye is known as the *secondary deviation.* The excess of secondary deviation over the primary is due to the fact that the strong impulse of innervation required to enable the paralyzed eye to fix, being simultaneously transmitted to the associated muscle of the sound eye, produces an overaction of this muscle, and consequently a greater amount of squint. This is an important point in distinguishing between paralytic and non-paralytic (concomitant) squint; in the latter, the primary and secondary deviations are equal.

3. *Diplopia* occurs in the *field of action of the paralyzed muscle* and becomes more marked as the eyes are moved into this field. The presence or absence of diplopia, the relative position of the double images, and the increase or diminution of the distance between them in the six cardinal directions of gaze, form the most important means of diagnosing an ocular muscle paralysis.

4. *Head Tilting.* The patient usually turns his head in the direction of action of the paralyzed muscle. The oblique

position of the head is a suggestive but not a diagnostic sign.

5. *False Projection.* The paralyzed eye does not see objects in their correct location. The false projection is due to markedly increased innervation, conveyed to the nerve supplying the paralyzed muscle in an effort to force it to act; this gives the patient an erroneous idea of the position of the eye. It can be demonstrated by closing the patient's sound eye and telling him to point quickly at an object in front of him; the finger will be directed to the side of the object corresponding to the paralyzed muscle.

6. *Vertigo, nausea,* and *uncertain gait* are frequent symptoms due to the diplopia and the false projection; they are relieved by closing the paralyzed eye.

Diagnosis: The limitation of movement, the squint and the diplopia are the three important symptoms of ocular paralysis. All of these symptoms increase in the field of action of the paralyzed muscle. In the paretic cases, where the limitation of motion and squint are slight in amount, the behavior of the diplopia is most important.

Method of Testing for Diplopia: The patient is seated facing a wall at a distance of 30 inches from it. A *red glass* is placed before the right eye, and the head and body are kept still. A small electric light (May Electric Ophthalmoscope with the lens-disc removed) or a lighted candle is moved in the six directions of gaze and the nature and amount of diplopia noted in each field. The data required are: (1) in which direction of gaze there is single vision and in which diplopia; (2) whether the diplopia is homonymous, crossed, vertical, or mixed; (3) whether the diplopia increases in any direction of gaze. A rule which is helpful in interpretation of diplopia is: The image of the paralyzed eye always lies on the side towards which the diplopia increases, and the diplopia always increases in the field of action of the paralyzed muscle. Knowing the direction in which the diplopia increases and which is the affected eye, it is possible to determine the particular muscle involved. The diplopia field can be most satisfactorily determined by the use of the special tangent plane of Duane.

After a paralysis has lasted a long time the symptoms become less characteristic. Diplopia disappears because the image of the paralyzed eye is *suppressed* and faulty projection is corrected by newly acquired experience; *contracture* of the antagonist of the affected muscle increases the squint.

When one muscle only is paralyzed, the diagnosis is easy; but when several muscles are involved, it is sometimes difficult to determine the exact combination.

Varieties of Ocular Paralysis.—One muscle may be involved or several muscles may be affected. Paralysis of the external rectus is the most common acquired paralysis of a single muscle; less frequently the superior oblique or one of the muscles supplied by the third nerve is affected. Combined paralysis of some or all of the four muscles supplied by the third nerve is exceedingly common.

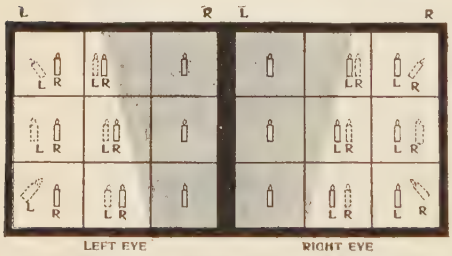

FIG. 330.—Paralysis of the External Rectus (the dotted outline refers to the false image).

Paralysis of the External Rectus (Sixth Nerve).—There is limitation of movement outward, convergent squint, and homonymous diplopia. All of these symptoms increase as the affected eye is abducted. The images are on the same level; the lateral separation increases as the paralyzed eye attempts to move out (Fig. 330).

Paralysis of the Internal Rectus.—There is limitation of movement inward, divergent squint, and crossed diplopia. All of these symptoms increase as the affected eye is adducted. The images are on the same level; the lateral separation increases as the paralyzed eye attempts to move in (Fig. 331).

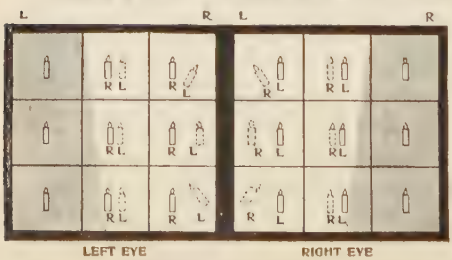

FIG. 331.—Paralysis of the Internal Rectus (the dotted outline refers to the false image).

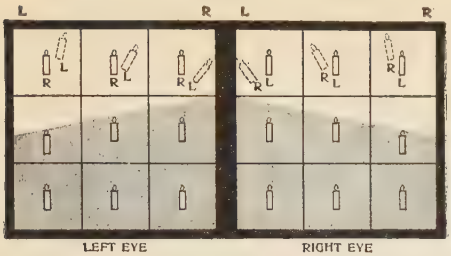

FIG. 332.—Paralysis of the Superior Rectus (the dotted outline refers to the false image).

Paralysis of the Superior Rectus.—There is limitation of movement upward (most pronounced in the upper outer field), vertical squint and mixed diplopia. The diplopia is mainly vertical but usually also slightly crossed. The image of the paralyzed eye is higher and the vertical separation of the images increases as the affected eye attempts to move up and out; the intorsion of the false image and the crossed diplopia increase in the upper nasal field (Fig. 332).

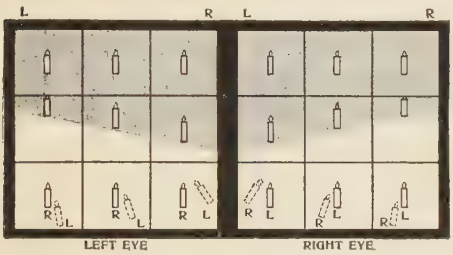

FIG. 333.—Paralysis of the Inferior Rectus (the dotted outline refers to the false image).

Paralysis of the Inferior Rectus.—There is limitation of movement downward (most pronounced in the lower outer field), vertical squint and mixed diplopia. The diplopia is mainly vertical but usually is also crossed. The image of the paralyzed eye is lower and the vertical separation of the images increases as the affected eye attempts to move down and out; the extorsion of the false image and crossed diplopia increase in the lower nasal field (Fig. 333).

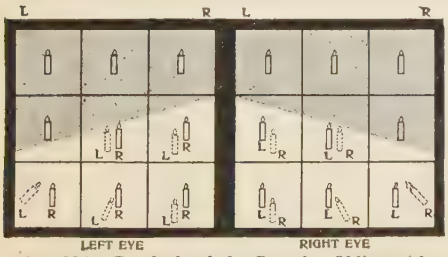

FIG. 334.—Paralysis of the Superior Oblique (the dotted outline refers to the false image).

Paralysis of the Superior Oblique.—There is limitation of movement downward (most pronounced in the lower nasal field), vertical squint and mixed diplopia. The diplopia is chiefly vertical but usually is also homonymous. The image of the paralyzed eye is lower and the vertical separation of the images increases in its lower nasal field; the intorsion of the false image and homonymous diplopia increase in its lower temporal field (Fig. 334).

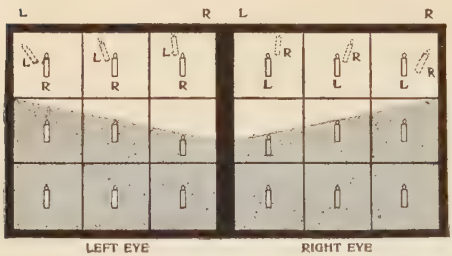

FIG. 335.—Paralysis of the Inferior Oblique (the dotted outline refers to the false image).

Paralysis of the Inferior Oblique.—There is limitation of movement upward (most pronounced in the upper nasal field), vertical squint and mixed diplopia. The diplopia is mainly vertical but usually is homonymous. The image of the paralyzed eye is higher and the vertical separation of the images increases in its upper nasal field; the extorsion of the false image and homonymous diplopia increase in its upper temporal field (Fig. 335).

Paralysis of the Third Nerve.—With complete paralysis of this nerve there is *ptosis;* the *eyeball is almost immobile,* the limitation of motion being upward, inward and slightly downward; the eye *deviates outward* and somewhat downward, with the upper end of the vertical meridian inclined inward, especially on looking downward; the face is directed upward and toward the sound side, and the head inclined to the shoulder of the paralyzed side. There is slight exophthalmos due to paralysis of the three recti which normally draw the eyeball backward; the *pupil* is *dilated* and is *immobile; accommodation* is *paralyzed;* there is crossed *diplopia*—the false image is higher, and its upper end inclined toward the paralyzed side.

Paralysis of the third nerve is *common;* it is often incomplete, two or three of the muscles being affected. It may be associated with paralysis of other nerves.

When all the muscles of one eye are paralyzed, including the iris and ciliary body, the condition is known as *total ophthalmoplegia.*

When all the exterior muscles of the eyeball are paralyzed, but not the iris and ciliary body, the condition is known as *external ophthalmoplegia;* this variety is more common than total ophthalmoplegia; the nuclei for the sphincter pupillae and ciliary muscle being separate, they often escape involvement of the lesions affecting the origin of the exterior ocular muscles; this form is generally of central (nuclear) origin.

Paralysis limited to the sphincter pupillae and the ciliary muscle is known as *internal ophthalmoplegia* (p. 355).

Etiology.—The lesions causing paralysis may be situated anywhere in the course of the nerve tract, from the cerebral cortex to the muscle. According to its site, the lesion is distinguished as *central and peripheral.*

Central lesions may be situated in the *cortical* centres, the *association* centres, the *nuclei* of origin, or in the fibres which connect these centres. Lesions occurring above the nuclei do not produce an individual muscle paralysis but a paralysis of the conjugate movements (*conjugate paralysis*). *Nuclear* paralysis usually involves more than one muscle and as a rule is bilateral.

Peripheral lesions affect the nerves in some part of their course, either between the point where they issue from the brain and their entrance into the orbit (*basilar* paralysis), or in the nerve or its branches in the orbit (*orbital* paralysis). Peripheral lesions are usually complete and unilateral.

The Nature of the Lesion.—The lesion may be a neighboring exudation, hemorrhage, periostitis, tumor, injury or vascular change, causing compression or inflammation of the nerves; less frequently primary inflammation or degeneration.

The most common cause is *syphilis* (late symptom) which is responsible for one-half the cases. Epidemic *encephalitis* is another frequent cause. Muscle paralyses occur in various central nervous system diseases (*tabes*, general paralysis, disseminated sclerosis, etc.); after acute infectious diseases (*diphtheria*, influenza, etc.); in intestinal intoxication; in acute poisonings (alcohol, ptomaine, botulism, etc.); in diabetes; in *rheumatism;* in exophthalmic goitre; accompanying *accessory sinus disease;* and after injuries.

Congenital paralyses are not uncommon, due to absence, abnormal insertion, or other structural defects of the muscles themselves. Congenital abnormalities most often affect the external rectus and the superior rectus.

Course.—The onset may be sudden or gradual. The course is always *chronic* and even in favorable cases, six weeks or more are required to effect a cure. *Relapses* are not in-

frequent. The prognosis depends upon the cause. After existing a long time the prognosis becomes less favorable on account of secondary changes (atrophy of the paralyzed muscle and contraction of the antagonist).

Treatment should be *directed to the cause.* In syphilis energetic specific treatment (iodides, mercury, salvarsan) is indicated; in rheumatism, salicylates and aspirin; in diphtheria, strychnine; and in obscure cases potassium iodide with or without mercury is usually resorted to.

Symptomatic treatment consists in relief of the diplopia. Prisms are rarely successful because even in slight paralysis the diplopia changes in amount in whatever direction the eye is moved. The only satisfactory way to avoid double vision is to *occlude the deviating eye* by a patch or by a ground glass in a spectacle frame.

If the condition persists for a long time in spite of all treatment, and the paralysis seems incurable, *operative treatment* is indicated. This consists in a resection or advancement of the paralyzed muscle combined, in many cases, with a tenotomy of the antagonist; the results of this operation are often disappointing but the cosmetic improvement may be satisfactory.

Spasm of the Ocular Muscles is due to excessive innervation; it may be primary or secondary. *Primary Spasm* is rare; it may be produced by meningeal or by reflex irritation. *Secondary Spasm* is common and occurs with paralysis of one of the other ocular muscles, presenting excessive movement in the field of action of the spastic muscle and spastic deviation of that eye; it appears frequently in the direct antagonist of a paralyzed muscle, *e.g.*, spasm of the internal rectus following paralysis of the external rectus of the same eye; where the paralyzed eye is used for fixation, there is often a secondary spasmodic deviation of the other eye due to spasm of the associate of the paralyzed muscle; the most common example of this type of deviation occurs in paralysis of the superior rectus followed by a spasm of the inferior oblique of the other eye. The treatment of secondary spasms is operative, *i.e.*, tenotomy to weaken the action of the overactive muscle.

CONCOMITANT STRABISMUS

Concomitant strabismus (*Concomitant Squint or Heterotropia*) is a *manifest deviation* of the visual line of one eye, the two eyes maintaining the same faulty relationship of axes in every direction in which they are turned. The power of the different muscles of the two eyes is usually normal, and the squinting eye follows the other in all its movements, always deviating from the correct position to the same extent. The eye which is directed toward the object looked at, is known as the *fixing eye*, the other as the *squinting eye.*

Concomitant strabismus differs from heterophoria as explained on p. 370. It is distinguished from paralytic squint by presenting a *normal range of movement* of each eye and the *same deviation* in all parts of the visual field, while in paralysis the deviation is present only in the field of action of the paralyzed muscle and there is limitation of movement in a certain direction; in concomitant squint the *primary and secondary deviations are equal*, while in paralytic squint the secondary deviation is greater than the primary; diplopia, a prominent symptom in paralytic squint, is seldom present in concomitant squint.

Varieties.—Concomitant squint may be

1. *Constant*, if present all the time.

2. *Periodic*, if under the same visual conditions it is present sometimes and absent at others.

3. *Intermittent*, if greater for near than for distance, and vice versa; *continuous*, if equal in amount for both distance and near.

4. *Monocular*, when one eye constantly deviates, the other being used habitually for fixation.

5. *Alternating*, when the patient fixes with either eye indifferently, or one eye fixes for distance and the other for near.

According to the *direction of deviation*, concomitant squint is classified into

(1) *Convergent* strabismus (Internal squint, Esotropia).

(2) *Divergent* strabismus (External squint, Exotropia).

(3) *Vertical* strabismus (Strabismus Sursum Vergens, when

upward; and Deorsum Vergens, when downward; Hypertropia, right or left, according to the higher eye).

(4) *Mixed* strabismus, a combination of a vertical and a lateral squint.

Diagnosis.—This can usually be made by inspection, but in slight cases this cannot be depended upon. The *binocular uncovering test* affords a simple method of differentiating between a heterophoria and a squint: The patient fixes a test object and one eye is alternately covered and uncovered leaving the other uncovered all the time; we notice carefully the movement, if any, of each eye: In heterophoria, when one eye is covered it deviates and on removing the screen it swings back into place to take up fixation with the other eye which has remained fixing; movement occurs only in the eye covered and uncovered. If the deviation is a squint and the squinting eye is covered and uncovered, no movement of either eye occurs; but when the fixing eye is covered and uncovered both eyes move.

The Measurement of Squint.—The amount of deviation present can be measured (1) by the screen test, (2) by the perimeter, and (3) by the corneal reflex test.

1. *The Screen Test* can not be used where there is loss of power of fixation in one eye; in all others it is our most accurate method: With the patient fixing an object, a card is placed before one eye and then passed quickly to and fro from one eye to the other. The card is so passed that the patient has no chance to fix with both eyes at the same time but must alternate his fixation. Each eye when covered deviates, and when uncovered turns back into the fixing position. A prism (apex in for internal squint, apex out for external squint) of sufficient strength to abolish this movement of correction represents the exact amount of deviation present. It is often more accurate in estimating the amount, to deduct 2° from the weakest over-correcting prism. This test is usually done both at 20 feet and at 13 inches and the amount of deviation noted at both distances.

2. *The Perimeter* (Fig. 19) gives the *angular measurement* of squint: The patient is seated with the squinting eye in the

centre of the instrument and is directed to fix a distant object placed in the median line, with both eyes; a lighted candle is now moved along the inside of the arc from the centre outward until its reflection on the cornea is seen in the centre of the pupil of the squinting eye; the number of degrees on the arc at this point indicates the size of strabismus angle.

3. *The Corneal Reflex Test* (Hirschberg) also measures the amount of squint in the degrees of arc. The patient looks at a lighted candle held one foot in front of the eyes. The examiner, placed directly behind the light, notes the position of its reflection on the cornea of the squinting eye. If it is at the margin of the cornea it represents a squint of 6mm. (about 45 degrees of arc); every mm. of deviation represents approximately seven degrees of arc of squint.

Symptoms.—The *disfigurement* is the symptom which usually leads the patient to consult an oculist. There is *no diplopia* except in the very early stages, the double images soon disappearing owing to a psychical process of *suppression* of the image of the squinting eye. There is usually *diminution in the acuity of vision* of the deviating eye (except in alternating squint). This may or may not have existed previous to the development of strabismus; in either case, it increases with the duration of the squint from disuse (*amblyopia ex anopsia*), and may become very pronounced. There are no asthenopic symptoms.

Etiology.—Concomitant squint usually results from a *disproportion in strength between the power of convergence and the power of divergence.* To converge the eyes there must be a simultaneous and equal contraction of both internal recti, causing an equal movement inward of each eye. Divergence is affected through a relaxation of both internal recti. Divergence and convergence oppose each other; an overaction of one of them leads to a subsequent weakening of the other and vice versa.

Most concomitant squints start as an anomaly of one of these powers, but both soon become involved. A *disturbance in the normal balance* between convergence and divergence

may be (1) accommodative, or (2) non-accommodative in origin:

The *accommodative squints* are those in which the normal relation between convergence and accommodation has been disturbed by *errors of refraction*, including anisometropia, or as the result of *impaired vision* in one eye due to opacities of the media, etc.

The *non-accommodative* cases comprise those in which no refractive error can be found to explain the imbalance. All anomalies of the power of divergence are non-accommodative in origin.

Worth and many others believe that a *defect of the fusion faculty* is an important factor in producing squint. The fusion faculty begins to develop early in life and is complete before the sixth year; this establishes a desire for binocular vision which keeps the eyes straight. "Sometimes however, owing to a congenital defect, the fusion faculty develops later than it should, or it develops imperfectly, or it may never develop at all. Then there is nothing but the motor co-ordinations to preserve the normal relative directions of the eyes, and anything which disturbs the balance of these co-ordinations will cause a permanent squint" (Worth).

CONVERGENT CONCOMITANT STRABISMUS

In this form of squint (esotropia) there is *deviation inward* of the visual line of one eye (Fig. 336). It is generally associated with *hyperopia*, with or without hyperopic astigmatism; rarely it occurs in myopia and in emmetropia. It usually commences in *early life*, between the *first and fourth years*, when the child begins to use his accommodation for near objects, such as toys and pictures; rarely it is congenital. At first the squint may be noticed only at times (periodic), with near vision, or when there is any interference with the general health; but it is apt to become constant for both near and distant vision; occasionally it disappears at about the age of puberty.

FIG. 336.—Convergent Strabismus.

The *acuteness of vision* in the squinting eye often presents considerable *reduction*, and there may be marked *amblyopia*. Whether the squint precedes and is the cause of the amblyopia, or whether the amblyopia is originally present and is the cause of the squint, is one of the unsettled questions in ophthalmology; probably in most instances the amblyopia is acquired *from disuse* of the squinting eye.

Development.—A child who is hyperopic must use some accommodation for distance and more for near vision. *Accommodation and convergence* being *associated*, he must increase his convergence with increase of accommodation. In looking at a near object, the stimulus to converge corresponds not only to the amount present in the emmetrope, but includes an additional and abnormal amount called for by the extra accommodation required to compensate for his hyperopia. At first the child shows a spasmodic esophoria for near, due to the overstimulation of convergence; little by little the deviation increases until binocular fixation for near is impossible and he develops a squint at close range, along with which will be a slight esophoria for distance; then as time goes on, the deviation becomes manifest for both distance and near; in other words he develops a secondary weakening of his power of divergence. Exceptionally an esotropia begins as a primary squint for distance, due to a divergence insufficiency, with the later development of secondary excess of convergence.

Treatment comprises (1) the correction of refractive errors by glasses, (2) exercise of the squinting eye by occluding its fellow, (3) instillation of atropine, (4) the training of the fusion sense (orthoptic training), and (5) operation.

Non-Operative Treatment.—The *error of refraction* should be estimated under *homatropine or atropine*, and convex *glasses* correcting very nearly the total hyperopia (also the astigmatism, if present) prescribed for *constant wear*. In slight cases, especially if periodic, this sometimes effects a cure. Glasses may be worn by children of two years and upward. It is sometimes advisable to keep the eyes under the influence of atropine for a week when the glasses are first worn.

The fixing eye should be covered by a *patch or bandage* for one hour, three times a day, or the occlusion may be continuous. This compels the squinting eye to fix, *exercises* it, prevents amblyopia from disuse, and restores, as far as possible, the sight of the deviating eye if amblyopia already exists.

Atropine should be instilled into the *fixing eye* so that the latter cannot be used for near vision, thus compelling the child to employ the squinting eye for seeing close objects. One drop of a 1-per-cent. solution or ointment is used every morning; this practice, if kept up too long, may result in amblyopia of the eye originally used for fixation.

Orthoptic Training of binocular perception and the sense of fusion may be undertaken with *stereoscopes*, but most successfully with the *amblyoscope* (Fig. 337).

This instrument consists of two brass tubes joined by a hinge, each provided with a mirror and a convex lens. The object-slides are devices



Fig. 337.—Worth's Amblyoscope.

drawn on translucent paper gummed on glass, or printed on celluloid squares (Fig. 338). The two halves of the instrument can be brought together to suit a convergence up to 60°, or separated to suit a divergence of 30°. Each object-slide is lighted by a separate electric lamp, the brilliancy of which can be regulated, thus increasing or diminishing the illumination of either of the pictures.

The *Amblyoscope* is used as follows: The instrument is adapted roughly to the angle of the child's squint and the exercises are begun by an attempt to develop *simultaneous perception*, by increasing the illumination before the squinting



FIG. 338.—Object-slides used with Worth's Amblyoscope.

eye and adjusting the relative brilliancy of the lights, until the objects of both slides are seen simultaneously; then the child is taught to *fuse* the images; finally the amplitude of fusion is increased, and the *sense of perspective* taught.

Non-operative treatment is successful in a large proportion of cases of convergent concomitant squint, *if used sufficiently early*. The earlier such treatment is begun, the better the results; after the sixth year it is not usually effective.

Operative Treatment.—If non-operative measures do not overcome the deviation after a thorough trial, *operation* is indicated.

It is advisable to postpone operation until the child is old enough to allow local anaesthesia (*seventh year* or later) and thus to aid by its cooperation; under such circumstances, the results are more certain, since over-correction or under-correction can be avoided or remedied immediately. There are, however, some operators who advocate straightening the eye at an earlier period under general anaesthesia, desiring to remove the disfigurement and the effects which it often has upon the child's disposition, as early as possible; such surgeons then depend upon a subsequent operation, when the child is older, in case an imperfect result has to be repaired.

The operations used are a *tenotomy* of the internal rectus or an *advancement* (or *shortening*) of the external rectus. They may be done singly or in combination.

The choice of operation depends upon the amount of squint present for distance and for near, the lateral excursions for

both eyes, and the near point of convergence. Careful examination is necessary before deciding this question. As a rule, advancement (or resection) of one or both external rectus muscles, with or without a guarded tenotomy of the internus, is the operation of choice. If the squint is marked (more than 30 degrees), and present for both distance and near, a combination of the two operations is indicated. In the infrequent cases in which the squint is present only for near, the tenotomy of the internal rectus is required; when the squint exists only for distance, an advancement or resection of the external rectus is called for. These operations are done first on the squinting eye and subsequently, if necessary, on the other eye; they may be done on both eyes at the same time. The rules given above presuppose that the patient is wearing full correction.

DIVERGENT CONCOMITANT STRABISMUS

This form of squint (exotropia) exists when one eye fixes an object and the other *deviates outward* (Fig. 339). It is often associated with *myopia*, but may occur with hyperopia. It occurs frequently after the *loss of useful vision in one eye*, the sight of the other eye remaining good; here the incentive to converge is destroyed and the eyes assume the position of rest, viz.—one of divergence. It is sometimes met with after tenotomies performed for the cure of internal squint. Divergent strabismus does not usually become manifest in early childhood, but usually *develops in youth* or early adult life. It is much less frequent than convergent squint.



FIG. 339.—Divergent Strabismus.

Development.—These cases start either as (1) insufficiency of convergence or (2) excess of divergence.

Some cases of concomitant divergent strabismus start as a *weakness of convergence* due to myopia. In nearsightedness, little or no accommodation is needed for near vision; consequently there is an habitual deficiency of the stimulus

for convergence; this power, therefore, weakens and the patient has a deviation at close range but none at a distance; there is then a gradual increase in the amount of deviation, until it is present at all distances.

On the other hand, *divergence excess* is common as a primary condition, and as such at first shows a divergence only at a distance; but as time goes on the power of convergence weakens and the deviation persists for both distance and near. This type of deviation is found independently of the refractive error which is usually low in amount and hyperopic in character.

Treatment.—The *full correction* of any existing myopia is indicated; this will correct those cases due to an uncorrected myopia, where the deviation is still periodic. *Operation* is required in all other cases. Complete *tenotomy of the external rectus* is the operation of choice where the deviation is present only at distance; this can be done on one eye or on both, according to the amount of deviation present. In all cases where the converging power is markedly weakened, an *advancement* (or resection) of one or both internal recti should be done. A deviation which is continuous and equal in amount both at 20 feet and at 13 inches should have a combination of these operations performed on one or both eyes.

HETEROPHORIA

Heterophoria is a *latent deviation* in which the eyes have a *constant tendency to deviate.* This deviation is *overcome by muscular effort* because of the strong desire to maintain binocular single vision. In concomitant strabismus the deviation is manifest and cannot be overcome by increased innervation. As the same etiological factors produce both conditions, heterophoria and squint are differentiated solely by the patient's ability to overcome or to not overcome the deviation. A deviation therefore, may be a heterophoria on one examination and a squint on the next, or vice versa.

Varieties.—When a normal person fixes an object, both eyes are directed at that object under all conditions. This

condition of perfect muscle balance is known as *orthophoria*. The varieties of imperfect muscle balance (heterophoria) are:

1. *Exophoria*, a tendency to deviate *outward*.
2. *Esophoria*, a tendency to deviate *inward*.
3. *Hyperphoria*, a tendency of one eye to deviate *upward; right* hyperphoria when the right eye tends to deviate upward; *left* hyperphoria when the left eye tends to deviate upward. This variety may be associated with exophoria or esophoria.

Cyclophoria, a tendency of the vertical meridian of one eye to deviate from the vertical position.

Tests.—Some of the tests are used both at 20 feet and at 13 inches, since we must know the state of muscular balance or imbalance at both of these distances in order to make a definite diagnosis.

A candle flame or a small electric light (May Electric Ophthalmoscope with head and cap removed) is a satisfactory test object. When the eyes are in a state of *perfect balance*, there is orthophoria for distance (1° to 2° of either esophoria or exophoria are also considered normal), a normal prism divergence, a slight exophoria (2° to 4°) for near, a normal near point of convergence, and normal motility in all fields.

The *amount* of heterophoria present for both distance and near can be satisfactorily determined by the use of (1) the screen and parallax test, (2) the Maddox rod, and (3) the phorometer.

The Screen and Parallax Test.—This is a combination of the objective screen test and the subjective parallax test. It is done exactly as described on p. 370, except that in addition to the observer noting the direction in which the eyes move, the patient tells of the *direction of the movement of the test object*. He sees the test object apparently move precisely as his eye moves. A *prism* of sufficient strength to abolish all movement of both the test object and the eye represents the exact amount of deviation present. This combined test is very accurate; deflection of one-half of a degree can be satisfactorily measured by it.

The Maddox Rod (Fig. 340) consists of one or more pieces of glass rod set in a hard-rubber disc, so as to fit into the trial frame. It converts the image of the flame perceived by one eye into a long streak of light (Fig. 341), so that there remains no desire to unite it with the image of the other eye. The line is always at right angle to the axis of the rod.



FIG. 340.—Maddox Rod.

The Maddox rod is placed *horizontal* before the right eye, converting its image of the candle flame into a vertical streak. If *orthophoria* is present, this streak appears to pass directly through the image seen with the other eye (Fig. 341). If the line of light appears to the left of the flame, there is crossed diplopia indicating, *exophoria* (Fig. 342); if to the right of the flame, there is homonymous diplopia, indicating *esophoria* (Fig. 343). The amount of heterophoria is measured by the prism, base in or out, which serves to displace the streak until it runs directly through the flame.

FIG. 341. FIG. 342. FIG. 343.

FIG. 341.—The Maddox Rod Test in Orthophoria.
FIG. 342.—The Maddox Rod Test in Exophoria.
FIG. 343.—The Maddox Rod Test in Esophoria.

The rod is then placed *vertical* before the right eye, converting the image of this eye into a horizontal line of light, which will pass through the image of the left eye (Fig. 344) if *orthophoria* prevails. If this is below the image of the flame seen with the left eye, there is *right hyperphoria* (Fig. 346); if above, there is *left hyperphoria* (Fig. 345). The degree of hyperphoria is measured by the prism, base up or down, which causes the light streak to pass directly through the flame.

Any *strong convex cylinder* answers the same purpose. The Maddox rod is sometimes made of red glass, or a red glass is held in front of one eye, so as to color one image and thus effect a still greater reduction in the tendency to fuse the two images. A piece of *red glass* held in front of one eye is sufficient in itself to cause diplopia, whenever the heterphoria is marked.

Fig. 344. Fig. 345. Fig. 346.

Fig. 344.—The Maddox Rod in Orthophoria.
Fig. 345.—The Maddox Rod in Left Hyperphoria.
Fig. 346.—The Maddox Rod in Right Hyperphoria.

The Phorometer (Fig. 347) consists of a pair of 5° or 6° prisms. The latter are first placed with their bases up and down so as to produce vertical diplopia; if the double images

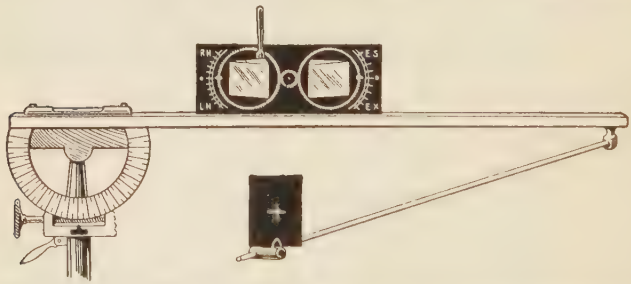

Fig. 347.—The Stevens Phorometer (the base and upright have been omitted from the illustration).

do not appear one exactly over the other, there is exophoria or esophoria; by rotation of the prisms, the images can be brought in a vertical line, and the degree of rotation required, read off on an attached arc, indicates the amount of exophoria or esophoria. Hyperphoria is determined in a similar manner, the prisms being placed with their bases in. The test object for near is a small metal plate, in the centre of which is a small cross with perforation.

The Near Point of Convergence is determined by carrying a fine test object (small white-headed pin) up to the eyes and

noting the nearest point on which, with maximum effort, convergence can be maintained. This point should not be more than 75 mm. from the anterior focal plane of the eye (the plane on which spectacles are worn). Any persistent remoteness of the near point of convergence denotes a weakness of that power.

In addition to determining the amount of heterophoria present for distance and near, it is important to measure the amount of prism the eyes can overcome. *Prism divergence* (*abduction*) is the ability to overcome prisms base in while looking at a distant object; the normal limits of this power are from 4° to 9°; it is constant and gives reliable information of the diverging power. *Prism convergence* (*adduction*) is the ability to overcome prisms base out; it is variable in amount and is of value only when repeated tests show a subnormal power; the normal limits are from 15° to 40°. *Risley's Rotary Prism* (Fig. 348) is a convenient instrument for measuring these powers.

FIG. 348.—Risley's Rotary Prism.

Symptoms.—In slight degrees of heterophoria there are very often no symptoms whatever. In more pronounced forms, the symptoms of *muscular asthenopia* are present: headache, pain in the eyes, indistinctness or "running together" of print, heavy and uncomfortable sensations referred to the eyelids, diplopia, nausea and vertigo. These asthenopic symptoms are the result of the *strain* imposed upon the muscles in overcoming the deviation. There are frequently periods of clear vision with strain, alternating with periods of diplopia with confused vision. Head tilting or actual torticollis may be present as a result of the patient's endeavor to correct a diplopia, particularly if it is vertical. These symptoms may be most pronounced on close use of the eyes, or on looking at distinct objects, depending upon the cause of the heterophoria. A characteristic feature of the symptoms due to a muscular trouble is their disappear-

ance on the closure of one eye. The dependence of epilepsy, chorea, and other serious nervous disorders upon heterophoria is extremely doubtful, but neurasthenia and disturbances of digestion and nutrition may be the result of the muscular error in predisposed individuals.

Etiology.—Heterophoria may be *refractive* or *non-refractive* in origin.

An *error of refraction* is a frequent cause for a disturbance of the normal relationship between accommodation and convergence. For example, a hyperope has to use an abnormally great amount of accommodation to maintain clear vision; thus his power of convergence is constantly overstimulated and an esophoria results; conversely, a myope uses too little accommodation and is likely to develop an exophoria.

Heterophoria of *non-refractive* origin is common, since all the cases due to a primary disfunction (overactivity or underactivity) of the power of divergence are not influenced by the state of refraction; it is equally true that many cases of weakness of convergence result from non-refractive causes. Heterophoria is frequently seen in neurasthenia, hysteria, anæmia, focal infections, in connection with nasal and accessory sinus disease, and in persons who are debilitated from any cause whatever; it is also found in perfectly healthy individuals. Occasionally an anatomical defect of one of the external muscles is responsible for the deviation.

Treatment consists in correction of the error of refraction, attention to the general health, prism exercises, the wearing of prisms, and as a last resort, operation.

1. *Correction of the Refractive Error* is of the greatest importance, and frequently is curative, though some cases are uninfluenced by glasses. An esophoria due to a *convergence excess*, *i.e.*, one which is greatest in amount at close range, is usually corrected by the constant use of the full hyperopic and astigmatic correction; if myopia is present it should be under-corrected. A *convergence insufficiency* causing an exophoria for near range calls for a full correction of the myopia and an under-correction of the hyperopia.

An exophoria or an esophoria due to a *divergence* anomaly, *i.e.* most pronounced for distance, is not materially influenced by the correction of a refractive error.

2. *Attention to the General Health* is a necessary and valuable adjunct to local treatment especially in neurasthenic and debilitated individuals who show a high degree of exophoria at close range and a very remote near point of convergence, with no refractive error to account for the deviation.

3. *Prism Exercises* are used chiefly in *exophoria* due to a non-accommodative weakness of convergence. Here the patient looks at a lighted candle, a prism base out is placed before one eye, and the two images are fused into one; after a few seconds the prism is removed. Starting with a weak prism (5°), the strength is gradually increased until the patient can overcome at least a 50° prism base out. This exercise is used either at 20 feet or at 13 inches, or at both distances. It is continued for several minutes two or three times a day and must be persisted in for several weeks to give results. In esophoria and hyperphoria prism exercises are not satisfactory.

4. *Prisms for Wear* may be used to correct deviations of low degree. The apex of the prism is always placed in the direction in which the eye turns. They are most satisfactory in hyperphoria. In esophoria and exophoria, prisms constantly worn tend to increase the deviation and their use is not generally advisable; in selected cases they may give relief which is, however, often only temporary.

If glasses are worn, the effect of a prism may be obtained by *decentering*—that is, displacing the optical centre so that it no longer corresponds to the geometrical centre of the lens (Figs. 349 and 350). *Decentering a convex lens in,* or a *concave lens out,* produces the effect of a *prism* with its *base toward the nose;* decentering a convex lens up or a concave lens down gives the effect of a prism with its base up. A lens of 1 D. must be decentered 8.7 mm. to produce the effect of a prism of 1°. To calculate the amount of decentering necessary to produce a certain prismatic effect, we multiply 8.7 by the value of the

prism, and divide the result by the strength of the lens in diopters. For example, a + 4 D. lens ⌔ prism of 2°, base in,

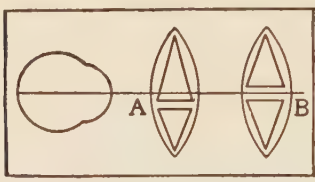

FIG. 349.

FIG. 350.

FIG. 349.—The Prismatic Effect of Decentering a Convex Lens. *A*, Convex lens decentered downward; *B*, optical centre corresponds to geometrical centre.

FIG. 350.—The Prismatic Effect of Decentering a Concave Lens. *A*, Concave lens decentered downward; *B*, optical centre corresponds to geometrical centre.

equals $\frac{8.7 \times 2}{4}$ = 4.3 mm.; such a lens should be decentered inward 4.3 mm. in order to have the added effect of a prism of 2° base in.

5. *Operation*, if used in carefully chosen cases, gives satisfactory results; it should not be resorted to until one is certain that no other measures will suffice; its success depends entirely upon a correct diagnosis of the underlying conditions producing the heterophoria; the best results are obtained in exophoria due to divergence excess by a tenotomy of the external rectus. The operations employed are *advancement* (or resection) and *tenotomy* (complete and guarded). The technique is the same as that used for the correction of strabismus. *Partial tenotomy* and *partial advancement* are operations which were resorted to formerly more often than at present; in these procedures only the central portion of the muscle is divided at its insertion or only the central portion advanced; the results are doubtful, often negative and disappointing, especially in the case of partial tenotomy.

NYSTAGMUS

Nystagmus is a short, rapid, involuntary *oscillation* of the eyeball, usually affecting *both* eyes and associated with *imperfect vision;* it may be *congenital* or *acquired.* The movements are most frequently from side to side (*lateral nystagmus*) or around the antero-posterior axis (*rotary nystagmus*), some-

times up and down (*vertical nystagmus*). There may be a combination of the lateral or vertical with the rotary movements (*mixed nystagmus*). The oscillations are similar in kind, duration, and frequency in the two eyes. They may be constant or present or exaggerated only when the eyes are turned in certain directions. The patient is *not*, as a rule, *inconvenienced* by the existence of this condition; but when it commences in adult life there may be much annoyance from the apparent movements of objects.

Most cases exist from *infancy*, and depend upon diminution in the acuteness of vision or *amblyopia* as a result of opacities of the media, intraocular diseases, albinism and other congenital anomalies, and very marked errors of refraction; in such instances the affection is due to defective vision, which prevents the infant or child from learning to fix properly.

In adults it may develop with many *cerebral affections*, especially disseminated sclerosis, disease of the cerebellum, and Friedreich's disease. It is found in miners (*miner's nystagmus*); in these cases it is due to defective illumination and strain and exhaustion of the ocular muscles, because the eyes must be turned in unnatural directions, especially when predisposed by errors of refraction. It occurs also in labyrinthine irritation and disease (*labyrinthine nystagmus*).

The usual infantile cases are *not amenable to treatment*, though the condition sometimes becomes less marked with advancing years; the *correction of errors of refraction* may be of some benefit. Miner's nystagmus generally disappears when the patient gives up this kind of work, and the labyrinthine variety ceases after the cause has been removed.

Operations.—The operations used to correct muscular deviations are (1) *Tenotomy*, intended to weaken a muscle, and (2) *Advancement, Resection* (and Tendon-Tucking), designed to strengthen a muscle.

TENOTOMY

Tenotomy may be *complete* or *guarded* (partial). Usually a complete tenotomy is done on the external rectus and a guarded on the other recti muscles. The methods of oper-

FIG. 351.—Fixation Forceps.

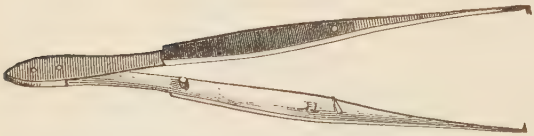

FIG. 352.—Toothed Forceps.

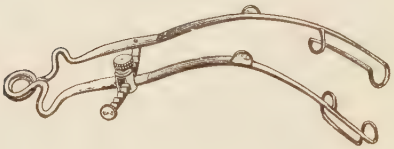

FIG. 353.—Eye Speculum.

FIG. 355.—Large and Small Squint Hooks.

FIG. 354.—Fine Curved and Half-Curved Needles.

FIG. 356.—Curved Strabismus Scissors.

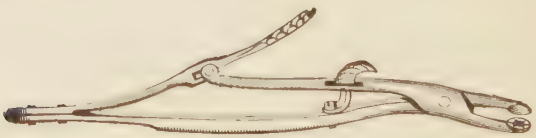

FIG. 357.—Sand's Needle Holder.



FIG. 358.—Advancement Forceps.

FIGS. 351 to 358.—Instruments Required for Tenotomy and Advancement of the External Ocular Muscles.

ating most frequently employed are the open and the subconjunctival.

Instruments.—(1) Eye speculum (Fig. 353); (2) fixation forceps (Fig. 351); (3) mouse-tooth forceps (Fig. 352); (4) blunt-pointed, curved strabismus scissors, such as Stevens' tenotomy scissors (Fig. 356); (5) two strabismus hooks (Fig. 355); (6) needle holder (Fig. 357); (7) fine curved needles (Fig. 354); and No. 5 twisted black silk.

The Open Method.—The speculum is introduced, the patient directed to look in such a direction as to expose the insertion of the muscle to be cut, the conjunctiva grasped with the mouse-tooth forceps, and a vertical incision (10 mm. long) made over the insertion of the muscle. Then the conjunctiva is dissected up freely; in the case of the internal rectus, the semilunar fold and the caruncle are freed. Next the tendon is grasped with the forceps and buttonholed in the centre near its insertion. A hook is passed into the opening, swept up to determine the amount of tendon remaining above this point, and the muscle cut towards the border, always leaving the lateral attachment. The hook is then carried below and all the fibres except the lateral attachment are severed. Performed in this manner, all of the muscle but none of the lateral attachment is cut. The conjunctiva is then sutured with interrupted, vertical silk sutures.

If a complete tenotomy is desired, the insertion may be cut straight through from one border to the other. To accomplish this, after the conjunctival incision, an opening is made into Tenon's capsule below the lower border of the muscle and a hook passed under the tendon. While the tendon is gently lifted away from the globe, one blade of the scissors is passed behind the tendon and it is completely severed close to its insertion including its lateral attachments. The conjunctival wound is then closed.

The Subconjunctival Method.—With the speculum in place, a small opening is made through the conjunctiva, subconjunctival tissue, and Tenon's capsule below the line of insertion of the muscle. A strabismus hook is introduced

into this opening, passed under the tendon and pushed upward until its point is seen through the conjunctiva at the upper border of the muscle. One blade of the scissors is passed between the tendon and sclera and the other between the tendon and the conjunctiva; the tendon is divided close to its insertion. The hook is reintroduced to ascertain that all fibres have been cut; if any are found uncut they are severed. The conjunctival wound is closed.

A *restraining suture* is sometimes passed through the muscle previous to tenotomy, so that if an overeffect has been produced, the muscle can be drawn forward and sutured so as to produce exactly the effect desired.

After-Treatment.—The result of the operation should be noted after completion. It may be necessary to lessen the effect by a suture which stitches the muscle forward to the insertion of the tendon; or to increase the effect by again introducing the hook and dividing any fibres which have escaped, avoiding, however, the upper and lower tendinous expansions. A protective dressing and bandage are applied to the operated eye and changed daily for three or four days, when the sutures are removed and the dressing discontinued.

There is usually no great reaction; the eye will be congested, but not painful. Sometimes there is slight deformity caused by a sinking of the caruncle. Infection occurs in rare instances, emphasizing the necessity for strict asepsis.

Recession is a modification of tenotomy in which scleral anchorage is used in order to gauge accurately the amount of weakening of the muscle. The tendon is exposed, completely severed from its insertion, and then sutured to the episcleral tissue 3 to 5 mm. behind its original insertion, thus limiting the amount of retraction of the muscle and its loss of power.

These forms of tenotomy are applicable to any of the recti muscles but the technique for tenotomy of the inferior oblique is quite different.

Tenotomy of the Inferior Oblique is indicated in paralysis of the superior rectus with spasm of the inferior oblique of the opposite side, and also in incurable paralyses of the

superior oblique. The instruments required are the same as those used in a tenotomy of a rectus with the addition of a muscle clamp. A curved skin incision ¾ inch long is made at the intersection of the lower orbital margin with a perpendicular dropped from the supraorbital notch. Dissection is made down to and through the septum orbitale close to the orbital margin. The tendon is engaged on a strabismus hook by keeping the hook in contact with the floor of the orbit and sweeping it inward. After being freed, the tendon is severed close to the periosteal attachment and a portion (10 mm.) is removed; no attempt is made to suture the ends. The skin wound is closed with interrupted silk sutures.

ADVANCEMENT OF AN OCULAR MUSCLE

The term advancement may be applied in a general sense to any operation designed to increase the action of an ocular muscle. There are three varieties: (1) *Advancement*, which brings the attachment of the muscle further forward; (2) *Resection*, in which a piece of the muscle is cut out, thus shortening the muscle; (3) *Muscle-tucking*, in which a permanent fold is made in the muscle and thus the latter is shortened.

Advancement.—In slight deviations it will be sufficient to advance the muscle without tenotomizing its opponent; for squints of greater degree, it is best to include a tenotomy upon the opposing muscle. Many methods of advancement have been designed; the Worth operation, which the author usually employs with slight modifications, is performed as follows:

The *instruments* required are the same as those needed for tenotomy with the addition of advancement forceps (Fig. 358). General anæsthesia is sometimes required, but in most instances, local anæsthesia is sufficient. After insertion of the speculum, the conjunctiva is grasped with the toothed forceps and a curved vertical incision is made, rather more than half-an-inch in length, with its convexity close to the corneal margin; a similar incision is made through Tenon's capsule; the conjunctiva and capsule then retract or are pushed and dissected back, so as to expose the muscle well.

A tenotomy hook is now passed under the muscle so as to free it sufficiently and then one blade of an advancement forceps takes the place of the hook, the other blade being clasped upon muscle, capsule of Tenon and conjunctiva with their relations undisturbed except for the retraction of the membranes (Fig. 359). The tendon and a few small fibrous bands are now divided at the insertion into the sclerotic. The part of the sclera near the cornea intended for the new insertion of the advanced muscle is carefully cleaned of all loose tissue so as to favor firm union. The advancement forceps holding tendon, capsule and conjunctiva can now be lifted up so as to get a good view of the underside of the muscle.

Two sutures of black No. 2 braided silk, with a needle at each end, and a third with rather lighter silk armed with a single needle, are required. One of the needles is passed inwards about 2 mm. behind the advancement forceps through conjunctiva, capsule and muscle at A′, and the other on the same suture at B′; the first needle is continued forward under muscle and advancement forceps; the second is made to pierce muscle, capsule and conjunctiva coming out at D. The other double armed suture, A.B., at the lower margin of the muscle, is then similarly dealt with.

Fig. 359.—Worth's Operation of Advancement of an Ocular Muscle.

The anterior parts of the muscle, capsule and conjunctiva are then cut off with scissors behind where they are grasped by the advancement forceps. The position of the loops of silk and the amount of tissue removed vary with the degree of rotation required; if only a small effect is desired, it may not be necessary to remove any tissue at all.

One needle of each of the two sutures is then inserted into the sclera near the corneal margin (G′, G); this step requires considerable skill; the needle is made to enter the sclera about one-eighth inch from the limbus and penetrates one-half the thickness of the sclera, care being taken not to pierce the whole thickness. Each suture is tied at H after gradual tightening. The third suture is then passed through conjunctiva, capsule and muscle and then through sclera exactly in the horizontal plane, midway between the two main sutures, affording additional protection and helping to keep the edges of the wound in apposition; if there are any gaps in the line of junction these are closed with additional fine sutures.

The immediate effect is the permanent result and overcorrection is not necessary. Both eyes are bandaged for three or four days, the operated eye for a week; stitches are removed on the eighth day. Worth keeps the patient in bed, with both eyes bandaged, for ten days, and leaves the sutures in for this period.

Resection.—One of the best of the muscle-shortening operations is that devised by Reese. The *instruments* used are the same as those used in a tenotomy with the addition of an advancement forceps (Fig. 358). Local anesthesia is usually sufficient, but general anesthesia is necessary in young children or in very nervous individuals.



FIG. 360.—Reese Resection Operation. Muscle Exposed.

With the speculum in place, a vertical incision, 10 mm. in length, is made in the conjunctiva along the insertion of the tendon. At the upper and lower ends of the wound an opening is made into the tissue anterior to the sclera through which a strabismus hook is passed upward beneath the muscle. With the muscle held taut it is carefully freed from the conjunctiva and fascial tissues at the upper and lower margins of the tendon. One blade of the advancement

forceps is inserted under the muscle and the forceps is clamped on the tendon about 3 mm. from its insertion (Fig. 360); the tendon should be thoroughly spread out on the clamp before it is closed; it is divided 2 mm. from its insertion, leaving a stump.

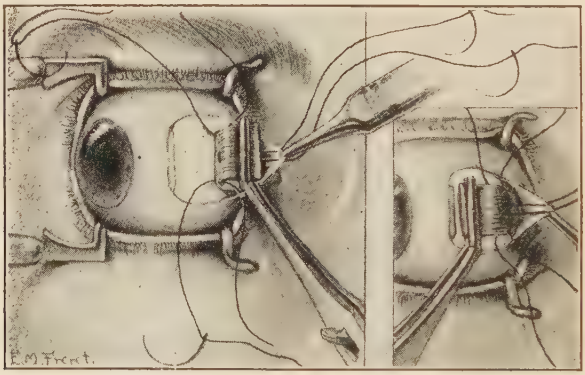

FIGS. 361 and 362.—Reese Resection Operation. Showing the Placing of the Sutures.

Three sutures are necessary. The middle suture consists of No. 3 braided silk with a needle on each end; both needles are passed through the under surface of the muscle, 4 mm. back of the point of resection and then through the dissected edge of the conjunctiva, so as to form a loop 2 mm. broad, in the central part of the muscle, on its scleral surface. This central suture is reinforced by an upper and a lower suture of No. 5 twisted silk; the single needle of each of these sutures passes first through the upper and lower part of the dissected conjunctiva and then includes the superior and inferior border of the muscle respectively, slightly posterior to the loop of the middle suture (Figs. 361 and 362).

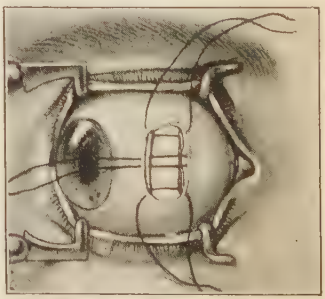

FIG. 363. —Reese Resection Operation. The Sutures Ready to be Tied.

The muscle is cut 2 mm. in front of the loop. The two

needles of the middle suture are brought out through the center of the stump, 2 mm. apart, and the other two needles through the upper and lower edges of the stump, all including the conjunctiva as they pass from behind forward (Fig. 363). All three sutures are then tied. The middle suture is removed in ten days, the others can be removed after forty-eight hours. The eye operated upon only is bandaged and dressed for five days.

Tendon-Tucking.—Many operations for producing permanent folding of the muscles have been advocated. The muscle and tendon are exposed, freed from all attachments to the sclera, and then a portion of the muscle is folded upon itself, often by the means of a specially-constructed double or triple hook; the folds of tendon are then sewn together with catgut, and thus a permanent shortening of the muscle is produced.

CHAPTER XXVI

OCULAR THERAPEUTICS

GENERAL RULES FOR EYE OPERATIONS

The eye being a very delicate and sensitive organ, it becomes necessary, in applying various therapeutic resources, to limit the strength of local applications and to observe care in the manner in which such remedies are applied.

Remedies employed in the treatment of diseases of the eye may be divided into 1. *constitutional*, and 2. *local*.

Constitutional Remedies are frequently prescribed and often exercise a marked influence on the progress of ocular disease. Many systemic disorders present ocular manifestations; and an important part of the treatment of the latter consists in general medication intended to correct the constitutional disturbance. Syphilis, tuberculosis, anæmia, and other disordered states give rise to well-marked eye symptoms and diseases, which will yield only after proper *internal treatment*. Some ocular diseases are dependent upon a lowering of the general health, for which *tonics* are indicated. *Rest in bed* is often absolutely necessary for the effective control of some of the acute affections of the deeper structures of the eye. Thus it is evident that the condition of the system cannot be disregarded in the treatment of ocular diseases.

Local Remedies.—Drugs intended for local use to the eye are most frequently dissolved in *water;* a saturated solution of *boric acid* forms a very good menstruum. Such remedies are also used in *oily, ointment, powder*, or *solid* form.

CLEANSING AND ANTISEPTIC SOLUTIONS

Solutions of this sort are employed for *flushing* the conjunctival sac and *removing secretion*. They are used *freely*, are bland and *unirritating*, and should be *lukewarm*. They are allowed to run between the lids from a wad of *absorbent cotton*,

from an *eye-dropper* (using 2 or 3 dropperfuls), or poured out very conveniently by means of the *undine* (Figs. 364 and 366), or with a soft-rubber bulb syringe (Fig. 365).

Fig. 364.—Undine for Irrigating the Eye.

The *eye-cup* is very popular for this purpose; before use, the edges of the lids should be cleansed; otherwise the fluid will become contaminated with dust adhering to the lashes and introduce this into the conjunctival sac.

The cleansing and antiseptic solutions which are used most frequently are:

1. *Boric Acid* in saturated solution (about 3 per cent.); ℥ss. of the crystals to O i.

2. *Sodium Chloride* in physiological strength (0.6 per cent.; ʒi to O i.).

3. *Mercuric Chloride*, from 1 : 10,000 to 1 : 6,000; gr. i. to O i.

The following will be found useful when a bland and cleansing solution is required:

℞ Sodii bicarb... gr. x.
Sodii bibor.... gr. x.
Aq. camphor.. ʒi.
Aq. destill.... ℥iv.
M. S. Eye wash.

℞ Ac. boric.....gr. x.
Sod. bibor.... gr. xv.
Glycerin..... ʒi.
Aq. destill.... ℥iv.
M. S. Eye wash.

Fig. 365.— Soft-Rubber Eye Syringe.

Boric Acid (boracic acid) is used more frequently than any other of these remedies. Though chemically an acid, its solution is *bland and soothing* and is often employed for irrigation. It is frequently prescribed with white vaseline or cold cream, in the form of an *ointment*, to prevent adhesion of the lids overnight, when there is considerable discharge.

℞ Acidi borici..... gr. iij.
Vaselini albi..... ʒ ij.
M. ft. ungt.

℞ Acidi borici..... gr. iij.
Ungt. aq. rosæ..... ʒ ij.
M. ft. ungt.

Alkaline Wash.—An excellent eye-wash, taking the place of solution of boric acid, with greater comforting and cleansing effects, is the following:

℞ Sodii Bicarbonat..... gr. xv.
Sodii Biborat..... gr. xv.
Sodii Chloridi..... gr. xv.
Glycerini..... ʒ i.
Aquæ Filtrat..... ʒ viii.
M. S. Eye wash.

This solution is often preferred to boric acid solution by the patient; it will be found very useful for general and free use in the various forms of conjunctivitis, and exceedingly grateful for washing out the eyes following exposure to wind and dust, after automobiling, golfing, etc. It supplies a superior substitute for the various proprietary eye-washes, sold by druggists and others, which often contain ingredients, such as adrenalin and local anæsthetics, which are not entirely devoid of injurious effects upon the eyes after continuous and prolonged use.

Patients often desire to wash out the conjunctival sac, upon arising and when retiring, with an eye-wash of this character, and then make use of the solution in large quantities. In such cases, the following directions can be given for preparing the eye-wash at home: "Take a moderately-heaped teaspoonful *each* of bicarbonate of soda, of borax, and of table salt; dissolve these in one quart of boiled water; add a full tablespoonful of glycerine, and filter."

When flushing the conjunctival sac, the escaping fluid may be caught in a pus-basin pressed against the patient's cheek, a towel having previously been wound around the neck to avoid soiling the clothes. But a much neater plan is to absorb the escaping fluid by means of a roll of *cellucotton* held below the lower lid and pressed against the cheek; this substance resembles absorbent cotton in appearance, consists of prepared wood-pulp, is comparatively cheap, and is much more absorbent than ordinary cotton which is often quite defective in this quality.

STIMULATING AND ASTRINGENT REMEDIES

The remedies of this class used most frequently are: Zinc sulphate, tannic acid, alum, borax, thiosinamine, camphor, silver nitrate, copper sulphate, yellow oxide of mercury, ammoniated mercury, calomel, and ichthyol. They are intended to cure abnormal conditions of the conjunctiva, and are used principally in various forms of *conjunctivitis.* For this purpose they are prescribed in *small quantity.* Two or 3 drops are allowed to fall upon the everted lower lid from an eye-dropper (Fig. 367); the latter must not touch the lids or lashes, since such contamination would infect the liquid contained in the bottle to which the dropper is returned. Most of these remedies are used in *watery solution;* copper sulphate and alum are frequently employed in solid form.

FIG. 366.—Method of Irrigating the Eye with a Solution Poured from an Undine.

Zinc Sulphate is used very often in astringent collyria.

℞ Zinci sulph..... gr. i.
Aquæ destill..... ℥ i.
M. S. Two drops in each eye three times a day

℞ Zinci sulph..... gr. i.
Acidi borici..... gr. v.
Glycerini..... ℥ ss.
Aquæ destill..... ℥ i.
M. S. Eye drops.

℞ Zinci sulph..... gr. i.
Acidi borici..... gr. v.
Aquæ destill..... ℥ i.
M. S. Eye drops.

℞ Zinci sulph..... gr. i.
Aquæ camphor..... ♏ x.
Aquæ destill..... ℥ i.
M. S. Two drops in each eye twice a day.

Tannic Acid is sometimes used in combination with other astringents. It is often dissolved in glycerin, and solutions of

5 to 25 per cent. are painted on the everted lids in trachoma.

℞ Acidi tannici..... gr. ss.
Zinci sulph..... gr. ss.
Aquæ destill..... ʒ i.
M. S. Two drops in each eye two or three times a day.

℞ Acidi tannici..... gr. ss.
Acidi borici..... gr. v.
Aquæ destill..... ʒ i.
M. S. Two drops in each eye two or three times a day.

Alum (gr. $\frac{1}{4}$–i. to ʒ i.). Long-continued use is said to injure the cornea. The stick of alum is applied to the everted lids in chronic conjunctivitis, and in mild forms of trachoma.

Fig. 367.—Method of Instilling Drops by Means of an Eye-Dropper.

Borax is used as a cleansing wash (ʒi. to O i.), or in combination with other remedies:

℞ Zinci sulph..... gr. ss.
Sodii biborat..... gr. iij.
Aquæ destill..... ʒ i.
M. S. Two drops in each eye two or three times a day.

℞ Acidi tannici..... gr. ¼
Sodii biborat..... gr. iij.
Aquæ camphor..... ʒ ij.
Aquæ destill..... ʒ vi.
M. S. Eye drops.

Thiosinamine is used in 10 p. c. ointment, with massage, to reduce corneal opacities.

Camphor.—Though feebly soluble in water, such solution (aqua camphoræ) is stimulating and astringent, and is often incorporated in collyria.

Silver Nitrate, always dissolved in *distilled* water, may be used in the strength of gr. $\frac{1}{10}$ to gr. $\frac{1}{5}$ to ʒ i., *dropped* into the conjunctival sac. In *stronger* solution (gr. i. – v. to ʒ i.) it is *brushed* upon the *everted lids*, in various forms of conjunctivitis. Solutions of silver nitrate *spoil* upon contact with organic matter; the brush or cotton applicator should not be dipped into the bottle, but some of the solution should be

poured into a small vessel for each use. Silver solutions, when used repeatedly and frequently, may permanently *stain* the conjunctiva (*argyrosis*); hence they should be applied by the physician himself, and only for a *limited period*. When stronger than 1 per cent., they act as *disinfectants* and *caustics* (p. 401).

Copper Sulphate ("bluestone") may be employed in solution (gr. i. to ʒ i.); but its chief use is in the form of the *crystal*. A *flattened pencil* (Figs. 127 and 129) is rubbed across the everted lids in *trachoma*, and the excess washed off with water; the pencil should be flattened and have a blunt, rounded extremity (p. 120).

Yellow Oxide of Mercury, insoluble in water, is employed in an *ointment* made with white vaseline, cold cream, or lanolin (1 to 3 per cent.), which must be *thoroughly mixed* and preserved in a jar coated externally with asphalt varnish so as to be *impervious to light.*

℞ Hydrarg. oxidi flavi. gr. i.
Vaselini albi..... ʒ ij.
M. ft. ungt. S. Eye salve.

℞ Hydrarg oxidi flavi..... gr. ij.
Ungt. aquæ rosæ..... ʒ ij.
M. ft. ungt. S. Eye salve.

These ointments are often prescribed in *blepharitis*, chronic conjunctivitis, *phlyctenular* keratitis and conjunctivitis, *interstitial keratitis*, and *opacities* of the cornea. In blepharitis the ointment is rubbed into the margin of the lid, after removal of scales or crusts; in other affections, a small piece is transferred from a glass rod or cotton-tipped applicator or tooth-pick, to the everted lower lid, and thus into the conjunctival sac.

Ointments intended for home use can be prescribed in *individual collapsible metal tubes*; the patient is directed to pull down the lower lid, place the uncovered opening of the tube upon the everted conjunctiva, press out a small portion of the ointment, close the lids, and withdraw the point of the tube.

Ammoniated Mercury, a white, insoluble powder, is prescribed in the same strength and under the same circumstances as the yellow oxide of mercury.

Calomel, in the form of a fine powder, is dusted into the eye with a camel's-hair brush, or from cotton wound upon an applicator, in *phlyctenular keratitis* and corneal ulcers; it is be-

lieved to be slowly changed to corrosive sublimate by contact with the tears, and thus to keep the eye bathed in an antiseptic fluid; calomel should not be used if the patient is taking iodine, since such a combination produces the very irritating mercuric iodide in the tears.

Ichthyol in 5 or 10 per cent. ointment forms an excellent application for obstinate examples of *ulcerative blepharitis*.

Lead Acetate *should not be employed* since it deposits an insoluble salt of lead upon any corneal abrasion; this *stain* cannot be removed. Lead and opium wash is not, therefore, a desirable application for the eye.

DISINFECTANTS AND CAUTERANTS

True disinfectants (capable of destroying germs) cannot be instilled into the conjunctival sac under ordinary circumstances without injury to the cornea; they are, however, applied to *circumscribed* areas, the excess being washed off by water. *Corneal ulcers*, especially when *infected*, and *purulent conjunctivitis* furnish common indications for such use. Some of the remedies classified under this head, though not, strictly speaking, true disinfectants in the strength used, have an inhibitory action upon the growth of micro-organisms and thus act as *practical disinfectants*. Those used most commonly in connection with the eye are: mercuric chloride, chlorine water, potassium permanganate, carbolic acid, formalin, tincture of iodine, silver nitrate, argyrol, protargol, iodoform, ethyl hydrocuprein, and the cautery.

Mercuric Chloride (Corrosive Sublimate) is often prescribed in *purulent* and other forms of conjunctivitis. It may safely be used 1:5,000; when stronger, it injures the cornea, and must consequently be limited to the everted lids, and the excess carefully washed off. A strong solution, 1:500, is rubbed into the conjunctiva in the final stage of the operative expression of trachoma. Solutions of corrosive sublimate are often used to flush the eye during operations; they attack the metal of instruments and dull the cutting edges.

Corrosive sublimate is frequently used in 1:3,000 *ointment* (often known as White's ointment) made up as follows:

℞ Hydrarg. bichlor..... gr. $\frac{1}{6}$
Sodii Chlor..... gr. $\frac{5}{6}$
Alcohol dil..... q.s.
Petrolati albi..... ʒ i.

Dissolve sublimate and salt in a few drops of dilute alcohol and mix with the vaseline, which has previously been kept at a temperature of 212° F. for half an hour. *Stir until cool.*

This salve is bland, antiseptic, and very useful in various forms of conjunctivitis, ulcers of the cornea, phlyctenular affections, serving to keep the conjunctival sac filled with a weak disinfectant and to prevent adhesion of the lid margins overnight; many operators put a little in the conjunctival sac after cataract extraction and other operations upon the globe.

Chlorine Water (*freshly prepared*) diluted with 10 to 20 parts of water is sometimes employed in purulent conjunctivitis.

Potassium Permanganate in 1:5,000, or stronger, aqueous solution is used for irrigation in *purulent conjunctivitis.*

Carbolic Acid (3-per-cent. solution) is used only for disinfecting instruments. The pure acid is sometimes applied to *infected ulcers* of the cornea.

Formalin.—Solutions of 1:1,000 and 1:2,000 are used in purulent conjunctivitis; solutions of 1:500 are applied to infected ulcers; solutions of 1:200, and formalin vapor, are sometimes employed for the disinfection of instruments.

Tincture of Iodine is an excellent remedy in the treatment of *infected ulcers* (p. 143).

Silver Nitrate, a very efficient and popular disinfectant, is used in 1 or 2 per cent. solution, brushed upon the everted lids in purulent and sometimes in other forms of *conjunctivitis,* and the excess washed off; and one drop is instilled into the eyes of the new-born as a prophylactic measure against *ophthalmia neonatorum.* In stronger solution, and in solid stick, it is applied to *infected* and indolent *ulcers* and the excess neutralized by salt solution. Fused with potassium nitrate in various proportions, it forms the "*mitigated stick.*" For local anæsthesia preliminary to silver applications, *nitrate of cocaine* should be used instead of the customary muriate, since the latter is incompatible and precipitates chloride of silver.

Iodoform is a feeble disinfectant which is sometimes dusted upon *corneal ulcers*, or used in 2 to 4 per cent. ointment in such lesions. It is not infrequently dusted upon wounds after *plastic operations* upon the lids. *Nosophen* is an efficient and odorless substitute for iodoform.

Argyrol, an *organic salt of silver*, soluble in water, forming a brown solution, is used in 5 to 25 per cent. solution in the same class of cases in which silver nitrate is indicated; it is penetrating, not precipitated by albuminous fluids, and is *devoid of the irritating qualities* of silver nitrate; like the latter, it has a tendency to stain the conjunctiva, when used for a considerable period; it may also leave a brown discoloration upon the cornea when ulceration exists; its germicidal effect is very limited; its solutions should be freshly prepared.

Examples of permanent, brown, silver-staining of the conjunctiva (*argyrosis*) are seen quite often after the frequent instillations and the long-continued home use of argyrol. This is favored by the rather common habit of practitioners of prescribing solutions of argyrol as a sort of panacea for all eye affections. Hence, when this remedy is ordered for home use, one should take pains to limit the duration of its employment.

Protargol (5 to 25 per cent.) and other organic silver salts, known by trade names, have identical properties and uses as argyrol with somewhat greater germicidal action.

Ethyl Hydrocuprein (*Optochin*), a derivative of quinine, is useful for *pneumococcus* ulcer, in 1-per-cent. solution or salve.

The Electro-Cautery (p. 143) gives us the most certain means of limiting the spread of *corneal ulcers*, by destroying the infecting micro-organisms. It is also used in conical cornea, and in epithelioma of the lid.

MYDRIATICS AND CYCLOPLEGICS

Mydriatics are remedies which produce *dilatation of the pupil; cycloplegics* are agents which cause *paralysis of the ciliary muscle* (accommodation). Practically, these two terms are *interchangeable*, since, with two exceptions, mydri-

atics also produce paralysis of the ciliary muscle. The drugs commonly employed to induce mydriasis and cycloplegia are *atropine* and *homatropine;* much less frequently duboisine, daturine, hyoscyamine, and scopolamine. The remedies used to *dilate the pupil*, without action on the ciliary muscle, are *cocaine* and *euphthalmin.*

Indications.—These agents are used (1) in *iritis*, to dilate the pupil, prevent adhesions, and exert a sedative action; (2) in various diseases of the *cornea* and of the *deeper* structures; (3) after certain *operations;* (4) to paralyze accommodation in estimating the state of *refraction;* (5) to dilate the pupil for *ophthalmoscopic* examination; and (6) to enlarge the pupil in lamellar and nuclear *cataract.*

Atropine, the alkaloid of *Belladonna*, the most commonly employed mydriatic, is prescribed in the form of *sulphate* in solutions varying from $\frac{1}{2}$ to 3 per cent. (most often 1 per cent.); occasionally in ointment or oil.

℞ Atropin, sulphat.... gr. i.
Aquæ destill..... ʒ ij.
M. S. *Poison.* One drop in each eye every four hours.

℞ Atropin, sulphat..... gr. i.
Cocain, hydrochlor..... gr. ij.
Aquæ destill..... ʒ ij.
M. S. *Poison.*

Atropine *paralyzes the sphincter* of the pupil and *stimulates the dilator.* After instillation of 2 or 3 drops at intervals of 10 minutes, pronounced action will have taken place in half an hour after the last dose; *the effects last a week.* Atropine and other mydriatics (except, generally, cocaine and euphthalmin) *increase intraocular tension.* They are *contraindicated in glaucoma*, and in persons who have a tendency to this disease; we should carefully test the tension in persons past middle life before instilling atropine.

Atropine Poisoning.—In susceptible individuals atropine may cause *general toxic symptoms:* Dryness of the throat, flushing of the face, headache, vomiting, quick pulse, cutaneous eruption, excitability, and even delirium; *the antidote is morphine;* in such cases, absorption may occur in the nose and throat, the solution entering via the lacrymal duct; under these circumstances, or when we push the atropine, it is well to have the patient press upon the lacrymal sac for

some minutes after each instillation. Susceptibility to atropine poisoning may require the substitution of one of the other mydriatics, mentioned below; *ophthalmic discs*, which contain very small doses, may prove useful in such cases.

Atropine Irritation.—In some persons, when long continued, atropine may cause considerable *local irritation*, showing itself in congestion, œdema, and eczema of the lids, and follicular conjunctivitis.

When using atropine or other solutions for the local effects upon the cornea or deeper parts, the drop is allowed to fall upon the cornea or into the lower conjunctival sac, the upper lid being raised and the patient directed to throw the head back and to look down (Fig. 367). Such solutions are prescribed in small quantities (5ij.) and labelled "*Poison.*"

Duboisine Sulphate (gr. $\frac{1}{2}$ to 5ij.), Daturine Sulphate (gr. $\frac{1}{4}$ to 5ij.), Hyoscyamine Hydrobromate (gr. $\frac{1}{2}$ to 5ij.), and Scopolamine Hydrobromate (gr. $\frac{1}{8}$ to 5ij.), occasionally *substituted for atropine*, have similar attributes, are contraindicated in increased tension, and may also produce poisoning.

Homatropine Hydrobromate resembles atropine, but is *milder*. It is used to paralyze accommodation during examinations of *refraction*. Though not so perfect as with atropine, the effect is sufficient for all practical purposes, and lasts only 48 hours; after the examination, 2 drops of a $\frac{1}{2}$-per-cent. solution of *eserine* are instilled; the effects of homatropine will thus be neutralized within an hour; the eserine causes some annoying winking. Homatropine is used in 2-per-cent. solution, one drop instilled every few minutes for 4 doses; one hour and a quarter after the final dose, the eye will be ready for examination. Homatropine is frequently combined with cocaine for this purpose:

℞ Homatropin. hydrobrom..... gr. i.	℞ Cocain, hydrochlor..... gr. i.
Aquæ destill..... 5 i.	Homatropin, hydrobrom gr. ij.
M. S. Poison.	Aquæ destill..... 5 ij.
	M. S. Poison.

Euphthalmine, or **Eucatropine,** is very useful for dilating the pupil for *ophthalmoscopic* examination; 1 or 2 drops of a 5-per-cent. solution cause mydriasis in 30 minutes, and the

effects pass off within 2 hours; it has but a feeble action upon accommodation, and rarely causes increase in tension.

Cocaine Hydrochloride (Muriate) is often used for *moderate* dilatation of the pupil for *ophthalmoscopic* examination. One or 2 drops of a 4-per-cent. solution cause sufficient dilatation in 30 minutes, produce insignificant interference with accommodation, and the effects disappear within an hour. Cocaine acts by constricting the blood-vessels of the iris; it usually *diminishes tension.* It is sometimes combined with other mydriatics, and then increases the action of the latter.

MIOTICS

Miotics *diminish the size of the pupil,* producing tonic contraction of the sphincter and of the ciliary muscle, and *reducing* intraocular *tension.* These agents are employed chiefly in *glaucoma,* sometimes in ulcers of the cornea, especially when peripheral. *Eserine salicylate* ($\frac{1}{8}$ to $\frac{1}{2}$ per cent.) and *pilocarpine muriate* ($\frac{1}{2}$ to 2 per cent.) are prescribed; the former is stronger and has a tendency to produce conjunctival irritation and iritis; the latter is milder and free from these drawbacks.

℞ Eserin. salicylat.. gr. $\frac{1}{8}$—$\frac{1}{2}$.
Aquæ destill..... ℥ij.
M. S. Poison.

℞ Pilocarpin. muriat....gr.ss.—ij.
Aquæ destill.....℥ ij.
M. S. Poison.

LOCAL ANAESTHETICS

Cocaine Hydrochloride (Muriate), in 4 per cent. solution, is the most commonly used remedy for producing local anæsthesia of the conjunctiva, cornea, and to a certain extent the iris, during *operations* upon the eye; it is also used subcutaneously and subconjunctivally, with due regard for its *poisonous* qualities. It serves as a *temporary anodyne* in corneal and iritic affections, and as a *mydriatic* for ophthalmoscopic examinations. Combined with atropine and homatropine, it enhances the mydriatic action of these agents. Cocaine produces dilatation of the blood-vessels, after a preliminary contraction, and *lowers* intraocular *tension;* it has a tendency to cause *desiccation with desquamation of the corneal epithelium;*

hence after instillation the patient should be directed to keep the lids closed; for the same reason it should not be used for any length of time, and it is generally unwise to prescribe cocaine for home use.

One drop of 4-per-cent. solution with a second drop after a few minutes, is sufficient to anæsthetize the cornea for the removal of foreign bodies; for more penetrating effects, the instillations are repeated 3 or 4 times, at intervals of 2 minutes. Solutions of cocaine *do not keep well,* and should be freshly prepared for operations.

Holocaine Hydrochloride, or **Phenacaine Hydrochloride,** is an excellent local anæsthetic, manufactured synthetically, which has *supplanted cocaine* with many oculists; it is usually employed in 1-per-cent. solution. Its *advantages* over cocaine are: it is more penetrating, does not dilate the pupil, has no injurious effect upon the cornea, and its solution is mildly antiseptic and does not spoil; there is, however, more preliminary conjunctival irritation, and, though perfectly safe for instillation, it *cannot be used hypodermically,* since it causes toxic symptoms when employed in this way.

Other synthetic chemicals, which are more or less frequently used as *substitutes for cocaine,* include novocaine, alypine, butyn, eucaine B, tropacocaine, stovaine and acoine.

Novocaine (Procaine) is the anæsthetic of choice for *hypodermic* use in lid operations and excision of the lacrymal sac, being much *less poisonous* than cocaine; it is generally used in 2-per-cent. solution combined with adrenalin chloride 1:5,000; such solutions should be *freshly prepared* or else sterile ampoules should be employed. Novocaine also gives satisfaction when injected deep into the orbit in 4-per-cent. solution, inducing anæsthesia in iridectomy for acute congestive glaucoma and in enucleation and evisceration of the eyeball. A few drops are sometimes injected into the palpebro-temporal region preliminary to cataract extraction, to prevent injurious squeezing of the lids during this operation.

The other substitutes for cocaine are not in general use. Butyn has no advantages over holocaine and several deaths have been reported after its use by injection.

OTHER THERAPEUTIC MEASURES

Adrenalin (Suprarenin, Epinephrin), the active principle of the *suprarenal gland*, available in 1:1,000 aqueous solution of the chloride which can be diluted with salt solution, is a valuable *astringent and hæmostatic*. After instillation of solutions varying from 1:10,000 to 1:1,000, *blanching* of the conjunctiva occurs as a result of contraction of the blood-vessels, beginning in a minute and lasting half an hour. When the ocular structures are much congested, cocaine and holocaine produce unsatisfactory anæsthesia; if combined with adrenalin, these agents act better. Adrenalin is used in some cases of conjunctivitis with marked congestion, in affections of the lacrymal passages to facilitate expression of retained contents and the introduction of probes, in glaucoma, in congested conditions in general, and in operations upon the eye to prevent bleeding and to improve the action of local anæsthetics.

Dionin, a derivative of morphine, is an *analgesic*. It is used in iritis and iridocyclitis, glaucoma, keratitis, and scleritis; also for the *absorption* of pupillary exudates and corneal opacities. This remedy is not a local anæsthetic, but it relieves deep-seated pain, acting as a vasodilator and lymphagogue, stimulating the vascular and lymphatic circulation of the eye and producing marked dilatation of these vessels. It is employed in 2 to 10 per cent. aqueous solution, occasionally in powder or ointment form; after instillation there is marked chemosis and often swelling of the lids; the appearance of the eye is occasionally alarming, but there is no danger of serious consequences. Tolerance for the drug is established very rapidly and then the eye fails to react; hence we must increase the strength of the solution every few days or else intermit from time to time.

Subconjunctival Injections are employed in episcleritis, scleritis, iridocyclitis, choroiditis, keratitis, corneal ulcer, and in detachment of the retina. After holocainization, the conjunctiva about 10 mm. from the limbus is lifted up and punctured by the needle of a hypodermic syringe; from 5 to 15 minims of fluid are injected under this membrane, the patient

looking downward or upward so as to facilitate the operation. Various germicides—mercury bichloride 1:5,000–1:1,000, mercury cyanide 1:5,000–1:1,000, cinnamic acid (hetol) 1:100—are used and 1-per-cent. acoin often added to reduce the pain; but a solution of *sodium chloride* of physiological strength is equally effective and much less painful.

Fluorescein, an orange-red powder, is used in 2-per-cent. aqueous solution (with sodium bicarbonate, 3 per cent. added) to detect abrasions, infiltrations, and ulcers of the cornea and to define the limits of such lesions. A drop of the solution is instilled into the conjunctival sac and after a few minutes the excess is washed off with water; a green stain indicates loss or disease of corneal epithelium.

Local Bloodletting is of great benefit in affections of the deeper structures of the eye, especially in *iritis* and iridocyclitis, and sometimes in acute glaucoma. *Leeches* are frequently prescribed; four or more are applied to the temple, midway between the outer canthus and the tragus. Rarely blood is taken from the mastoid region in inflammations of the retina, choroid and optic nerve. The *artificial leech* (Fig. 168) is sometimes used as a substitute.

Salvarsan (Neosalvarsan, Arsphenamin) is often used intravenously in syphilitic ocular affections. The results in iritis are brilliant and in sympathetic ophthalmitis very encouraging; in other diseases (choroiditis, retinitis, papillitis, paralysis of external ocular muscles) the effects vary, but with a positive Wassermann reaction, the use of the remedy is advisable; in interstitial keratitis salvarsan is generally of some value. It is not used in atrophy of the optic nerve since no benefit has followed; but there is no evidence that salvarsan has a harmful effect upon the eyes or causes blindness even when inflammation or atrophy of the nerve is present.

Vaccines and Sera are valuable agents in suitable cases of ocular disease. When possible, an autogenous vaccine should be made; when this is impracticable, stock preparations may be used. *Gonococcal* vaccine gives excellent results in gonorrhœal iritis, less certain effects in purulent conjunctivitis. *Staphylococcal* vaccine may be of service in obstinate examples

of phlyctenular affections. *Autogenous* vaccines sometimes accelerate the cure of ulcers of the cornea and hordeola, and are occasionally useful in dacryocystitis and post-operative infections. *Diphtheria antitoxin* is indispensable in diphtheritic conjunctivitis; it has also been used, with occasional success, in infected corneal ulcers, severe forms of uveitis, and in inflammations following infection after wounds and operations upon the eyeball. Anti-pneumococcus serum may be of service in the early stages of infected corneal ulcers. *Boiled Milk*, in doses of 5 to 10 c.c., is injected into the gluteal muscles for the sake of its foreign protein contents, in cases of panophthalmitis, corneal ulcers, purulent uveitis, gonorrhœal ophthalmia and dacryocystitis; some good results have been reported. *Tuberculin* is extensively used in tuberculous eye affections, sometimes with very good results.

Tuberculin is used both for diagnosis and treatment.

For *diagnostic* purposes an injection of 1 mgm. of *old tuberculin* (T.O.) is given, and then general, local, and focal reactions are looked for; the first manifests itself in a rise of temperature and is of little importance in this connection; the *local reaction* shows itself in redness, induration and swelling at the site of the injection; the *focal reaction* produces an *increase in the ocular manifestations* and is a valuable indication of the tuberculous nature of the affection. If there is no reaction after the first injection, a second (2 mgm.) and if necessary a third (4 mgm.) is given at intervals of 3 days. Von Pirquet's test may be employed but is much less conclusive, especially in adults.

For *treatment*, *new tuberculin* (T.R. or B.E.) is usually employed, though old tuberculin is sometimes used. The initial dose is $\frac{1}{2000}$ mgm.; the injections are repeated every fifth day and the dose increased to 1/10,000 mgm.; then 0.0001 mgm. is added to each successive dose until 0.001 mgm. is reached; then 0.001 mgm. is added with each dose until 0.01 is reached; then 0.01 mgm. is added until 0.1 is the dose; this is then increased by 0.1 mgm. for each injection until finally 0.5 mgm. is given. The course of treatment occupies many months. Care must be taken to avoid a reaction, the dose being re-

duced if a reaction occurs. Children must be given very much less than adults. Tuberculin treatment is used in tuberculous iritis, choroiditis, episcleritis and scleritis; less frequently in phlyctenular affections and rarer forms of ocular tuberculosis.

Sometimes tuberculin is employed, with good results, in ocular disease in which the clinical signs point to tuberculosis, and yet no positive tuberculin reaction has been obtained.

Heat.— *Hot, moist compresses* are prescribed in affections of the *cornea, iris, ciliary body,* sclera, and orbit; also to hasten the formation of pus and to relieve pain in lacrymal abscess and panophthalmitis. They are applied by means of flannel or lint wrung out of water as hot as can be borne (115°), placed upon the closed lids, and renewed every minute or two.

Cold.—*Cold compresses* are used in inflammatory affections of the *conjunctiva.* Strips of lint, lintine, or similar material are folded to make *pads* of four thicknesses, about $1\frac{1}{2}$ inches square, moistened and cooled upon a *block of ice;* they are laid upon the closed lids and changed as soon as they become warm. In the absence of ice, the compresses may be wrung out of cold water. Ice should never be applied directly to the lids.

Electricity is seldom used in ocular therapeutics, except in the form of the *electro-cautery* for corneal ulcer (p. 143) and conical cornea (p. 153); *electrolysis* may be employed for the removal of distorted lashes (p. 47) and in xanthoma. The *galvanic current* is occasionally resorted to in paralyses of ocular muscles, optic-nerve atrophy, and corneal opacities, and high-frequency currents in atrophy of the optic nerve.

The X-Rays and Radium are used with benefit in trachoma, spring catarrh, and epithelioma of the eyelid. *Carbon-dioxide snow* is recommended for the same affections.

Massage is sometimes prescribed in interstitial keratitis, glaucoma, and in corneal opacities. A small quantity of white vaseline or a medicated ointment is placed in the conjunctival sac; then the finger is applied to the closed upper lid, and the cornea massaged by a gentle rotary motion for a few minutes at a time.

Protective Measures of various sorts are applied to the eye to insure *rest,* to keep out *light,* air, wind, and dust, and to

give *support.* The patient is sometimes kept in a *shaded* room during the course of diseases of the uveal tract and retina. Various kinds of glasses intended to *subdue the light* are frequently ordered; the colors generally used are varying shades of smoke, amber, green, and amethyst (see p. 351); such glasses may be either plane or curved (coquilles). Mica spectacles are worn by workmen engaged in stone-cutting and similar occupations. *Black Patches* (Fig. 368) are made use of to keep out light, to hold dressings in place, or when imperfect protection is sufficient; these should always be curved and never flat. The application of eye *bandages* is described on p. 415 (Figs. 373 and 374).

FIG. 368.—Eye-Patch.

GENERAL CONSIDERATIONS OF OPERATIONS

The rules of *asepsis and antisepsis* which govern general surgery are also indicated in ophthalmic operations, except that *strong solutions of germicides are not tolerated* by the eye. In other respects, the preparations connected with an operation are similar to those employed by the general surgeon.

Preparation of the Patient.—Unless the patient is to be prepared for general anæsthesia, he need not enter the hospital until the morning of the day of the operation, having taken a cathartic the night before. He should be in *good physical condition;* old age, albuminuria, and diabetes are no contraindications, but such patients require special care.

It is imperative to examine the conjunctiva and the lacrymal region before deciding to operate upon the eyeball, especially in iridectomy and cataract extraction; the presence of *mucopurulent* secretion renders such an operation extremely hazardous, on account of the danger of *infection;* in such cases, the

conjunctival or lacrymal affection must first be cured by appropriate treatment. A *culture of the conjunctival secretion* should be made in every case in which an incision into the globe is required; in cases of doubt, it is well to bandage the eye for twenty-four hours, and then to examine the dressing.

Preparation of the Hands of the Operator comprises thorough *scrubbing* with soap and warm water and immersion in 1:1,000 sublimate solution or alcohol. Rubber gloves are not worn during eye operations.

Preparation of Instruments.—*Blunt instruments* should be *boiled* in 1-per-cent. solution of soda, *rinsed* with sterile water, and then kept in a sterile solution of salt (0.6 per cent.), or allowed to dry in sterilized gauze. *Sharp instruments* should be tested upon thin kid stretched in the testing-drum (Fig. 369).

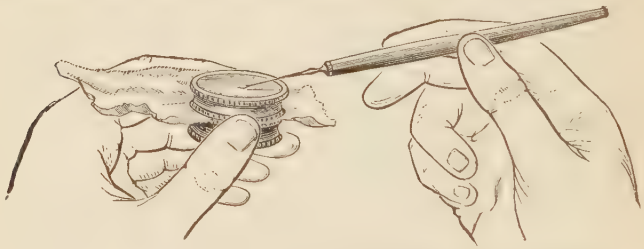

Fig. 369.—Drum Used to Test the Cutting Edges of Eye Instruments.

Knives with delicate cutting edges (such as cataract knives, keratomes, knife-needles, and cystotomes) are wiped carefully with benzin, dipped into pure carbolic acid, then into alcohol, held in boiling water for 20 seconds, transferred to alcohol, next to sterile saline solution, and finally allowed to dry; throughout this preparation great care must be taken not to injure the point or edge.

Position of the Patient. The patient may be operated upon either in bed or on a table, occasionally upon a special operating-chair (Figs. 370 and 371). *Daylight* answers very well for the lids and external muscles; but in operations upon the globe, especially cataract extraction, iridectomy, and the like, *artificial illumination* is preferred, the light being condensed upon the field of operation by a strong convex lens or better by means of an *electric projection lamp*.

Preparation of the Region of Operation.—The eyelids including the lashes, brow, and the surrounding skin, should be *cleansed* thoroughly with *soap* and warm water, and then washed with sublimate solution (1:5,000); many operators

FIG. 370.— The Author's Examining and Operating Chair.

FIG. 371.—The Same Converted into an Operating Table.

have the eye prepared the morning of the operation, and then covered by sterile gauze and a bandage, which dressing is not disturbed until the operation. The conjunctival sac is flushed with a large quantity of warm saline or boric solution preceding the operation; then the lashes and lid margins are painted with 3-per-cent. iodine.

Anæsthesia.—In the great majority of adult cases, *local* anæsthesia is sufficient in operations upon the eyeball: Two drops of 4-per-cent. *cocaine* or 1-per-cent. *holocaine* are instilled every few minutes for 4 doses, the lids being kept closed in the intervals.

Subconjunctival injection of a few minims of 4-per-cent. *cocaine* will render operations upon the globe absolutely painless, even to the cutting of the iris; one drop is injected 10 mm. below and an equal distance above the inner and outer canthi respectively; this keeps the injection away from the seat of operation. A hypodermic injection of *morphine* half an hour before operation is often useful in allaying nervousness.

In children, also in enucleations or evisserations, in acute congestive glaucoma, in blepharoplastic operations, and

occasionally in other procedures, a *general* anæsthetic is often necessary. But even in acute congestive glaucoma and with enucleations and eviscerations of the eyeball, a painless operation can be performed, after the injection of 1 c.c. of 4-per-cent. novocaine mixed with 1:5,000 adrenalin, deep into the orbit.

In many operations upon the *lids* a 2-per-cent. solution of novocaine in 1:5,000 adrenalin, is used *hypodermically;* the infiltration method of Schleich may be utilized, but the œdematous and altered appearance of the lids following this procedure is often objectionable. *General* anæsthesia is often resorted to in lid operations.

FIG. 372.— Gauze and Absorbent Cotton Dressing Retained by Plaster Strips.

Cleansing Solutions.—In the course of operations upon the eyeball, it is necessary to cleanse the seat of operation, and to *irrigate* the cornea frequently to prevent desiccation. The solutions used for this purpose are *boric* acid 3 per cent., *salt* 0.6 per cent., and *mercuric chloride* 1:10,000. These solutions are applied either by means of an undine (Fig. 364), a large pipette or eye-dropper, or small wads of absorbent cotton known as "cotton sponges."

Dressings vary very little with the nature of the operation. Usually a small quantity of bichloride ointment, 1:3,000, is placed in the conjunctival sac, the closed lids covered by a double, circular piece of gauze, $2\frac{1}{2}$ inches in diameter, wet with boric acid solution; upon this a variable amount of absorbent cotton, and then a circular piece of lint, $2\frac{1}{2}$ inches in diameter; this dressing is held in place by two strips of rubber adhesive plaster (Fig. 372) and retained by a bandage (Figs. 373 and 374). In cataract operations, additional pro-

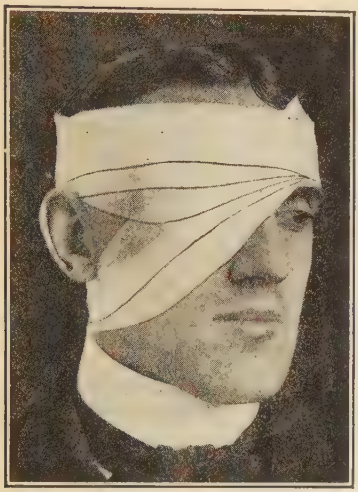

FIG. 373.—Monocular Bandage.

FIG. 374.—Binocular Bandage.

tection from injury is secured by Ring's mask (Fig. 226), wire gauze, or aluminum covers fastened over the dressings.

Eye Bandages are $1\frac{1}{2}$ inches wide, 5 or 7 yards long, and made of gauze or muslin. If for *protection* only, they are applied *lightly*; if for *pressure*, they are put on *firmly*, and then care must be taken that the depression between supraorbital margin and nose is properly filled with cotton.

The Monocular Bandage (Fig. 373) is applied as follows: Begin at the temple of the affected eye (right, for example); make one turn around the forehead, pass across the occiput, below the right ear, and obliquely across the right eye; then another turn about the forehead, below the right ear, across the right eye, alternating in this way three or four times.

The Binocular Bandage (Fig. 374).—Begin at the temple—the right, for example; make a full turn around the forehead and continue to the left temple, then obliquely across the occiput, below the right ear, across the right eye; around the upper occipital region, above the right ear, downward over the left eye, below left ear, across the occiput; below the right ear, across the right eye, and alternate in this manner for three or four turns.

CHAPTER XXVII

THE OCULAR MANIFESTATIONS OF GENERAL DISEASES

The ocular symptoms and diseases occurring with general affections, in most instances merely mentioned in this chapter, are discussed more fully in preceding pages, which must be referred to for fuller information on any particular point.

The systemic diseases which give rise to ocular symptoms and diseases most frequently are syphilis, tuberculosis, rheumatism, nephritis, diabetes, arteriosclerosis, cardiac affections, diseases of metabolism, chronic intoxications, infective diseases, and affections of the nervous system.

DISEASES OF THE BLOOD

Anæmia (Simple) and Chlorosis give rise to *pale pink conjunctivæ* and *pearly white sclerœ*. There may be pallor of the disc and the rest of the fundus, the retinal vessels being pale, tortuous, and the retinal veins broader than normal. Occasionally retinal hemorrhages are found.

Anæmia (Pernicious) often causes *retinal hemorrhages*, occasionally retinitis. The fundus exhibits great pallor.

Hæmophilia predisposes to profuse *hemorrhage* after injury to the eye, and under such circumstances may cause hyphæma, hemorrhage into the retina, or into the orbit.

Leukæmia.—Retinal hemorrhages are common, and a peculiar form of retinitis, "*leukæmic retinitis*," is often present.

Purpura is often accompanied by *hemorrhage* beneath the conjunctiva, in the retina, skin of the lids, and occasionally into the orbit.

Hemorrhage (Severe) may be accompanied by *amblyopia*, either temporary and accompanied by little or no ophthalmoscopic change, or permanent and followed by optic-nerve atrophy. Such sudden and severe anæmia may cause *retinal hemorrhages*.

DISEASES OF THE CIRCULATORY SYSTEM

Heart.—Valvular heart disease and fatty heart are often accompanied by *hemorrhages into the retina,* less frequently into the vitreous. Aortic insufficiency causes pulsation of the retinal arteries. Endocarditis may cause *embolism* of the central artery of the retina. The *œdema* dependent upon cardiac disease may involve the *eyelids,* being noticed especially upon rising in the morning.

Aorta.—Aneurysm of the aorta may give rise to mydriasis, enlarged palpebral aperture, and exophthalmos as a result of irritation of the cervical sympathetic; or to miosis, slight ptosis, and enophthalmos through paralysis of the same; this condition may also cause thrombosis and embolism of the central artery of the retina or of one of its branches.

Arteriosclerosis gives rise to *characteristic changes in the fundus* which are described on page 264 and illustrated on Plate XVIII. It is a predisposing cause of glaucoma.

DISEASES OF THE DIGESTIVE SYSTEM

Teeth.—The occurrence of ocular symptoms and diseases dependent upon *dental disease* is not rare, and in such cases it is not uncommon to have the ocular symptoms disappear and the ocular disease improve when the offending tooth is filled or extracted. Such symptoms include conjunctival congestion, photophobia, epiphora, asthenopia, amblyopia, and weakness of accommodation. Iritis, keratitis, cyclitis, and choroiditis may be dependent upon dental disease giving rise to *oral sepsis.*

Stomach and Intestines.—Dyspepsia and chronic affections of the stomach and intestines cause ocular symptoms by interfering with nutrition and reducing the general tone of the individual; thus we often find *asthenopia,* weakness of accommodation, and heterophoria. *Absorption of septic matter* from the gastro-intestinal tract may give rise to iridocyclitis or choroiditis. The loss of much blood from gastric or intestinal *hemorrhage* may cause *amblyopia* with anæmia of the retina without other ophthalmoscopic changes, or with subsequent optic-nerve atrophy. Straining associated with constipation may cause subconjunctival, retinal, and vitreous hemorrhage.

Liver.—Diseases of the liver may cause ocular symptoms such as asthenopia and weakness of accommodation as a result of general loss in strength. In *jaundice*, the yellowish discoloration of *sclera and conjunctiva* is one of the earliest signs.

DISEASES OF THE DUCTLESS GLANDS

Acromegaly exhibits many ocular manifestations. There are hypertrophy of the margins of the orbit and thickening of the skin of the lids. Disease of the hypophysis causes characteristic *bitemporal hemianopsia*, though other abnormalities of the field of vision are met with, and there is often reduction in the acuteness of *vision*. There may be optic *neuritis* and optic-nerve atrophy, and paralysis of one or more of the ocular muscles. *Exophthalmos*, hypertrophy of the lacrymal gland with epiphora, and sluggish reaction of the pupils are also seen. Pain in the eyes and brow is sometimes complained of.

Myxœdema and Cretinism give rise to *swelling of the eyelids*, sometimes optic neuritis with consequent amblyopia, and may be a rare cause of interstitial keratitis.

Exophthalmic Goitre (Graves' or Basedow's Disease).—Though this is a constitutional disease and the ocular symptoms are not an essential part, the eye exhibits the most striking manifestations of the affection, some or all of the following occurring in almost every case:

Exophthalmos is usually present; it varies in degree; it may be slight or the proptosis may be so pronounced that the patient cannot cover the cornea with the lids; it is usually bilateral, but occasionally it affects only one eye. *Von Graefe's Sign* consists in a failure of the upper lid to follow the eyeball normally when the patient looks downward; the upper lid lags behind. *Dalrymple's Sign* is the name given to the abnormal widening of the palpebral aperture causing the staring look. *Stellwag's Sign* is the diminution in the normal involuntary power of nictitation as a result of which winking is imperfect, less frequent, and more irregular than normal. *Möbius' Sign* is the imperfect power of convergence resulting in asthenopic symptoms. *Gifford's Sign* is the difficulty in everting the upper lid due to retraction and rigidity.

Vision is not usually involved. The *cornea* may suffer when exophthalmos is extreme and causes much exposure; in such cases the lower part may become vascular, dry, or ulcerated, and occasionally destruction of the eyeball is the outcome.

There is a brownish *pigmentation* of the skin of the lids in some patients. There may be arterial pulsation visible in the fundus. Dilatation and inequality of the *pupils* may be present. The extrinsic ocular muscles, especially the abducens, may be the seat of paresis. *Epiphora* is very common.

DISEASES OF THE EAR

Choked disc and congestion of the papilla are frequently observed in sinus thrombosis complicating mastoiditis. *Nystagmus* is common and of great diagnostic import in affections of the labyrinth.

INFECTIVE DISEASES

Cerebrospinal Meningitis is often accompanied by ocular symptoms. *Conjunctivitis* occurs frequently; œdema of the lids and conjunctiva may be seen. There may be *pareses* of the extrinsic ocular muscles causing strabismus and ptosis; *nystagmus* is encountered. There may be abnormalities of the *pupils*, keratitis, retinal hemorrhage, optic neuritis, and optic-nerve atrophy. Iridochoroiditis, and purulent choroiditis, leading to *pseudo-glioma*, are not uncommon.

Cholera.—Owing to the shrinkage of orbital tissues the eyeballs are sunken, and the eyes surrounded by bluish circles; the cornea is often dull and sometimes infiltrated or ulcerated; there are subconjunctival hemorrhages.

Diphtheria.—With the exception of diphtheritic *conjunctivitis*, which is now rare, the ocular manifestations of diphtheria occur after the acute stage of the disease has passed, and are, therefore, *post-diphtheritic* symptoms. The latter include *paralysis* of one or more of the extrinsic muscles of the eye, usually the external rectus, and paralysis of accommodation. Occasionally optic neuritis occurs.

Erysipelas, when it spreads to the eye, causes great *swelling and redness*, so that the lids can be separated only with great difficulty; following this, there may be abscess of the eyelids

with sloughing of the skin. When the disease extends into the orbit, it causes *orbital cellulitis;* thrombosis of the retinal veins, optic neuritis, and atrophy of the optic nerve may follow; glaucoma sometimes results, and occasionally inflammation of the lacrymal gland and sac.

Gonorrhœa is responsible for the local infection of the conjunctiva resulting in *purulent conjunctivitis* in adults and in ophthalmia neonatorum in the new-born. It also gives rise to a form of *iritis* resembling rheumatic iritis, and much less frquently to a type of conjunctivitis; both of these affections are analogous to gonorrhœal arthritis, and are due to *metastasis* or the presence of toxins.

Influenza is almost always accompanied by *congestion of the conjunctiva* or by acute catarrhal conjunctivitis. There is frequently *severe pain* in and back of the eyeballs. Many ocular manifestations credited to influenza are probably dependent upon the depression which follows the disease; in this category may be placed weakness of accommodation and asthenopia. Infrequent ocular complications include corneal ulcer, pareses of extrinsic ocular muscles, retrobulbar neuritis, optic neuritis, optic-nerve atrophy, and orbital cellulitis.

Leprosy attacks the *eyelids*, frequently producing anæsthetic patches of the skin, loss of lashes and eyebrows, deposit of tubercles, and deformity of the lids. The *conjunctiva* often presents chronic conjunctivitis, tubercles, and pterygia. The *cornea* is a common seat of tubercles or leprous keratitis. More rarely the iris and ciliary body present tubercles.

Malaria infrequently gives rise to the following ocular manifestations: *keratitis*, optic neuritis, retrobulbar neuritis, hemorrhages into the retina and vitreous, amblyopia, and paresis of accommodation.

Measles is regularly accompanied by a *catarrhal conjunctivitis* with subjective symptoms of greater or lesser severity. In addition, there are very frequently *blepharitis, phlyctenulæ,* hordeola, superficial corneal ulceration, and asthenopia.

Mumps is complicated by *dacryo-adenitis* in a small number of instances; this rarely leads to suppuration. Œdema of the lids and chemosis may be present.

Pneumonia may be complicated by *herpes of the cornea* sometimes followed by corneal ulceration.

Relapsing Fever.—In a certain number of cases uveitis and iridocyclitis follow this disease; these generally end in complete recovery, but are sometimes succeeded by opacities of the vitreous, atrophy of the globe, and even panophthalmitis.

Scarlatina.—Acute catarrhal *conjunctivitis* is an ocular complication of scarlatina, but it is less frequent and milder than in measles; corneal ulcer is sometimes seen; both of these complications are more apt to be found in the convalescent stage than early in the disease. When this disease is complicated with nephritis, the characteristic fundus picture of albuminuric *retinitis* may be seen.

Septicæmia and Pyæmia give rise to *retinal hemorrhages* and sometimes to emboli in the choroid and retina; in the latter case, the complication results either in purulent choroiditis, followed by pseudoglioma, or in panophthalmitis.

Syphilis is frequently responsible for ocular disease. The primary sore may occur on the lids or conjunctiva. *Iritis* is due to syphilis in at least 25 per cent. of cases; it is an early symptom of the *secondary stage*, at which time the anterior segment of the eyeball is the vulnerable part; the later stages are more prone to attack the posterior segment, causing choroiditis, *chorioretinitis*, *optic neuritis*, and diffuse opacity of the vitreous. In the *tertiary stage*, gummata may be deposited in the iris, ciliary body, and the periosteum of the orbital wall, and there may be optic neuritis and *optic-nerve atrophy*, rarely interstitial keratitis. During this tertiary period *paralysis* and paresis of the *ocular muscles*, both extra- and intraocular, are quite common. *Inherited syphilis* is responsible for the great majority of instances of *interstitial keratitis*, and also for some congenital ocular defects.

Tuberculosis, though infrequently involving the eye, may affect the *iris*, *choroid*, and *sclera*, presenting characteristic deposits; still more infrequently the conjunctiva and lids present tuberculous disease. In acute general miliary tuberculosis and in tuberculous meningitis it is not uncommon to find

small tubercle deposits scattered over the fundus. Inequality of the pupils is seen in pulmonary tuberculosis.

In the so-called "*scrofulous*" or "*strumous*" diathesis, presenting a well-known clinical picture but indefinite pathology and association with the tuberculous state, there is a predisposition to many *common diseases of the anterior portion of the eye*, namely, conjunctivitis, blepharitis, phlyctenular conjunctivitis and keratitis, and occasionally interstitial keratitis.

Typhoid and Typhus Fevers are not particularly prone to ocular manifestations. There may be catarrhal *conjunctivitis, herpetic ulcers* of the cornea, and *retinal hemorrhages*. During extreme prostration, there is *enophthalmos* from wasting of the orbital tissues, and the cornea may suffer, becoming dry, infiltrated, or ulcerated from imperfect closure of the lids. During convalescence there may be paresis of accommodation and of the extraocular muscles.

Vaccinia.—There have been examples of accidental inoculation of the eyelids and conjunctiva with *vaccine virus;* in such cases, the pustules excite marked swelling and induration, involvement of the preauricular glands, and tendency to deformity of the lid from subsequent cicatrization.

Varicella may be complicated by *conjunctivitis*. The eruption may involve the conjunctiva and cornea, resulting in a *superficial ulcer* of little consequence.

Variola is responsible for destructive lesions of the lids and eyeball. The lids and conjunctivæ are often the site of *pustules* and subsequent cicatrices may cause deformity. Though pustules rarely appear upon the cornea, this part is not infrequently the seat of *keratitis* and of *ulceration;* the latter sometimes results in perforation and may present as sequelæ, opacities, adherent leucoma, or even destruction of the globe.

Whooping Cough.—*Subconjunctival hemorrhage* is often seen as a result of the severe paroxysms of coughing; occasionally such an extravasation of blood takes place in the lid; rarely it involves the orbit, causing serious damage.

Yellow Fever, in its early stage, presents *congestion* of the conjunctiva; this redness is modified by the addition of yel-

lowish discoloration at a later stage. Subconjunctival and retinal *hemorrhages* are also found.

DISEASES OF THE KIDNEYS

Nephritis presents many ocular manifestations. *Œdema* is often present in the lids, and may also show itself in the conjunctivæ (chemosis). *Albuminuric retinitis* is common, occurring most frequently with the chronic interstitial variety, but liable to complicate any other form, including the nephritis of scarlatina and pregnancy. *Exophthalmos* is often seen. During an attack of *uræmia, amblyopia* without ophthalmoscopic changes may be present; the pupils are dilated during this state.

MISCELLANEOUS DISEASES AND CONDITIONS

Consanguinity of Parentage presents examples of ocular abnormalities in the offspring, especially *retinitis pigmentosa* and *congenital ocular malformations.*

Diabetes.—The common ocular complications of diabetes are *cataract* and *hemorrhages in the retina.* Less frequently there occur retinitis, optic neuritis, retrobulbar neuritis, iritis, pareses of the external ocular muscles, and paralysis of accommodation. Diabetics occasionally present sudden and marked changes in the state of refraction of the eye, especially myopia, but also hyperopia, accompanying an increase in the amount of sugar in the urine.

Gout is sometimes responsible for a form of *iritis,* for *episcleritis* and scleritis, and rarely for marginal ulcer of the cornea, glaucoma, and hemorrhagic retinitis. Gouty individuals often complain of *"dry catarrh,"* a condition in which the conjunctiva is congested, and the patient experiences a hot feeling in the lids and a sensation as though a foreign body were present; such patients are sometimes subject to attacks of transient periodic episcleritis.

Headache, when persistent or frequently recurring, should always prompt a careful examination of the eyes. Errors of *refraction* are common causes of headache and neuralgia; not infrequently we find anomalies of the extrinsic ocular *muscles;*

less often presbyopia and accommodation weakness. The error of refraction which is most commonly responsible is *astigmatism;* less often hyperopia; the amount of astigmatism may be very moderate, even 0.25 or 0.50 D. The site of the pain varies, but is often supraorbital and frontal. Depreciation of general health is, in many cases, a predisposing factor; thus we often find that the glasses required to cure headaches in individuals who were debilitated are no longer necessary when the system has regained its normal tone after a vacation.

Migraine.—This affection, thought to depend upon some disturbance in the circulation of the cerebral cortex, is characterized by periodic or irregular attacks commencing with *blurring* of vision with or without *scintillating scotoma*, often more or less *hemianopic* in character. After a period varying from several minutes to half an hour, vision again becomes normal; then a very severe *headache* develops, accompanied often by nausea and vomiting, and followed by marked general *depression*. Though dependent, in part at least, upon depreciation in general health and excessive use of the eyes, the attacks are often aggravated by *eyestrain;* in such cases the seizures are prevented or made less severe by correction of errors of refraction or of heterophoria.

Rheumatism is responsible for a moderate number of examples of *iritis* and irido-cyclitis. It is the etiological factor in some cases of scleritis, *episcleritis*, tenonitis, and *palsies* of the extrinsic ocular muscles.

Rickets.—The subjects of rachitis often present congenital *cataract* (zonular), interstitial *keratitis*, and phlyctenular kerato-conjunctivitis.

Scurvy is accompanied by *hemorrhages* beneath the conjunctiva, in the retina, skin of the lids, and occasionally into the orbit. It not infrequently presents a form of *night blindness* which disappears when the affection is recovered from.

Vertigo, with or without nausea, is often dependent upon the same ocular errors which produce headaches and neuralgia. In addition to insufficiencies of the extrinsic ocular muscles, *pareses* of these *muscles* may be responsible.

DISEASES OF THE MIND

Insanity (Functional) presents no ocular symptoms of any importance. *Pupillary alterations*, including irregularity, are found not infrequently, but are not pathognomonic.

DISEASES OF THE NERVOUS SYSTEM

The eye furnishes information of great importance in the *diagnosis* of diseases of the nervous system, the intimate relationship between this part of the human anatomy and the visual organs being evident. Particulars regarding the condition of the optic nerves, the pupils, the eye muscles, the acuteness of vision, and the fields of vision are of great value.

Apoplexy gives rise to a number of ocular manifestations varying according to the part of the brain involved. *Retinal hemorrhages* may precede the cerebral affection and may serve as a warning of impending danger.

Encephalitis Lethargica frequently has among its first symptoms a paralysis of the third nerve of one or both sides, giving rise to ptosis, strabismus, diplopia and pupillary disturbances; sometimes the fourth and the sixth nerves are involved; nystagmus is common; changes in the fundi (neuritis) occur, but are rather uncommon.

Hereditary Ataxia has no eye symptoms except *pseudo-nystagmus*, irregular twitchings in lateral excursions of the eyes.

Hydrocephalus is often accompanied by *optic-nerve atrophy* and by *strabismus;* less frequently optic neuritis is found.

Meningitis often presents optic *neuritis*, abnormalities of the *pupils*, and *palsies* or spasms of the ocular muscles causing deviations. These ocular manifestations are seen most frequently in tuberculous meningitis, in which variety tubercles of the choroid are not infrequently found.

Myelitis is infrequently accompanied by optic neuritis, retrobulbar in type, and intense pain in the orbit and brow.

Paresis (General).—The subjects of this disease often present inequality and irregularity of the *pupils*, also miosis, and less frequently mydriasis. There is not uncommonly impairment or loss of the light reflex (*Argyll-Robertson pupil);* later there is added partial or complete loss of reaction to accom-

modation. Sometimes *atrophy* of the optic nerve with reduction in the acuteness of vision and restriction of the field is noted. *Palsies* of the third, fourth, and sixth nerves may occur.

Sclerosis (Multiple) presents numerous ocular manifestations; the latter are found in fully one-half of the cases. *Nystagmus* is a frequent symptom. The *fields* of vision often exhibit irregular peripheral *contraction* and central or paracentral *scotoma*, relative or absolute. An incomplete *optic-nerve atrophy*, unilateral or bilateral, is common, resulting from retrobulbar neuritis. There are also partial *paralyses* of the extraocular muscles, giving rise to diplopia.

Tabes is accompanied by many ocular signs. The *Argyll-Robertson pupil*, in which the reaction to light is lost, while that of convergence and accommodation is preserved, is present in the great majority of cases and usually exists on both sides. A deviation from circular shape, inequality, and marked contraction of the pupil (*miosis*) are very common; much less frequently mydriasis is present, but it is then very often associated with blindness. *Atrophy of the optic nerve* occurs often, is an early symptom, is progressive, and generally leads to blindness; with this change in the optic nerve there is reduction in the acuteness of *vision* and concentric contraction of the *field*. Ocular *palsies* are very common; they often occur early in the disease, involve the third and sixth nerves, rarely the fourth, appear suddenly in many instances, are generally transient, and are accompanied by diplopia—if the third nerve is involved, also by ptosis. Epiphora is sometimes observed; also incoordinated movements of the eyeballs.

Tumor of the Brain (including Abscess) gives rise to *choked disc* in the majority of cases, generally bilateral, and in most instances more marked on the side of the growth. There may be *palsies* of the ocular muscles and alterations in the *field* of vision. The characteristics of these changes are a great aid in *localization*.

FUNCTIONAL NERVOUS DISORDERS

Chorea.—"True chorea," now generally regarded as an acute infectious disease, is not caused by ocular anomalies.

Patients with "*Habit Chorea*" or "*Habit Spasm,*" having choreic movements of the muscles of the lids and secondarily of the face and neck, often suffer from *errors of refraction,* less frequently from lack of equilibrium of the eye muscles; relief of eyestrain by the wearing of glasses or the correction of the muscular anomaly sometimes effects a cure.

Coma.—Objective examination of the eyes may give important data in all forms of coma. If dependent upon *organic brain disease* there may be choked disc, mydriasis, and deviation of the eyes. If due to *cerebral hemorrhage* there may be miosis, inequality of the pupils, and conjugate deviation. With increased intracranial *pressure,* there may be dilated pupils. If *uræmic,* albuminuric retinitis may be found. When *alcoholic,* there may be dilatation of the pupils and pareses of external ocular muscles. If due to *poisoning* by opium or similar drugs, there will be extreme miosis.

Epilepsy.—The seizure frequently begins with a *visual aura:* transient flashes of light, colored sensations, and hemianopic or complete loss of vision. During the attack, there may be narrowing of the retinal arteries, the *pupils* are generally dilated and the light reflex is lost, and there is often spasm of the extrinsic ocular muscles causing conjugate lateral *deviation* of the eyes. After the seizure, there are distention of the retinal veins, often alterations in size of the pupils, and not infrequently temporary concentric contraction of the field and reduction in vision. Not very often, but certainly in some cases, epilepsy is excited by eyestrain, and the number and severity of attacks are reduced by the wearing of glasses.

Hysteria is sometimes responsible for a great variety of ocular symptoms, the principal ones being diminution in the acuteness of vision (*amblyopia* and even blindness), concentric contraction of the *field* of vision for form and colors, becoming more marked with each repeated examination, and *reversal in the relative size of the color fields.* Other ocular symptoms occurring in hysteria are scotoma, hemianopsia, photophobia, blepharospasm, and monocular diplopia. The pupillary reflexes and the ophthalmoscopic appearances are normal. The ocular manifestations are almost always referred to *one eye.*

Neurasthenia is often accompanied by *pain* in or around the eyes, or headache, usually aggravated upon close work, also *fatigue* and *discomfort* in reading or near use. In many cases these symptoms depend upon *errors of refraction* or *heterophoria* which in healthy individuals would give rise to no discomfort. These patients often obtain comfort by the wearing of correcting lenses or of prisms; but in some cases glasses are ineffective or give only partial relief; then the asthenopia is regarded as "neurasthenic" and is considered a neurosis dependent upon a general asthenic condition of the system.

DISEASES OF THE NOSE, NASO-PHARYNX, AND ACCESSORY SINUSES

The communication between nose and conjunctival sac by means of the lacrymal duct explains the frequent occurrence of ocular symptoms and affections as a result of nasal disease. In *coryza* there is often conjunctival congestion or acute catarrhal conjunctivitis with marked lacrymation. In hay fever these conditions are found, and also very annoying itching. In chronic *rhinitis*, catarrhal or hypertrophic, *conjunctivitis*, blepharitis, and phlyctenular affections are very common; in addition, the nasal swelling may obstruct the lower end of the lacrymal duct and produce stenosis, *dacryocystitis*, and lacrymal abscess. The lacrymal duct may convey infection from the nose to the conjunctival sac and cause *corneal ulcer*.

Adenoids not infrequently give rise to catarrhal *conjunctivitis*, follicular conjunctivitis, epiphora, and *asthenopia*.

Diseases of the Accessory Sinuses (maxillary, ethmoid, sphenoid, and frontal) are not infrequently responsible for many ocular symptoms and diseases, among which are orbital periostitis and cellulitis, exophthalmos, paresis or paralysis of the ocular muscles (both extrinsic and intrinsic), *asthenopia*, reduction in acuteness of *vision*, changes in the *fields* of vision including *scotomata* and *increase in size of the blind spot*, *choroiditis*, *optic neuritis*, neuroretinitis, retrobulbar neuritis, and atrophy of the optic nerve (see p. 83).

POISONINGS AND INTOXICATIONS

These conditions are responsible for ocular symptoms and disease, especially *retrobulbar neuritis* (less frequently optic-nerve atrophy) which results from poisoning by alcohol, tobacco, wood-alcohol, chloral, iodoform, lead, arsenic (atoxyl), bisulphide of carbon, nitrobenzol, and anilin.

CONDITIONS OF THE SEXUAL ORGANS AND OBSTETRICAL CONDITIONS

Excessive sexual intercourse has been held responsible for retinal hemorrhages and for optic-nerve atrophy in men.

Menstruation.—Ocular diseases often show an *exacerbation* at the menstrual period, and at this time *asthenopic symptoms* are often complained of and weakness of accommodation sometimes observed. *Vicarious* menstruation is occasionally represented by subconjunctival, vitreous, or retinal hemorrhage.

Pregnancy may be complicated by *gravidic retinitis* so marked as to justify premature delivery in order to save sight.

Parturition is accompanied by danger to the eyes of the child: Conjunctival infection may give rise to *ophthalmia neonatorum;* the use of the *forceps* during delivery has resulted in bruising of the lids, injury to the cornea, orbital hemorrhage causing exophthalmos, and even rupture of the eyeball. During this period the eyes of the mother may present, on rare occasions, retinal hemorrhages; and if there has been great loss of blood, amblyopia without ophthalmoscopic changes, or reduction of vision with subsequent optic-nerve atrophy may ensue. *Puerperal infection* may result in metastatic choroiditis or in panophthalmitis with loss of the eye. Parturition may also be followed by optic neuritis, atrophy of the optic nerve, retrobulbar neuritis, retinal hemorrhages, and embolism of the central artery of the retina, though all of these are rare.

Lactation, if prolonged and causing impairment of the mother's health, may be responsible for paresis of accommodation, asthenopic symptoms, and ulcer of the cornea.

INDEX

Abbreviations, 306
Ablatio retinæ, 267
Abduction, 381
Abscess, corneal, 141
  lacrymal, 75
  orbital, 79, 81
  retrobulbar, 81
  vitreous, 186, 223
Accommodation, 228, 310, 352
  amplitude of, 311
  and convergence, 313, 373
  anomalies of, 352
  Helmholtz theory, 311
  mechanism of, 310
  paralysis of, 354, 366
  range of, 311
  spasm of, 355
  Tscherning theory, 311
Achromatopsia, 281
Acoine, 406
Adduction, 381
Adrenalin, 95, 407
Advancement of muscles, 384, 389
  guarded, 384
  limited or partial, 384
After-cataract, 229, 245, 247
Alkaline wash, 99, 396
Alum, 398
Alypine, 406
Amaurosis, 280
Amaurotic cat's eye, 196
  family idiocy, 261
Amblyopia, 280
  alcohol, 276
  color, 281
  congenital, 280, 371, 373
  ex anopsia, 280, 371, 373
  from disuse, 280
  hysterical, 284
  malarial, 286
  methyl-alcohol, 286
  quinine, 286
  reflex, 286
  simulated, 284
    tests for, 285
  tobacco, 276
  toxic, 276
  uræmic, 258
  wood-alcohol, 286
Amblyoscope, 374
Ametropia, 309
Amotio retinæ, 267
Anæsthetics, local, 405, 413
Angle alpha, 309
  gamma, 309
  iris, 198, 206
  meter, 314
  of anterior chamber 198 206,
Angle of convergence, 314
  of incidence, 293, 295
  of reflection, 293
  of refraction, 293, 295
  visual, 10
Anisometropia, 346
Ankyloblepharon, 58
Anophthalmos, 86
Antiseptic solutions, 394, 414
Aphakia, 234
Aqueous chamber, 164, 198
  humor, 7, 198, 199
Arcus senilis, 134
Argyrol, 99, 402
Argyrosis, 399, 401, 402
Arsphenamin, 408
Artificial eyes, 90
Asthenopia, 329, 347
  accommodative, 329, 348
  hysterical, 348
  muscular, 348, 381
  nervous, 348
  neurasthenic, 348
  retinal, 348
Astigmatic dial, 341
Astigmatism, 310, 319, 337
  against the rule, 235, 340
  compound, 339
  corneal, 338
  correction of, 345
  etiology of, 338
  irregular, 337, 346
  lenticular, 338
  mixed, 340
  oblique, 340
  refraction of rays in, 338
  regular, 337
  simple, 339
  symptoms of, 340
  tests for, 341
  treatment of, 345
  varieties of, 339
  with the rule, 340
Astigmia, 337

Astringent remedies, 397
Atrophy of eyeball, 180
Atropine, 170, 403
irritation, 404
poisoning, 170, 403
Axis, optical, 309
principal, 298
secondary, 299

Background, 25, 33
Bandages, eye, 142, 415
Beer's knife, 45
Bifocal lenses, 331, 350
Bjerrum's curtain, 18
Black eye, 65
Blennorrhœa, conjunctival, 103
of the lacrymal sac, 69
Blepharitis, 39
Blepharophimosis, 58
Blepharoplasty, 56
Blepharospasm, 5, 62, 125
Blind spot, 17
enlargement of, 84, 205
Bloodletting, 170, 408
Bluestone, 118, 398
Boracic (boric) acid, 395
Borax, 398
Bowman's membrane, 133
Buller's shield, 105
Buphthalmos, 86, 218
Butyn, 406

Calomel, 126, 399
Camphor, 398
Canal of Petit, 227
Schlemm's, 177, 199
Canaliculi, lacrymal, 66, 68, 69
Canaliculus dilator, 68, 71
knife, 68
slitting of, 72
Canthoplasty, 52
temporary, 53, 107
Canthotomy, 53, 107
Canthus, external, 38
internal, 38
Capsule of Tenon, 78, 158, 357
Capsulotomy, 238
preliminary, 234
Carbolic acid, 401
Carbon-dioxide snow, 129, 407
Cardinal points of the eye, 308
Caruncle, 38
sinking of, 388
Cataract, 228
after-, 229, 232, 245
anterior capsular, 242
anterior polar, 138, 228, 242
Cataract, artificial ripening of, 233
black, 232
brown, 232
capsular, 228, 242
capsulo-lenticular, 228, 232
central, 229, 244
chalky, 232
complete, 228
complicated, 229, 244
concussion, 229, 244
congenital, 229, 241
cortical, 230
development of, 230
etiology of, 229
fluid, 228
fusiform, 229, 244
hard, 228, 229
hypermature, 232
immature, 231
incipient, 231
juvenile, 229, 241
knife, 210, 237
lamellar, 228, 243
lenticular, 228
mask, 240
mature, 231, 233
monocular, 234
Morgagnian, 232
nuclear, 230
partial, 228, 242
pathology of, 232
posterior polar, 183, 228, 242
primary, 228
progressive, 228
punctuate, 229, 244
pyramidal, 242
ripe, 232
secondary, 228, 242, 244, 245
senile, 229, 230
shrunken, 232
signs of, 230
simple, 230
soft, 228, 229, 241, 245
stages of, 231
stationary, 228, 243, 244
swelling of, 231
symptoms of, 230
traumatic, 229, 244
treatment of, 232
uncommon forms of, 228, 244
varieties of, 228
zonular, 243
Cataract extraction, 234, 236
combined, 234, 236
complications of, 241
favorable time for, 233
indications, 236

Cataract extraction, in myopia, 245, 337
linear, 240
of lens in capsule, 240
prognosis, 235
simple, 234, 240
suction method, 241
with iridectomy, 234
without iridectomy, 234
Catarrh, angular, 101
dry, 94, 423
follicular, 99, 101
spring, 127
vernal, 128
Cauterants, 400
Cautery, 52, 54, 127, 143, 153, 402
Cavernous sinus, thrombosis of, 82
Cellucotton, 396
Cerebral decompression, 275
Chalazion, 43, 44
curette, 45
forceps, 45
suppurating, 43, 44
Chamber, anterior, 164, 198
anterior, angle of, 198
anterior, sinus of, 198
aqueous, 164, 198
posterior, 164, 198
Chemosis, 4, 81, 96, 103
Chiasm, 288
Chlorine water, 289, 401
Choked disc, 271, 272, 273
Chorio-capillaris, 182
Choroid, anatomy of, 182
atrophy of, 183, 185, 334
coloboma of, 187
diseases of, 182
inflammations of, see *Choroiditis*
physiology of, 182
rupture of, 187
sarcoma of, 194
tubercle of, 187
vessels of, 35, 182
Choroidal ring, 33
Choroiditic atrophy of optic nerve, 283
Choroiditis, 182
anterior, 185
central, 185
senile, 185
circumscribed, 184
diffuse, 184
disseminated, 184
exudative, 182
myopic, 185
non-suppurative, 182
Choroiditis, senile, 185
suppurative, 186, 260
syphilitic, 185
Choroidoretinitis, 182, 185, 253, 259
Cilia, 2, 38, 46
Ciliary body, 177
anatomy of, 177
diseases of, 177
inflammations of, see *Cyclitis*
injuries of, 181
vessels of, 177
ganglion, 78
injection, 93, 135, 166
muscle, 177, 327
paralysis of, 355
nerves, 177
processes, 177
tenderness, 8
Circumcorneal injection, 93, 135
Cleansing solutions, 393, 411
Clamydozoa, 118
Cocaine, 25, 403, 405, 413
Cold compresses, 410
Color blindness, 281, 283
central perception of, 18
perception theories, 281
peripheral perception of, 18
scotoma, 18
sense, 10, 18, 281
test lanterns, 283
worsteds, 282, 283
Color vision tests, 282
Colored vision, 283
Colors, field for, 18
Commotio retinæ, 261
Conjunctiva, 2, 92
acute blennorrhœa of, 103
anatomy of, 92
bulbar, 92
burns of, 131
diseases of, 94
ecchymosis of, 94
foreign bodies in, 131
fornix, 92
hyperæmia of, 94
inflammations of, see *Conjunctivitis*
injuries of, 131
nerves of, 93
ocular, 92
palpebral, 39, 92
retrotarsal, 4, 92
vascular supply of, 92
Conjunctival follicles, 92, 101
injection, 93
papillæ, 92

Conjunctival, sac, 92, 199
Conjunctivitis, acute catarrhal, 96
acute simple, 96
epidemic, 98
adult purulent, 103
angular, 101
catarrhal, in new-born, 110
chronic catarrhal, 100
chronic simple, 100
croupous, 112
diphtheritic, 110
diplobacillus, 101
eczematous, 123
electric, 97
exanthematous, 98
follicular, 99, 101
gonorrhœal, 103
granular, 113
infantile purulent, 107
lacrymal, 69, 98
membranous, 110
metastatic gonorrhœal, 107
Morax-Axenfeld, 101
Parinaud's, 123
phlyctenular, 123
purulent, 103
in new-born, 107
of young girls, 110
pustular, 124
scrofulous, 123
snow, 97
spring, 127
traumatic, 97
varieties of, 95
vernal, 128
Conus, 185
Convergence, 313
amplitude of, 314
and accommodation, 314, 373
angle of, 314
excess, 382
far point of, 314
near point of, 314
negative, 314
positive, 315
range of, 314
weakness of, 376, 382
Copper sulphate, 118, 120, 398
Coquilles, 411
Cornea, abscess of, 141
anatomy of, 133
burns of, 156
conical, 152
diseases of, 135
foreign bodies in, 154
infiltration of, 105, 134, 146
inflammations of, see *Keratitis*
injuries of, 154
Cornea, opacities of, 5, 21, 117, 153
paracentesis of, 143
perforation of, 137, 144
protrusions of, 150
ring abscess of, 141
sensitiveness of, 5
staphyloma of, 117, 138, 150
tattooing of, 154
transverse calcar. film of, 149
ulcer of, 117, 135
wounds of, 156
Corneal corpuscles, 134
endothelium, 134
epithelium, 133
facet, 136, 140
fistula, 138
lacunæ, 134
lamellæ, 133
leucoma, 153
macula, 153
microscope, 37
nebula, 153
reflex, 5, 28
ulcer, 135
annular, 140
atheromatous, 141
catarrhal, 97, 139
central, 140
deep, 139
dendriform, 141
herpetic, 141
indolent, 140
infected, 139
marginal ring, 140
Mooren's, 140
phytenular, 123
pneumococcus, 139
rodent, 140
serpent, 139
serpiginous, 139
simple, 139
sloughing, 139
transparent, 140
Corrosive sublimate, 395, 400
Credé's method of prophylaxis, 109
Crookes' glass, 351
Cyclitis, 165, 168, 178
plastic, 179
purulent, 181, 186
serous, 179
simple, 179
Cyclodialysis, 217
Cyclophoria, 378
Cycloplegia, 354
Cycloplegics, 349, 402
Cylinder, see *Lenses, cylindrical*
Cyst, Meibomian, 44

Cyst, tarsal, 44
Cystoid cicatrix, 208
Cystotome, 237

Dacryoadenitis, 69, 420
Dacryocystitis, 69, 75
Daturine, 403, 404
Day blindness, 288
Decentering of lenses, 384
Decompression, cerebral, 275
Descemet's membrane, 134
Descemetitis, 150, 179
Deviation, latent, 361, 377
manifest, 361, 369
primary, 362, 369
secondary, 362, 369
Deviations, varieties of, 361
Diaphanoscopy, 36
Dilator pupillæ, 164
Dionin, 407
Diopter, 303
Dioptric apparatus, 308
medium, 295
system, 303, 308
Diphtheria antitoxin, 409
Diplopia, 359, 362
crossed, 360
homonymous, 360
horizontal, 360
monocular, 248, 284
vertical, 360
Disc, see *Optic disc*
choked, 271, 272
diameter, 29
Placido's, 5, 344
Discission for after-cataract, 247
of the lens, 241, 245
Disinfectants, 400
Distichiasis, 46
Divergence excess, 377
Dressings, 414
Dry catarrh, 94
Duboisine, 403, 404

Ecchymosis of Lids, 65
Ectropion, 46, 53, 117
cicatricial, 53
mechanical, 53
operations for, 54
paralytic, 53
senile, 53
spasmodic, 54
Electricity, 410
Electrodes, eye, 143, 152
Electrolysis, 47
Emmetropia, 309, 319
Emphysema, 65
Enophthalmitis, 186
Enophthalmos, 4, 79, 422
Entropion, 46, 47, 117
cicatricial, 47
operations for, 48
senile, 47
spasmodic, 47
Enucleation of eyeball, 86
indications for, 88, 190
with artificial globe, 89
Epicanthus, 63
Epilation, 46
Epinephrin, 407
Epiphora, 53, 68
Episcleral tissue, 92, 94, 158
injection, 94, 177, 201
Episcleritis, 158, 159
transient periodic, 160
Erythropsia, 283
Escharotics, 64
Eserine, 209, 405
Esophoria, 378
Esotropia, 369, 372
Ethyl hydrocuprein, 142, 402
Eucaine B, 406
Eucatropine, 25, 404
Euphthalmine, 25, 403, 404
Evisceration, 89
Examination, dark-room, 21
external, 7
functional, 10
objective, 21
of media, 23
ophthalmoscopic, distant, 23
direct, 28, 318
indirect, 26, 318
for refraction, 24, 30, 317
subjective, 10
Extenteration of orbit, 91
Exophoria, 378
Exophthalmometer, 79
Exophthalmos, 4, 79, 85, 418
intermittent, 83
pulsating, 83
Exotropia, 369, 376
Eyeball, 77
associated movements of, 358
atrophy of, 180, 186, 190, 203
congenital anomalies of, 86
enucleation of, 86
with artificial globe, 89
evisceration of, 89
with artificial vitreous, 90
lymph channels of, 198
lymph spaces of, 198
movements of, 358
operations upon, 86

Eyeball, palpation of, 8
tension, 8
tumors of, 194
Eyecup, 395
Eyeglasses, 349
Eyestrain, 347, 381
Eyes, artificial, 90

Far point, 311, 331
Farsightedness, 326
Fascia, orbital, 77
palpebral, 39
Fibres of Gratiolet, 288
Mueller's, 251
Filtering cicatrix, 216
Fixation, field of, 358
line of, 309
Fluorescein, 5, 136, 408
Focal distance of a lens, 299, 303, 304
length of a mirror, 294
Focus, conjugate, 294, 299
negative, 300
principal, 294, 299, 309
real, 300
virtual, 294
Follicular catarrh, 101
Folliculosis, 102
Fontana, spaces of, 198, 199
Forceps, advancement, 386
capsule, 237
chalazion, 45
cilia, 46
entropion, 48
fixation, 210, 237, 386
iris, 210
toothed, 386
trachoma, 120
Form sense, 10
Formalin, 401
Fornix, 4, 92
Fovea centralis, 36, 250, 251
Fundus, 25, 33
physiological variations, 36
reflex, 24
Fusion, sense of, 372, 375

Ganglion, Ciliary, 78
Gasserian, 42, 145
Gerontoxon, 134
Gland, lacrymal, 67
Glands, Meibomian, 38, 39, 44
of Moll, 38
Zeiss', 38, 43
Glaucoma, 198, 199
absolute, 203
active stage of, 201
Glaucoma, acute congest., 199, 200
acute inflammatory, 199, 200
chronic congestive, 203
chronic inflammatory, 203
chronic non-congestive, 204
congenital, 86, 218
congestive, 199
degeneration stage of, 203
differential diagnosis, 167, 207
etiology of, 205
fulminans, 203
hemorrhagic, 216, 218
inflammatory, 199
malignant, 214
non-congestive, 199, 204
non-inflammatory, 199, 204
occurrence of, 205
pathology of, 206
primary, 199
prodromal stage of, 200
prognosis of, 208
secondary, 199, 218
simple, 199, 204
subacute, 199
symptoms of, 200, 204
theories of production, 206
treatment of, 208
varieties of, 199
Glaucomatous cup, 202
excavation, 202, 204
halo, 203
ring, 203
state, 201
Glioma of the retina, 194
pseudo-, 186, 196
Gonococci, 103, 108
Gonorrhœal conjunctivitis, 103
metastatic, 107
iritis, 172
ophthalmia, 103
Graefe knife, 210, 237
Grafts, Thiersch, 57, 130
Wolfe, 57
Granular lids, 113
Grattage, 121

Hand movements, 13
Head tilting, 362
Hemeralopia, 288
Hemiachromatopsia, 291
Hemianopia, 290
Hemianopsia, 16, 289, 290
absolute, 291
altitudinal, 291
binasal, 290
bitemporal, 290
complete, 291

Hemianopsia, crossed, 290
homonymous, 290
incomplete, 291
lateral, 290
relative, 291
transient, 292
Hemiopoa, 290
Hemiopic pupillary reaction, 291
Hemorrhage at macula, 186, 334
intraocular, 138
preretinal, 263
subconjunctival, 94
subhyaloid, 263
Herpes cornæ, 149
zoster ophthalmicus, 42, 149
Heterophoria, 361, 377
etiology of, 382
operations for, 384
symptoms of, 381
tests for, 378
Heterophoria, treatment of, 382
varieties of, 377
Heterotropia, 361, 369
Hetol, 408
Hole in the macula, 261
Holocaine, 95, 406, 413
Homatropine, 26, 349, 404
Hordeolum, 43
Hot compresses, 410
Hyalitis, 220
Hyaloid artery, 220, 242
persistent, 220, 242
canal, 220
membrane, 220
Hydrophthalmos, 218
Hyoscyamine, 403, 404
Hyperesophoria, 378
Hyperexophoria, 378
Hypermetropia, see *Hyperopia*
Hyperopia, 310, 319, 326
absolute, 328
axial, 326
etiology of, 326
facultative, 328
latent, 328
manifest, 328
ocular changes in, 327
of curvature, 326
symptoms of, 329
tests for, 329
total, 328
treatment of, 330
varieties of, 328
Hypertropia, 370
Hyphæma, 7, 166, 173
Hyperphoria, 378, 379
Hypopyon, 7, 137, 166
Hypopyon keratitis, 139

Ichthyol, 400
Illumination, oblique, 20, 37
Image, false, 359
true, 359
Images, double, 359, 363
formation of, 294, 300
negative, 294, 300
real, 294, 300
retinal, 252
virtual, 293, 300
Imbalance, muscular, 377
Incidence, angle of, 293, 295
Intermarginal space, 38
Interpupillary distance, 349
Iodine, tincture of, 143, 401
Iodoform, 142, 402
Iridectomy, 209, 238
indications for, 214
for artificial pupil, 215
for glaucoma, 211
results of, 213
optical, 215, 243
preliminary to cataract extraction, 234
Iridocyclitis, 165, 168, 178
acute, 178
chronic, 178
plastic, 179
purulent, 181, 186
serous, 179
suppurative, 186
sympathetic, 181
Iridodialysis, 173
Iridodonesis, 232, 235, 247, 248
Iridoplegia, 173
reflex, 176
Iridosclerectomy, 217
Iridotasis, 218
Iridotomy, 174
Iris, anatomy of, 164
angle, 198, 206
bombé, 169
coloboma of, 213, 215
forceps, 210
hook, 210
inflammation of, see *Iritis*
injuries of, 173
muscles of, 164
nerves of, 165, 174
operations upon, 174, 208, 209
paralysis of, 355
prolapse of, 173, 240
repositor, 210, 237
scissors, 210
tremulous, 232, 235, 247, 248

Iris, tumors of, 173
vessels of, 165, 174
Iritis, 165
acute, 165, 167
chronic, 165, 167
diabetic, 172
gonorrhœal, 172
gouty, 172
idiopathic, 169
nodular, 165
papulosa, 171
plastic, 165
primary, 165
purulent, 165
recurrent, 168
rheumatic, 171
scrofulous, 172
secondary, 165
septic, 172
serous, 165, 178
spongy, 165, 166
sympathetic, 172, 173
syphilitic, 171
traumatic, 169, 173
tuberculous, 172
Irrigation of anterior chamber in cataract extraction, 239

Jaeger's test types, 14
Jequiritol, 122
Jequirity, 122

Keratectasia, 137, 152
Keratitis, 134
accompanying herpos zoster, 42
band-shaped, 149
bullous, 149
dendritic, 141
desiccation, 145
e lagophthalmo, 145
fascicular, 124
from defective closure of lids, 145
herpetic, 141
hypopyon, 139
interstitial, 146
marginal, 123
neuroparalytic, 145
non-suppurative, 135, 149
parenchymatous, 146
phlyctenular, 123, 135
profunda, 149
punctuate, 150, 166, 179
sclerosing, 149, 160
superficial punctuate, 149
suppurative, 135
Keratitis, vascular, 116
vasculo-nebulous, 116
vesicular, 149
xerotic, 145
Keratocele, 137
Keratoconjunctivitis, phlyctenular, 123
Keratoconus, 152
Keratoglobus, 153, 218
Keratomalacia, 145
Keratome, 210
Keratoscope, 5, 344
Knife-needles, 246, 247

Lacrymal abscess, 75
apparatus, anatomy of, 67
diseases of, 69
canaliculi, 67, 68, 69
conjunctivitis, 69, 98
dilator, 68
duct, 67
fistula, 76
gland, 67
knife, 68
probes, 71
puncta, 67, 68, 69
retractors, 74
sac, 2, 67
abscess of, 75
blennorrhœa of, 69
catarrh of, 69
chronic inflammation of, 69
destruction of, 75
extirpation of, 74
incision into, 75
secretion, 68
sound, 71
styles, 73
syringe, 71
Lagophthalmos, 62, 145
Lamina cribrosa, 158, 270
vitrea, 182
Lamp, slit, 37
Lashes, 2, 38
Lead acetate, 400
Leber's disease, 279
Leech, artificial, 170, 408
Leeches, 107, 170, 209, 408
Lens, anatomy of, 227
anterior capsule of, 227
at different periods of life, 228
capsule of, 227
cortex, 227
crystalline, 227
discission of, 337
diseases of, 227

Lens, dislocation of, 247, 248
function of, 228
laminæ of, 227
loop, 237
luxation of, 248
measure, 306
nucleus of, 227
objective, 26
opacities of, 21, 228
physiology of, 228
posterior capsule of, 227
reflex of, 228
sclerosis of, 227, 228
sectors of, 227
spoon, 237
stellate figure of, 227
subluxation of, 247
suspensory ligament of, 227
Lenses, bifocal, 350, 351
converging, 297
cylindrical, 301
axis of, 302, 345, 350
decentering of, 384
diverging, 298
estimation of strength of, 305
finding of centre of, 306
magnifying, 297, 301
meniscus, 297, 298
minus, 298
negative, 298
numeration of, 302
of ophthalmoscope, 23
pebble, 350
periscopic, 297, 298, 350
plus, 297
positive, 297
recognition of kind, 305
reducing, 298
spherical, 297
action of, 297, 298
concave, 298
convex, 297
Lenses, spherical, conjugate foci of, 299
focal distance of, 299
foci of, 299
formation of images, 300
negative focus of, 300
positive focus of, 300
principal axis of, 298
real focus of, 300
secondary axes of, 299
virtual focus of, 300
sphero-cylindrical, 350
toric, 350
varieties of, 297, 306
Leucoma, adherent, 137, 153
Leucoma, corneal, 5, 153
Levator palpebræ superioris, 38
advancement of, 62
Lid clamp 45, 48
retractors, 7, 238
Lids, anatomy of, 38
burns of, 65
diseases of, 39
ecchymosis of, 65
emphysema of, 65
epithelioma of, 64
eversion of, 2
examination of, 2
glands of, 38, 39
granular, 113
injuries of, 64
insect—bites of, 65
muscles of, 38
nerve supply of, 39
œdema of, 41
physiology of, 38, 39
syphilis of, 41
tumors of, 63
vaccinia of, 41
vascular supply of, 39
wounds of, 65
Ligaments, cheek, 357
tarsal, 39
Ligamentum pectinatum, 134, 198
Light difference, 19
minimum, 19
perception, 13, 19, 235
projection, 235
rays of, 252
reflex of pupil, consensual, 175
direct, 175
indirect, 175
sense, 10, 19, 252
Limbus, 92, 133
Line of fixation, 309
visual, 309
Lymph spaces, anterior, 199
posterior, 199

Macropsia, 183, 253
Macula, corneal, 5, 153
hole in the, 261
lutea, 29, 36, 250
Macular fibres, 275, 288, 291
Maddox rod, 379
Magnet extraction, 225
Magnets, eye, 225
Mariotte's blind spot, 17
Mask, ocular, 240
Massage, 209, 410
Media, examination of, 20, 24
opacities of, 21, 24, 222

Mercuric chloride, 395, 400
Mercury, ammoniated, 399
yellow oxide of, 126, 399
Metamorphopsia, 183, 253, 267
Meter angle, 314
Methyl alcohol amblyopia, 286
Mica spectacles, 411
Microphthalmos, 86
Micropsia, 183, 253
Microscope, corneal, 37
Milium, 64
Mind-blindness, 248
Miotics, 209, 355, 405
Mirrors, 293
concave, 293
convex, 294
focal length of, 294
formation of images by, 294
plane, 293
retmoscopic, 321
Molluscum, 63
Motility, disturbances of, 357
Mucocele, 69, 83
Muscæ volitantes, 222
Muscle, Mueller's, 39
Muscles, eye, 357
action of, 357
advancement of, 389
anatomy of, 357
cardinal direction of gaze of, 358
contracture of, 364, 368
field of action of, 358
nerve supply of, 357
physiology of, 357
recession of, 388
resection of, 389, 391
spasm of, 368
tenotomy of, 384, 385, 387
Mutton-fat deposits, 179
Mydriasis, 25, 173, 349
Mydriatics, 25, 349, 402
Myopia, 310, 319, 331
axial, 332
choroiditis of, 185
clinical forms of, 333
etiology of, 332
high, 333, 334
malignant, 333
operative treatment of, 337
ophthalmoscopic signs, 334
prognosis of, 335
progressive, 185, 333
simple, 333
stationary, 333
symptoms of, 333
tests for, 334
Myopia, treatment of, 335
Myopic crescent, 185, 334

Nasal accessory sinuses, disease of, 83
duct, 67
probing the, 72
stricture of, 70
Near point, 311, 380
Nearsightedness, 331
Nebula, corneal, 5, 153
Needling of the lens, 241, 246, 337
for after-cataract, 247
Neosalvarsan, 408
Neuritis, descending, 271, 272
optic, intraocular, 271
retrobulbar, acute, 275
chronic, 276
Neuroretinitis, 253, 273
Night blindness, 266, 287
Nodal points, 308
Novocaine, 406, 414
Nyctalopia, 266, 287
Nystagmus, 281, 384
labyrinthine, 385
lateral, 384
miner's, 385
mixed, 385
rotatory, 384
vertical, 385

Oblique illumination, 20, 37
Old sight, 313, 353
Opaque nerve fibres, 36
Operation, Adam's, 55
De Grandmont's, 60
Dieffenbach's, 56
Elliot's, 216
Filtering cicatrix, 216
Frick's, 56
Graefe's, for ptosis, 60
Heine's, 217
Herbert's, 208
Hess', 61
Holth's, 218
Hotz's, 50
Jaesche-Arlt, 49
Knapp's, 56
Krönlein's, 91
Lagrange's, 217
Motais', 62
Mules', 90
Pagenstecher's, 60
Panas', 61
Saemisch's, 144
Streatfeild-Snellen, 51
V Y, 55

Operation, Wharton Jones,' 55
Ziegler galvanopuncture,
for ectropion, 54
for entropion, 52
Operations, gen. rules for, 411
Ophthalmia, 95
Egyptian, 118
electric, 97
gonorrhœal, 103
metastatic, 181, 187
neonatorum, 107
phlyctenular, 123
pustular, 124
scrofulous, 123
sympathetic, 188
Ophthalmitis, sympathetic, 188
Ophthalmometer, 343
Ophthalmoplegia, external, 366
internal, 355, 367
total, 366
Ophthalmoscope, 22, 317
electric, 23, 37
theory of, 31
Ophthalmoscopic examination, see *Examination*
Optic disc, 27, 33, 250
congestion of, 271
cupping of, 34, 202, 250
excavation of, 34, 202
hyperæmia of, 271
physiological depression of, 34, 202, 250, 270
temporal pallor of, 276
ganglia, primary, 288
nerve, 27, 33, 270, 288
anatomy of, 270
lymph spaces of, 270
Optic-nerve atrophy, 207, 277
choroiditic, 183, 278
gray, 277
inflammatory, 277
neuritic, 277
non-inflammatory, 277
postneuritic, 273
postpapillitic, 277, 278
primary, 277, 278
progressive, 277
retinitic, 254, 278
secondary, 277, 279
simple, 277
central artery and vein of, 34, 250
diseases of, 270
head of, 33, 250
inflammation of, 271
tumors of, 270
Optic neuritis, 271
axial, 275
intraocular, 271
orbital, 275
retrobulbar, 271, 275, 276
radiations, 288
tracts, 288, 289
Optical axis, 309
Optochin, 142, 402
Ora serrata, 250
Orbicularis muscle, 38
Orbit, abscess of, 79
anatomy of, 77
caries of, 80
cavities surrounding the, 77
contents of, 77
diseases of, 78
exenteration of, 91
fistula of, 80
injuries of, 85
necrosis of, 80
nerves of, 78
openings into, 77
tumors of, 85
vessels of, 78
Orbital cellulitis, 80, 81
fascia, 77
periostitis, 79
phlegmon, 81
Orthophoria, 378, 379
Orthoptic training, 374

Palpation of the eyeball, 8
Palpebral conjunctiva, 39
fascia, 39
Pannus, 116, 125
Panophthalmitis, 186, 192, 260
Papilla, 27, 33, 250
Papillitis, 271, 272
Papillœdema, 271, 272
Paracentesis needle, 144
Paralysis, associated, 367
basilar, 367
central, 367
conjugate, 367
cortical, 367
nuclear, 367
of accommodation, 355
of association centres, 367
of external rectus, 364
of inferior oblique, 366
rectus, 365
of internal rectus, 364
of iris, 355
of ocular muscles, 361
muscles, diagnosis of, 363
muscles, etiology of, 367

Paralysis, muscles, pathology of, 367
muscles, prognosis of, 368
muscles, symptoms of, 361
muscles, varieties of, 364
muscles, treatment of, 368
of superior oblique, 365
rectus, 365
orbital, 367
peripheral, 367
third nerve, 59, 355, 366
Pebbles, 350
Perimeter 16, 373
Periorbita, 77
Peritomy, 122
Petit, canal of, 227
Phlyctenulæ, 123
Phlyctenular conjunctivitis, 123, 159
keratitis, 123, 135
ophthalmia, 123
pannus, 125
Phorometer, 380
Photometer, 19
Photophobia, 125
Photophthalmia, 97
Photopsia, 183, 267
Phthiriasis palpebrarum, 41
Phthisis bulbi, 192
Pilocarpine, 209, 405
Pinguecula, 93
Pink eye, 98
Placido's disc, 5, 344
Plate, horn or metal, 48
Plica semilunaris, 92
Potassium permanganate, 401
Presbyopia, 313, 353
Principal points, 308
Prism, 295
apex of, 295
base of, 295
centrads, 296
convergence, 381
degrees, 296
diopters, 296
divergence, 381
exercises, 383
geometrical angle of, 296
rotary, 381
Prisms, numbering of, 296
position of, 296
refracting angle of, 295, 296
refraction by, 296
strength of, 296
uses of, 296, 383
Procaine, 406
Projection, 360
false, 363
Projection, light, 236
Proptosis, 4, 79, 85
Protargol, 402
Protective glasses, 351
measures, 410
Pseudo-glioma, 186, 196, 260
Pseudo-neuritis, 271
Pseudo-pterygium, 131
Pterygium, 130
Ptosis, 58, 63
mechanical, 59
operations for, 59
Pulsation of disc vessels, 35, 202
Puncta, lacrymal, 66, 67, 68
Punctum, eversion of, 68
proximum, 311
remotum, 311
Pupil, 7, 164, 174
Pupil, accommodation and convergence reflex of, 175
Argyll-Robertson, 176, 425, 426
artificial, 174, 215
consensual contraction of, 175
contraction of, 174, 175
dilatation of, 25, 174, 175
dilator of, 164
direct reflex of, 175
exclusion of, 169
hemiopic reflex, 291
indirect reflex of, 175
irregular, 166
occlusion of, 169
reflexes of, 175
seclusion of, 169
sensory reflex of, 175
sphincter of, 164, 174
Pupillary membrane, 165
persistent, 165
reflex paths, 175, 176

Quinine amblyopia, 286

Radium, 64, 85, 122, 129, 410
Ray, axial, 298
incident, 293
reflected, 293
secondary, 299
Rays, absorption of, 293
convergent, 293, 297, 300
divergent, 293, 294, 298
of light, 293
parallel, 293
reflection of, 293
refraction of, 295
Reading-glasses, 353
Recession operation, 388

Reflection, 293
by a concave mirror, 293
convex mirror, 294
plane mirror, 293
laws of, 293
Reflex, corneal, 4
fundus, 24
senile lens, 228
Refracting media of the eye, 308
surfaces of the eye, 308
Refraction, 293, 295
angle of, 295
by prisms, 296
errors of, 326
index of, 295
laws of, 295
of the eye, 308, 309, 315
Refractive apparatus of eye, 308
Resection of muscles, 389, 391
Retina, anæmia of, 262
anatomy of, 250
angeoid streaks of, 261
arteriosclerosis changes of, 264
atrophy of, 253
changes due to excessive light, 261
circulatory disturbances of, 262
connection with cerebrum, 288
contusion of, 261
cyanosis of, 262
detachment of, 267
diseases of, 252
embolism of central artery of, 264
glioma of, 194
hemorrhages in, 263
hyperæmia of, 262
inflammations of, see *Retinitis*
ischæmia of, 262
lymphatics of, 250
œdema of, 255, 261, 262
ophthalmoscopic view of, 35
perivasculitis of, 264
physiology of, 251, 288
pigment degeneration of, 266
preretinal hemorrhage of, 263
rods and cones of, 251
subhyaloid hemorrhage of, 263
symmetrical changes at macula of, 261
thrombosis of central vessels, 265
vascular changes in, 262
vessels of, 34, 250, 270
Retinitis, 252
Retinitis, albuminuric, 256
in pregnancy, 257
circinata, 261
deep, 255
diabetic, 258
electric, 261
etiology of, 254
gravidic, 257
hemorrhagic, 260
leukæmic, 258
metastatic, 260
nephritic, 256
of Bright's disease, 256
parenchymatous, 255
pathology of, 254
pigmentosa, 266
primary, 252
proliferans, 221, 261
punctata albescens, 267
renal, 256
secondary, 252
septic, 260
serous, 255
simple, 255
solar, 261
striata, 261
syphilitic, 259, 267
uncommon forms of, 260
Retinochoroiditis, 182, 253, 259
Retinoscopic mirror, 321
Retinoscopy, 321
Retractors, lid, 7, 238
Retrobulbar abscess, 81
neuritis, 275
Retrotarsal fold, 4, 92
Rodent ulcer of the lids, 64
Rotary prism, 381
Rotation, centre of, 309

Salmon patch, 146
Sarcoma of choroid, 194
Salvarsan, 171, 408
Schlemm's canal, 177, 199
Scissors, enucleation, 87
iris, 210
Stevens, 387
strabismus, 386
Sclera, anatomy of, 158
diseases of, 158
inflammation of, 158
injuries of, 162
rupture of, 162
staphyloma of, 161
trephining of, 216
wounds of, 162
Scleral ring, 33
Sclerectomy, 208, 217, 269

Scleritis, 158, 159, 160
Sclerochoroiditis posterior, 185, 334
Sclerocorneal trephining, 208, 216
Sclerotic, see *Sclera*
Sclerotomy, anterior, 208, 215
posterior, 208, 215, 269
Scopolamine, 403, 404
Scotoma, 17, 84, 183, 205
absolute, 18
annular, 17
central, 17, 185, 276
color, 18, 84, 276
motile, 17
negative, 17
paracentral, 17
peripheral, 17, 183
positive, 17
relative, 18
ring, 17
scintillating, 292
Semilunar fold, 92
Sense, color, 10, 18
form, 10
fusion, 374
light, 10, 19
Septum orbitale, 77
Sera, 408
Shadow test, 321
Shield, Buller's, 105
Shortsightedness, 331
Sideroscope, 224
Siderosis, 224
Sight, 10, 308
old, 313, 353
second, 230
weak, 347
Sign, Dalrymple's, 418
Gifford's, 418
Moebius', 418
Stellwag's, 418
von Graefe's, 418
Signs used in ophthalmology, 306
Silver nitrate, 398, 401
Skiascopy, 321
Skin-grafting, 57, 130
Slit lamp, 37
Smoked glasses, 408
Snow blindness, 97, 261
Sodium chloride, 395
Solutions, cleansing, antiseptic, 394, 414
Spasm of ocular muscles, 368
Spectacles, 349
Spectroscope, 283
Speculum, 237, 386
Sphincter pupillæ, 164
Spring catarrh, 127
Squint, see *Strabismus*
Staphyloma, anterior, 160, 161
corneal, 138, 150
equatorial, 161
posterior, 161, 185, 334
scleral, 161
Stenopæic disc, 215, 341
Stereoscope, 374
Stimulating remedies, 397
Stovaine, 406
Strabismus, 361, 369
accommodative, 372
alternating, 369
concomitant, 369
constant, 369
continuous, 369
convergent, 369, 372
deorsum vergens, 370
development of, 373, 376
diagnosis of, 370
divergent, 369, 376
etiology of, 371
external, 369, 376
hooks, 386
intermittent, 369
internal, 369, 372
latent, 361, 377
measurement of, 370
mixed, 370
monocular, 369
non-accommodative, 372
orthoptic training in, 374
paralytic, 362
periodic, 369
sursum vergens, 369
symptoms of, 371
treatment of, 373, 375, 377
vertical, 369
Stye, 43
internal, 44
Subconjunctival hemorrhage, 94
injections, 407, 410
Subhyaloid hemorrhage, 263
Suprachoroid, 182
Suprarenin, 407
Sutures, Pagenstecher's, 60
Symblepharon, 117, 129, 132
Sympathetic, inflammation, 188, 189
irritation, 189
Sympathetic ophthalmia, 188
ophthalmitis, 188
Synechia, annular, posterior, 168
total posterior, 168
Synechiæ, anterior, 7, 137
posterior, 7, 166, 169
Synchysis, 220, 221

Synchysis, scintillans, 221
Syphilis, inherited, signs of, 148
Syringe, eye, 395

Tangent plane, 363
Tannic acid, 397
Tarsal cyst, 44
  ligaments, 39
  tumor, 44
Tarsitis, 41
Tarsorrhaphy, 57
Tarsus, 39
Tattooing of cornea, 154
Tear sac, 2, 67
Temporal pallor of disc, 276
Tenderness, ciliary, 8
Tendon-tucking operations, 393
Tenonitis, 82
Tenon's capsule, 78, 158, 357
  space, 78
Tenotomy, 384, 385
  complete, 387
  guarded, 384, 387
  limited or partial, 390
  of inf. oblique, 388
  open method, 387
  subconjunctival method, 387
Tension, notation of, 9
  of eyeball, 8
Test, binocular uncovering, 370
  corneal reflex, 371
  excursion, 362
  screen, 370
  screen and parallax, 378
Test types, distant, 10, 315
    for illiterates, 13
    for near vision, 14, 317
    Jaeger's, 14, 317
    Snellen's, 10, 315
Thiosinamin, 398
Thrombosis of cavernous sinus, 82
  of central artery, 265
  of central vein, 265
Tinted lenses, 351
Tobacco amblyopia, 276
Tonometer, 9
Toric lenses, 350
Toxic amblyopia, 276
Trachoma, 113
  acute, 115
  bodies, 118
  cicatricial stage of, 115
  follicular form of, 114
  forceps, 120
  granular form of, 114
  granules, 114
  mild, 116
Trachoma, mixed form of, 114
  operations for, 120
  non-inflammatory, 115
  papillary form of, 114
  simple, 115
  treatment of, 118
Transillumination, 23, 36, 195
Transilluminator, 37
Trephining of sclera, 208 269
  sclero-corneal, 216
Trial case, 304
  frame, 315
Trichiasis, 46, 117
  operations, 48
Tropacocaine, 406
Tropometer, 359
Tuberculin, 409
Tumors, intraocular, 194

Ulcer of the cornea, see *Cornea*
  rodent, of the lids, 64
Undine, 395
Uræmic amblyopia, 258
Uvea, 164
Uveal tract, 164
    diseases of, 188
Uveitis, 178, 188, 189
  anterior, 146, 160
  metastatic, 181, 187
  mild type, 179
  plastic, 179, 189, 190
  purulent, 181, 186, 192
  serous, 179, 190
  severe type, 179
  sympathetic, 181, 188

Vaccines, 181, 408
Vasa vorticosa, 182
Venæ vorticosæ, 182
Vernal catarrh, 128
Vision, acuteness of, 10, 11, 317
  binocular, 359
  binocular single, 359
  blue, 283
  central, 10, 317
  color, 18, 282
  colored, 283
  direct, 10, 317
  distant, 10, 317
  field of, 14, 252
    alterations in, 16
    contraction of, 16
    defects in, 17
    extent of, 16
    limitations of, 16
    pathological alterations of, 16

Vision, field of, tests for, 14
green, 283
indirect, 14
near, 14, 317
peripheral, 10, 14
red, 283
white, 283
yellow, 283
Visual angle, 10
area of cerebral cortex, 288
impressions, 252, 288
line, 309
paths, 175, 289
purple, 251
Vitreous, 220
abscess of, 186, 223
anatomy of, 220
diseases of, 220
fluid, 220, 334
Vitreous, foreign bodies in, 223
hemorrhage into, 222
opacities of, 221, 334
Vossius' ring, 245

Wash, alkaline, 396
Watery eye, 68
Wernicke pupillary reaction, 291
White's ointment, 400
Word-blindness, congenital, 281

Xanthelasma, 63
Xanthoma, 63
Xerosis, 117, 145
X rays, 64, 122, 129, 410

Zinc sulphate, 397
Zoster, 42, 149